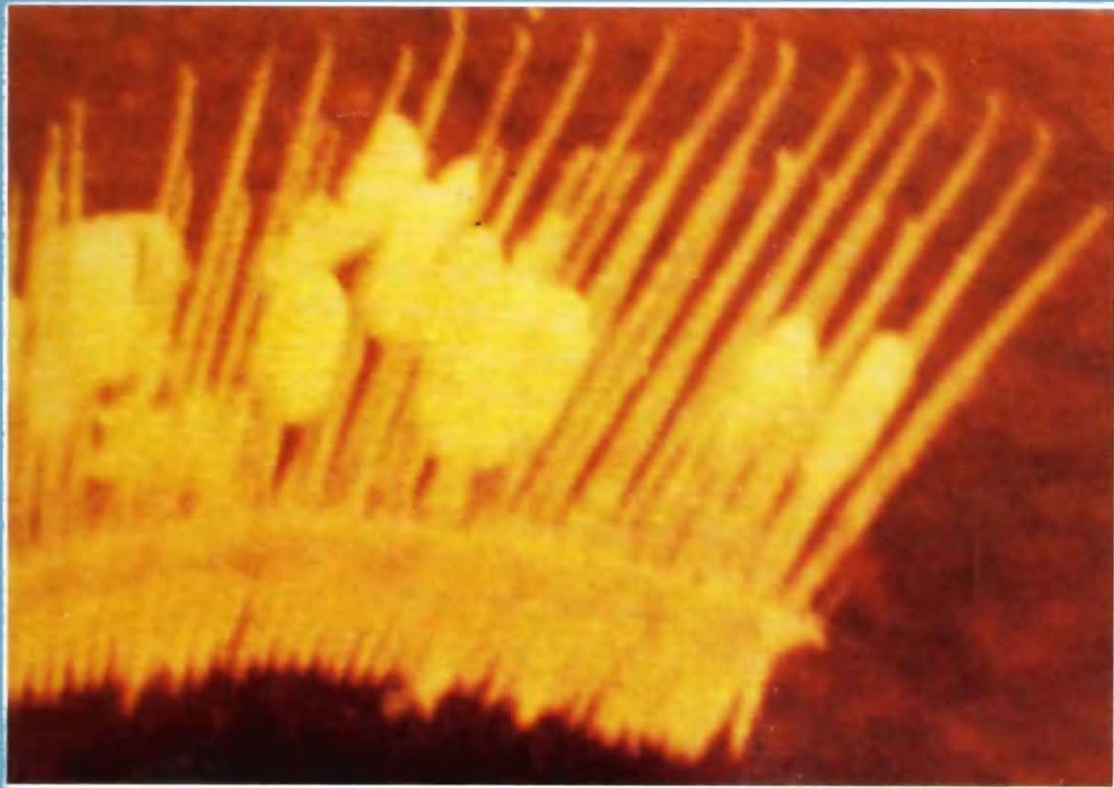


Handbook on
**Myxosporean Parasites of
Indian Fishes**

**C. KALAVATI
N.C. NANDI**



ZOOLOGICAL SURVEY OF INDIA

Handbook on
**Myxosporean Parasites of
Indian Fishes**

**C. KALAVATI
N.C. NANDI***

Department of Zoology, Andhra University, Vishakhapatnam

**Zoological Survey of India, M-Block, New Alipore, Kolkata 700 053*

Edited by the Director, Zoological Survey of India, Kolkata



**Zoological Survey of India
Kolkata**

CITATION

Kalavati, C. and Nandi, N.C. 2007. *Handbook on Myxosporean Parasites of Indian Fishes* : 1-294. (Published by the Director, *Zool. Surv. India*, Kolkata)

Published : September, 2007

ISBN 978-81-8171-168-7

© Govt. of India, 2007

ALL RIGHTS RESERVED

- No part of this publication may be reproduced stored in a retrieval system or transmitted in any form or by any means, electronic, mechanical, photocopying, recording or otherwise without the prior permission of the publisher.
- This book is sold subject to the condition that it shall not, by way of trade, be lent, resold, hired out or otherwise disposed of without the publisher's consent, in an form of binding or cover other than that in which, it is published.
- The correct price of this publication is the price printed on this page. Any revised price indicated by a rubber stamp or by a sticker or by any other means is incorrect and should be unacceptable.

PRICE

Indian Rs. 800.00
Foreign : \$ 60; £ 50

Published at the Publication Division by the Director Zoological Survey of India, 234/4, AJC Bose Road, 2nd MSO Building, 13th floor, Nizam Palace, Kolkata 700020 and printed at M/s Power Printers, New Delhi 110 002.

PREFACE

This handbook is a continuing collaborative effort of documenting catalogue and State Fauna Series to provide a true identification manual related to myxosporean parasites of fishes that is up-to-date, dependable, exciting and challenging. Its major goal is to emphasize the central role of detection and determination of piscine myxosporean parasite occurring in India that occupied a paramount position in aquaculture and fisheries. With the growing need from traditional to intensive and semiintensive piscicultural practices, the very survival of commercially important cultivated fishes is at stake, because of easy spread of epizootic diseases in organically rich crowded freshwater pond ecosystem. It is, thus, imperative that fish farmers, fishery entrepreneurs and researchers of fisheries and pathobiology be informed and acquainted about diagnosis of the diseases, identification of the species as well as parasitological and pathological issues. Thus, we aim to write this handbook not only for students and researchers but also for fishery owners with only a minimal background in biology to aware and facilitate recognition of myxosporeans and their pathogenic effects, if already known.

We believe that this document presents the basic diagnostic characters as well as key to the species in clear systematic sequence, but we realize that many serious researchers will prefer further details of the life cycle stages of the species, which will be taken up under 'Fauna of India' Series. As usual this account begins with a brief introduction that attempts to convey some of the information and excitement that has resulted from recent development in the field of parasitology/protozoology particularly the myxozoa. It includes earlier works on this subject, collection, preservation and identification of species, general organization and biology that includes spore morphology, ultrastructure and life cycle with convincing evidence of transmission through tubificid worms. An abbreviated current classification of myxosporean parasites is also added in the introductory part. This is followed by systematic account, which is amply illustrated with 276 figures and contains 'easy to use' key to the species, diagnosis, distribution, hosts, site of infection, pathogenicity and remarks. At the end, pathobiological and histo-parasitological effects of myxosporean parasites are suitably summarized with respect to different infected organs with illustrations in five plates so as to aware about the impact of these parasites on the organs and tissues, in addition to their treatment and control, and their use as biological tags.

We are grateful to the Head, Department of Zoology, Andhra University, Visakhapatnam, Andhra Pradesh and Director, Zoological Survey of India, Kolkata for facilities provided for this work. The various help, cooperation and encouragement received from our colleagues,

teachers, friends and experts in India and abroad are thankfully acknowledged. Many of them have readily supplied reprints of their valuable papers. We are indebted to Prof. E. R. Noble of University of California. Santa Barbara, Dr. G. L. Hoffman of U. S. Department of Interior Fish and Wildlife Service; Prof. Jiri Lom, Czechoslovak Academy of Sciences, Czechoslovakia; Dr. P. Janardanan of Calicut University. Kerala; Dr. Nilima Gupta of Rohilkhand University, Uttar Pradesh; Dr. D. P. Haldar of Kalyani University, West Bengal, Dr. N. K. Sarkar of Rishi Bankim Chandra College, West Bengal, Dr. S. K. Nandi of West Bengal University of Animal and Fishery Sciences, Kolkata; for supplying reprints/ xerox copies of several papers required for the preparation of this document. One of us (CK) is grateful to Professor B. V. Sandeep, Department of Zoology and Dr. K. Padma Dorothy. Department of Biotechnology, Andhra University for their timely help. The valuable counsel and encouragement from Professor A. V. Raman, Division of Marine Biology, Department of Zoology. Andhra University and, Professor Amalesh Choudhury, Dr. A. K. Mandal and Dr. A. K. Das from time to time has made this endeavor possible.

C. Kalavati
N. C. Nandi

Contents

| | |
|--|------------|
| <i>Preface</i> | <i>iii</i> |
| Introduction | 1 |
| Earlier works | 2 |
| Collection and Preservation | 3 |
| General Organisation and Biology | 5 |
| Classification | 12 |
| Classified list of species | 14 |
| Systematic account | 27 |
| Disease and Pathology | 255 |
| Diagnosis, control and treatment | 263 |
| References | 267 |

1. INTRODUCTION

Myxosporeans are exclusively parasites of lower vertebrates, typically of fishes, occasionally in amphibians and reptiles and rarely in invertebrates. They occur mainly in bony fish and can also be found in cartilaginous fishes. These parasites are the causative agents of a serious disease in freshwater, estuarine and marine fishes known as myxosporidiosis (the name of the disease is derived from the well known earlier Order Myxosporidia or Myxosporida). Several species are known to cause serious losses in pisciculture. Infections with the disease myxosporidiosis or myxosporidiosis typically appear as macroscopic white or yellowish cysts on body surface, gills and musculature. Serious epizootics are caused by histozoic genera *Myxobolus* and *Henneguya* in cultivable freshwater fishes and also by the genera *Kudoa* and *Hexacapsula* in commercially harvested marine fishes. The epizootics of severe whirling disease especially in trout hatcheries caused by a myxosporean parasite *Myxosoma* (now *Myxobolus*) *cerebralis* is widespread throughout Western Europe, the United Kingdom, South Africa, New Zealand as well as in India. In trout and salmon hatcheries of northwestern United States *Ceratomyxa shasta* produces massive epizootics. The disease or myxosporidiosis is particularly prevalent in warm-water pisciculture ponds in India, entire Asia Far East region with the adoption of aquaculture and fish husbandry in freshwater ponds and tanks on a large scale. The disease sometimes assumes epidemic proportions because of increased organic inputs in the form of fish food and manure, in stagnant or lentic water conditions and crowding of fishes in ponds, causing easy spread of pathogenic species.

Many species of Myxosporidia belonging to the genera viz., *Leptotheca*, *Chloromyxum*, *Myxobolus*, *Henneguya*, *Unicauda*, *Thelohanellus*, *Myxidium*, *Zschokkella*, *Sphaerospora*, etc., have been found to infect lacustrine, riverine as well as cultivated fishes in India and abroad (Fujita, 1912, 1929; Ishii, 1915a,b; Kudo, 1920; Nakai, 1926; Sikama, 1938; Chakravarty, 1939, 1943; Sarkar, 1946; Tripathi, 1952; Hoshina, 1953; Hoshina and Hosoda, 1957; Markovitch, 1963; Schulman, 1966; Sanders *et al.*, 1970; Hoffmam and Meyer, 1974; Markiw and Wolf, 1974, Mitchell, 1978; Kent and Hedrick, 1985-1987; Maheshwari, 1987; Moser and Kent, 1993; Ram *et al.*, 1994; Das and Das, 1995). They are found in all tissues and organs of fish. The class Myxosporidia contains around 1200 species in about 46 genera worldwide (Lom, 1987). In India, in all 282 species have been recorded. Fish farmers and entrepreneurs are increasingly aware of protozoan, helminth and crustacean parasites and diseases of fishes. Tremendous efforts, mandays and money are spent to detect, diagnose and control such diseases. Largely for these reasons an attempt is herein made to present an illustrated handbook on Indian myxosporean parasites for identification purpose as well as to highlight the current state of art on this subject.

2. EARLIER WORKS

Although Basanquet (1910) was the first to report a new species of Myxosporea, *Myxidium mackiei* in kidney of the tortoise, *Trionyx gangeticus*, Southwell (1915) made the first report of myxosporean, *Myxobolus* sp., in the subcutaneous tissue of the fish, *Rasbora daniconius*. Later on, Southell and Prasad (1918) reported *Myxobolus nodularis* in muscle of the same piscine species along with other myxozoan parasites from various fish hosts. Ray (1933a, b) made preliminary observations on Myxosporidia from India. Chakravarty (1938, 1939, 1943) studied the myxosporidian parasites from common food fishes of Bengal, while Ganapati (1941) and Setna (1942) reported on the myxosporean parasites of marine fishes from Madras (now Chennai) and Bombay (now Mumbai) respectively. During post independence period there has been tremendous surge of myxozoan parasite research of freshwater fishes in India. Several workers like Tripathi (1952), Qadri (1962-1970), Lalitha Kumari (1965-1969), Bhatt and Siddiqui (1964), Ray Chaudhuri and Chakravarty (1970), Karamchandani (1970), Mandal and Nair (1975), Haldar and his co-workers (1978 onwards), Seenappa and Monohar (1980), Hagaragi and Amoji (1981), Jayasri (1982), Bajpai *et al.* (1981), Bajpai and Haldar (1982), Yatindra and Mathur (1988), Kundu (1985), Gupta and Khera (1987-1992), and Susha and Janardanan (1994, 1995) contributed to our knowledge of myxosporean parasites of Indian fishes from freshwater habitats. Myxozoan parasites from estuarine and marine teleost fishes have been reported by Tripathi (1952), Narasimhamurti (1970), Nandi and Choudhury (1973) and, Narasimhamurti and Kalavati (1979a, b, c). At present, Sarkar (1984-onwards), Rajendran and Janardanan (1992) and Padma Dorothy and Kalavati and their colleagues (1992-1998) are carrying out works on marine myxozoa. Das *et al.* (1993) and Nandi *et al.* (2004) studied and collated the parasitic protozoa including myxosporeans occurring in West Bengal and Andhra Pradesh respectively, while Nandi *et al.* (1983, 2002) prepared the host parasite catalogues as well as bibliography of protozoan parasites covering myxosporean parasites of Indian fishes. Acute endoparasitism causing myxoboliasis in the brain of a freshwater fish *Labeo bata* was reported by Das *et al.* (1988). Fish disease in India and fish health monitoring, treatment and control of myxosporean parasites have been dealt by Das and his co-workers (1985-1995).

3. COLLECTION AND PRESERVATION

The step towards collection and preservation of Myxozoa requires professional experience of a fish pathologist to correctly diagnose and making a clinical history of the host fish. Techniques of autopsy and/or dissection of suspected fish host is essential before actual examination of organ imprints and tissue sections. The preparation of organ imprints and histological and histochemical techniques of detection of myxosporean parasites are as follows :

Preparation of organ imprints

The identification of myxosporean infection can only be made by examination of cysts and microscopic observation of spores and/or vegetative stages. As such, after dissection when cysts are seen or abnormalities in the organs are noticed or even when bile shows abnormal colouration (cloudy, light yellow or orange) myxozoan infection may be suspected. For precise confirmation of infection fresh saline wet mounts are prepared macerating the cysts or affected tissue. Myxozoan spores are easily identified from such wet preparation under microscope. But random examination of organs is also essential for proper detection of diffuse infiltration of spores or vegetative stages in case of latent infection without clinical manifestations. For spore morphology smears of spore suspensions in 0.5% saline obtained from cysts or infected organs are air dried, fixed in absolute methanol and stained with Giemsa. Initial hydrolysis of smears in 1N HCl yields better results. Several rapid staining techniques are used to detect some structural characteristics of spores. Mucous envelopes around the spores are determined using a drop of spore suspension mixed with a drop of common black India drawing ink. Lugol's iodine is often used to stain the iodophilous vacuoles of the species belonging to the family Myxobolidae. Methylene blue or methyl green is employed to detect spores in organ smears. Potassium hydroxide (KOH) or saturated solution of urea or 30% H_2O_2 is used for extrusion of polar filaments. The simple and effective technique prescribed by Lom (1969a) is suggested for diagnostic photomicrography of these parasites as follows :

- Only fresh, unfixed spores should be used.
- Microscope slides covered with a thin (1.5 mm) even layer of 1.5% agar.
- A small drop of spore suspension should be spread on a cover slip.
- Spores of coelozoic species may be concentrated by low-speed centrifugation of fluid and scrapings from the suspected organ.
- The cover slip is placed face down onto agar-covered slide for making an even layer of spores for photography of the spores in different views.

- The cover-slip preparations may be trimmed and sealed with paraffin or clear lacquer for preservation and further observation for several weeks keeping them in a refrigerator.
- Camera lucida drawings or freehand composite drawings should be prepared to supplement the photomicrographs.

However, samples of infected tissue should also be preserved in 10% buffered Formalin or Bouin's fixative for histological preparation.

Histological preparation

Histological preparation of organs and tissues containing cysts can be made by fixing with fixatives, embedding in paraffin, cutting microtome sections, and staining and mounting these sections following the standard histological techniques (Pearse, 1960).

4. GENERAL ORGANIZATION AND BIOLOGY

Myxosporeans are to some extent multicellular in morphological organization, being composed of specialised cells *viz.*, capsulogenic cells, valvogenic cells and sporoplasmic cells. These specialised cells carry out specific functions of the parasite, and are considered as cnidarians or degenerated multicellular organisms. The trophozoite stages seldom provide unique features for taxonomic identity. Hence, guidelines for identification, general terminology as well as spore morphology are furnished hereunder.

Guidelines for identification

The guidelines for identifying and describing myxosporean species summarized by Lom and Arthur (1989) are as follows:

Sample collection : Samples should always be fresh and they may be fixed in buffered 10% formalin but not in alcohol or frozen in case of emergency for subsequent examination soon after they thaw.

Description of host : Scientific name of the host, its age and geographic location, prevalence of infection, site of infection such as tissue or organ infected, and pathological changes are recorded.

Description of the vegetative stage of parasite : Shape, size, structure, and number of spores present, if any, should be recorded.

Description of the spore : The variability in shape and size of the spore is recorded. The shape, size, and presence of sutural ridges are noted along with the presence or absence of spore projections, caudal appendages, ribs, ridges and striae. The number, shape, size, and angle of polar capsules are recorded, noting whether the polar capsules are of equal size, and also their relation to spore length. The number and arrangement of coils in the polar filaments and position of capsule opening are observed. The presence or absence of a membranaceous or mucous envelope around spore is also recorded along with the presence or absence as well as shape of iodophilous vacuoles, if present. The position and number (one or two) of sporoplasms in spore cavity are noted. Besides these, high-quality line drawings and, when possible, microphotographs are prepared.

Terminology

Terms used to describe myxosporean taxonomy

- Cyst : A trophozoite with an impervious membrane surrounding an organism.

- Cnidocyst (polar capsules) : A sac-like structure containing polar filament in the spore.
- Polar filament : A thread-like structure present coiled inside the polar capsule.
- Spore: A growing sporogonic cell that acquires a resistant outer coating.
- Trophozoite : A growing vegetative stage. (This includes all stages except the spores).

Terms used to describe myxosporean development

- Endogeny : Internal budding.
- Enveloping cell (=Pericyte) : Cell enveloping the sporogonic cells.
- Generative cells : Cells within polysporoblastic plasmodia that form the sporoblast.
- Mother cell : same as enveloping cell.
- Pansporoblast : An enveloping cell that contains two or more sporoblasts. Pansporoblasts develop within plasmodia.
- Plasmodia : Multinucleate cells containing free vegetative nuclei and generative cells produced by endogenous budding.
- Plasmotomy : Vegetative reproduction by external budding.
- Pseudoplasmodium : A cytoplasmic structure found in coelozooic genera such as *Sphaerospora* that do not produce true plasmodia. The pseudoplasmodium is homologous to the pericyte (enveloping cell) found in species that produce large, polysporous plasmodia. As a result, the cells that are formed within the pseudoplasmodium are the sporogonic cells (Dykova and Lom, 1982; Lom *et al.*, 1982).
- Sporoblast (sporont) : The cells which ultimately form the spore (sporogonic cells). (Some authors do not consider the enveloping cell to be part of the sporoblast).

Terms used to describe sporogenesis (spore formation)

- Sporogonic cells : Cells that form spores.
- Capsulogenic cells : Cells that form the polar capsules.
- Valvogenic cells : Cells that form the spore valves.
- Sporoplasmic cells : Cells that form the sporoplasm.
- Sporoplasm : The cell that is released from the spore that becomes the amoebula.
- Vegetative nuclei : Free nuclei in plasmodia.

Spore morphology

Despite considerable variation in spore morphologies even within the same species, spore structure provides the most reliable, very much constant and taxonomically useful criterion for identification of species, and perhaps for this reason a large number of myxozoan species are described based on spore morphology. The spore structure, however, varies widely from genera to genera, in shape, size and measurements of spore and polar capsule, and in number, location and disposition of polar capsule within the spore as well as in other structural details. The shape of the spore and the number and position of cnidocysts are used to distinguish genera. In structure, a spore is a multicellular unit, typically 10-15 μm in longest dimension, and formed externally of one to six valves. Valves are joined in variously, sinuous or straight often thickened suture. The general morphology of a typical spore of *Myxobolus* is illustrated hereunder.

In the genus *Myxobolus* the spores are typically spheroid or pyriform and uniformly thick. The suture bisects the longest axis in side view and is the thickest region of valves. Valvular thickenings, indentations, and projections present on the inner and outer surface of the edges of the valves vary from species to species. The length and breadth of fresh, unfixed spore and of the cnidocysts are measured in front view for taxonomic purposes, while thickness is determined in side or end view. The pole to which the cnidocysts are arranged is considered the anterior surface. The cnidocysts of spores are usually spherical or pyriform. Each cnidocyst contains a coiled thread or filament inside. The number of coils, angle of coiling of the intact filaments within the capsules and the length of the extruded filaments are often used in the descriptions of species (Fig. 1a).

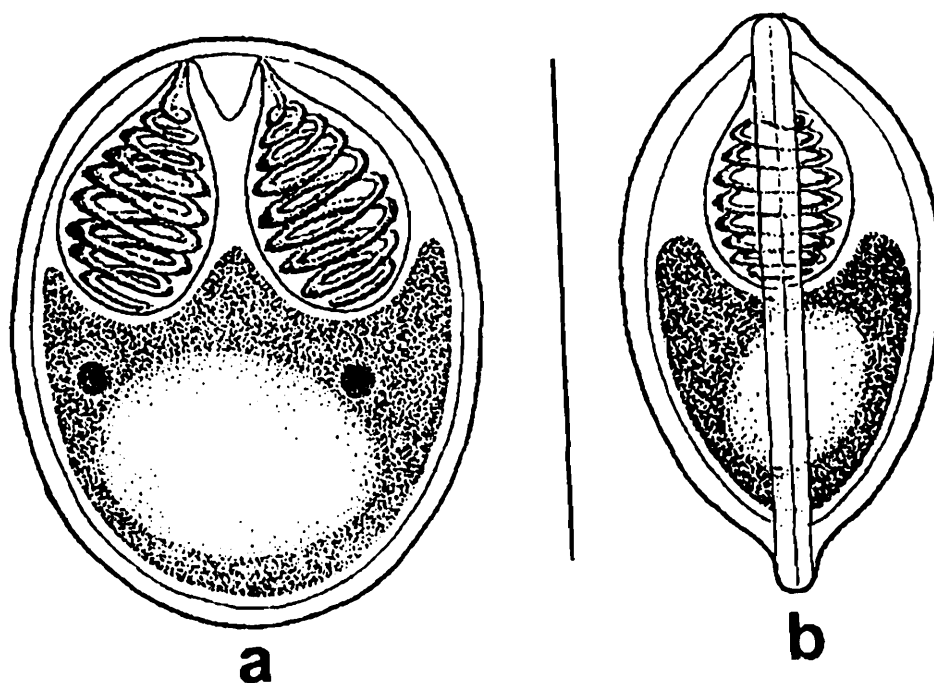


Fig. 1a. : Typical myxozoan spore (Genus *Myxobolus*) : a. Valvular view b. Sutural view

Ultrastructure

The ultrastructure of trophozoites and spores of a few species has so far been studied with the electron microscope. Such electron microscopic studies indicate multicellular nature of trophozoites as well as differentiation into distinct somatic and generative components in the early developing phase. The multicellular somatic plasmodium displays the generative units as discrete cells. Pinocytotic vesicles are more commonly encountered in the histozoic forms than the coelozoic species. Lom and Hoffman (1971) made scanning electron micrographic study of the spore of *Myxobolus* (*Myxosoma*) *cerebralis*. The spore valves appear somewhat shrunken at the regions that are not supported internally by cnidocysts. The two valves are of different volume and a deep furrow in each valve parallels the suture. Fine mucous strands extend over the surface, concentrating towards the posterior. The furrow and mucous strands are unique to *M. cerebralis*. The canals through which polar filaments are extruded are of open type in this species (Fig. 1b).

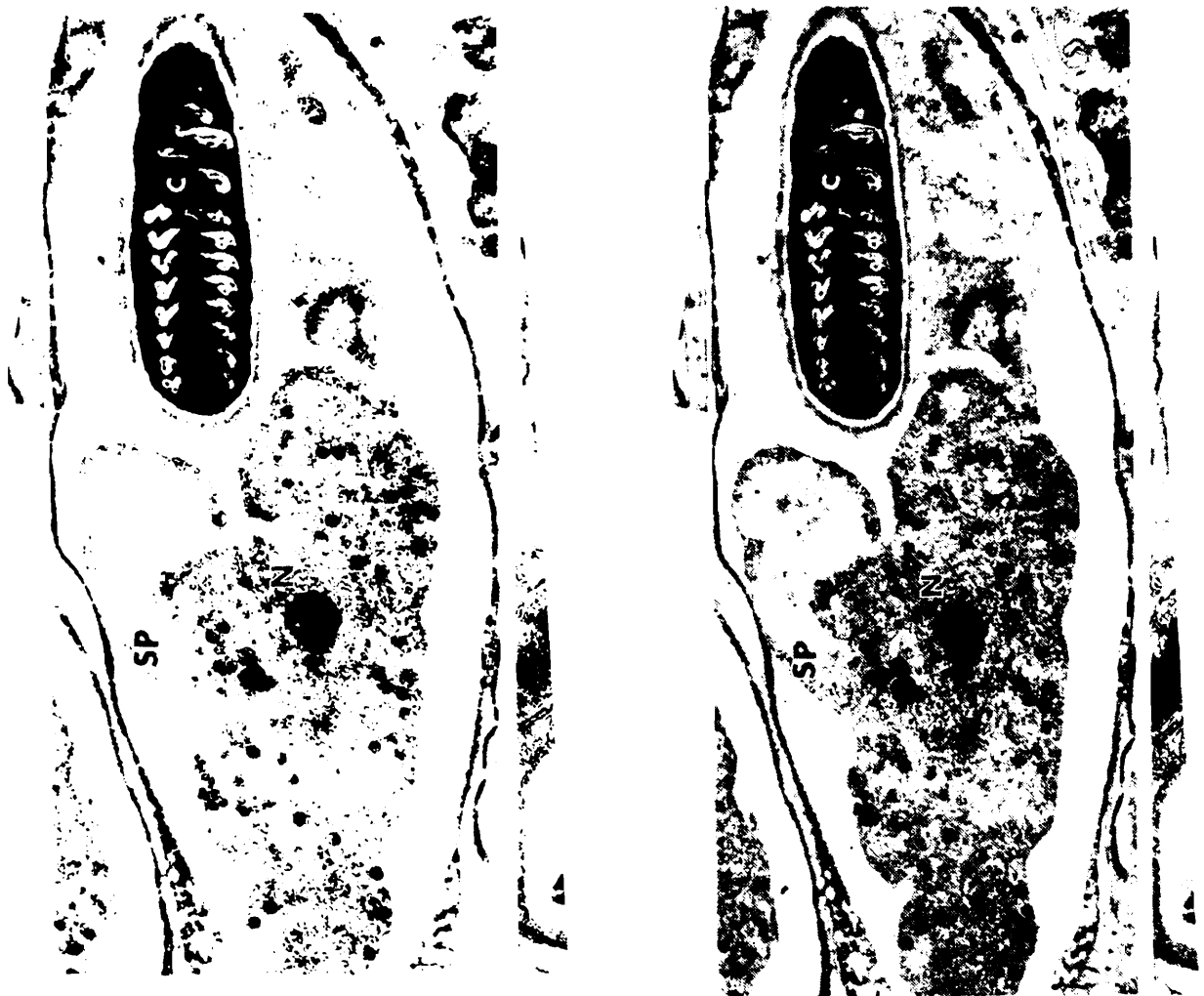


Fig. 1b. : Typical myxozoan spore (Genus: *Henneguya*) : EM structure.
(Lom and de Puytorac, 1965. *Protistologica* 1(1) : 53-65)

Life cycle (Fig. 2)

Myxosporeans have a complex 2-host life cycle involving a fish and an annelid/ or bryozoan. The life cycle begins in fish when water borne actinosporean spores released by oligochaetes/ polychaetes/ bryozoans contact a susceptible fish host. The spore then releases the polar filament which anchors the spore to the epithelium of the buccal cavity or gills as the case may be and releases the sporoplasm that penetrates the host cell. The two haploid nuclei in the sporoplasm fuse by autogamy to form a diploid nucleus. The trophozoites now migrate to infection site by unknown route to continue development in the host organ. In the host organ the trophozoite becomes a multinucleated plasmodium containing free vegetative nuclei. These nuclei develop to form generative cells, which undergo endogenous budding. In some histozoic myxosporean species a huge plasmodium develops containing an enormous number of generative cells that give rise to spores.

The sporogenesis is initiated by the fusion of two generative cells. During fusion, one cell envelops the other to form sporoblast. The outer cell is called as pericyte, enveloping cell or mother cell. The inner cell is known as sporogonic cell, which divides to form multicellular spore. The development of spore, however, varies but, in general, the spore is formed by differentiation of the generative cells into valvogenic, capsulogenic and sporoplasmic cells. The developing spore or sporoblast of *Myxobolus* has six nuclei surrounded by discrete cellular masses of cytoplasm. Of these, two cellular units (valvogenic cells) develop into the pair of valves; two others (capsulogenic cells) transform into two internal cnidocysts, usually called polar capsules, and the remaining pair forms the germinative sporoplasm. In mature spore the nuclei of the valves and cnidocysts are usually not visible. During hatching of the spore the polar filament is everted through a pore in the shell valve. The filaments serve as an adhesive holdfast or entangling device, which promotes infection of the host. Spores of *M. cerebralis* become infective after aging or maturation outside the host. Precise limnological conditions essential for maturation of the spore have not been clearly defined. All attempts to determine the complete myxosporean life cycle were unsuccessful for about 100 years.

Schafer (1968) considers that some stage other than the spore may be infective. Sindermann (1970) suggested that certain zooplankton might act as intermediate hosts of myxosporean species that infect marine pelagic fishes. Infection in fish has not been produced through ingestion of fresh spores. A few reports claimed transmission of *Myxobolus* by aged spores (Hoffmann and Putz, 1971; Yunchis, 1974; Upenaskaya, 1978; Dana, 1982) but these reports have not been confirmed (Wyatt, 1978; Wolf and Markiw, 1984). Kent and Hedrick (1985) transmitted the causative agent of proliferative kidney disease (PKD) with the blood and spleen of infected salmonid fish. Kent and Hedrick (1986) produced PKD in rainbow trout by introducing them in hatchery waters containing the infective stage. Wolf and Markiw (1984) have provided convincing evidence that the completion of life cycle of *M. cerebralis* requires ingestion

of an infected tubificid oligochaete. Their discoveries from feeding of spores to these worms have revealed that after 3 to 4 months the spores developed into organisms resembling a *Triactinomyxon* of the class Actinosporea. Serological tests confirmed the relatedness of *M. cerebralis* and the actinosporean *Triactinomyxon*. Markiw (1989) was the first to report that the skin was the site of first infection by a stage resembling a triactinomyxon sporoplasm. Rudisch *et al.* (1991) demonstrated *Myxobolus pavlovskii* infections in silver carp by exposing the fish to *Hexactinomyxon* sp. from a mixed population of oligochaete. Yokoyama *et al.* (1993) induced *Myxobolus* sp. infections in goldfish with actinosporean *Raabeia* spores collected from oligochaete worms. During

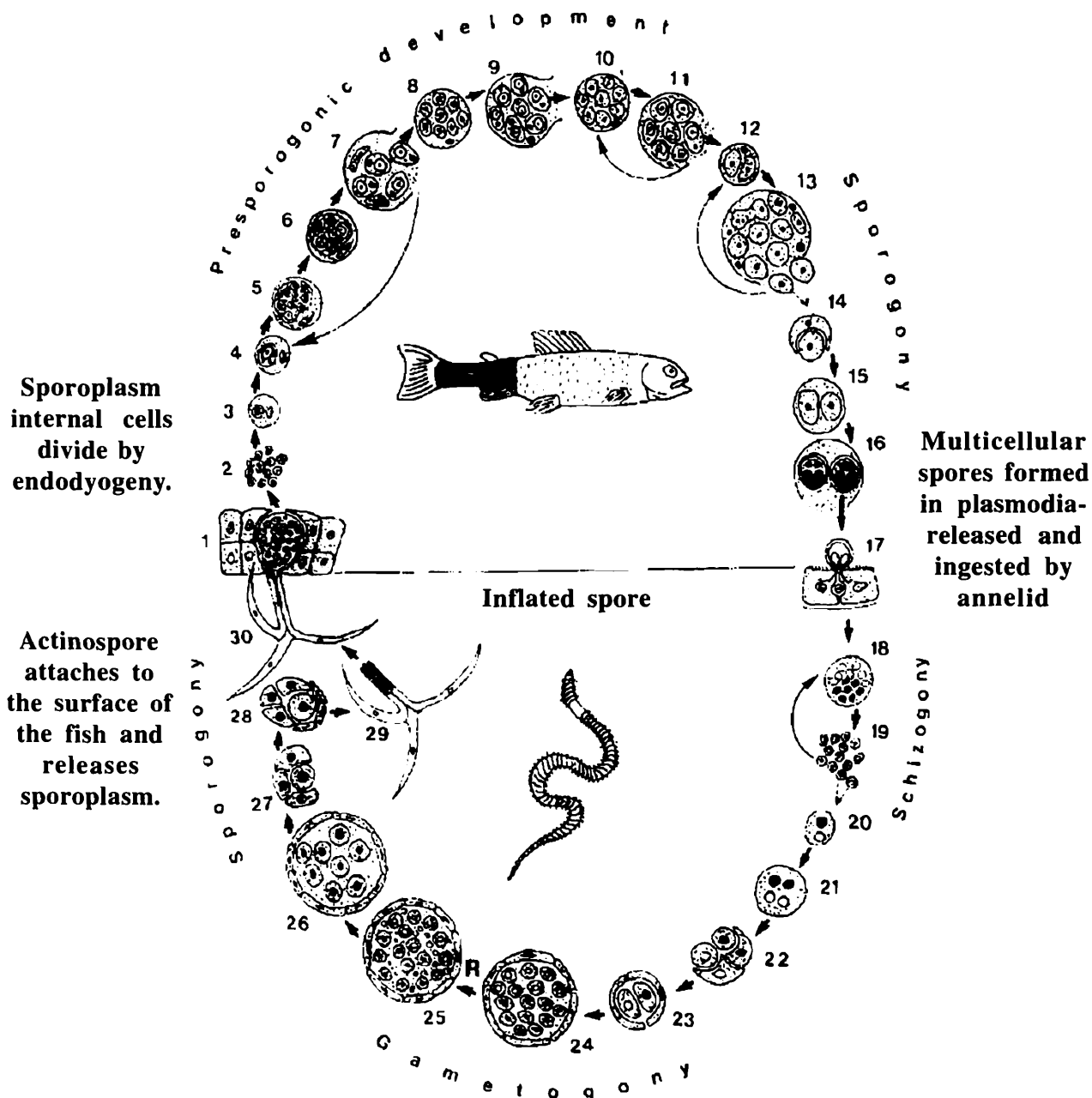


Fig. 2. Life cycle and Development of the Myxozoa (from Kent *et al.*, 2001. *J Eukaryot. Microbiol.*, 48(4), pp. 395-413). 1-16. Myxozoan development in fish host. 17-30. Actinosporean development in annelid host.

the development in the invertebrate host, the myxospores from the fish host release the polar filament in the gut, anchor the spore and release the sporoplasm. The two nuclei of the sporoplasm divide independently to produce multinucleate plasmodia, which eventually undergo plasmotomy resulting in small uninucleate bodies. They either repeat the schizogony or fuse to form binucleate cells. These cells undergo meiosis and form two tetranucleate forms with one generative and the other enveloping cells. These pansporocysts undergo sporogony resulting in the formation of an actinospore with hooks. At least 8-16 cells undergo to the formation of a typical actinospore. Such a life cycle, with two different sexual stages, resulting in two kinds of resistant spores *viz.*, myxospore and actinospore, is unique amongst the parasitic organisms.

5. CLASSIFICATION

The classification of protistan phyla including the phylum Myxozoa has been in a state of transition. It still remains a troublesome issue in taxonomy and systematics of protozoans as a whole (Schulman, 1966; Kudo, 1966; Mitchell, 1977; Lom and Noble, 1984; Corliss, 1984; Lom and Arthur, 1989; Cavelier-Smith, 1993, 1998; Cox, 1994; Hausmann and Haulsmann, 1996). The scheme of classification has been made and updated by the Society of Protozoologists from time to time (Honigberg *et al.*, 1964; Levine *et al.*, 1980; Lee *et al.*, 1985, 2002).

Although the myxozoans have herein been classified under the kingdom Protista, the phylum Myxozoa has been relegated to cnidarian lineages (Lom and de Puytorac, 1965; Lom, 1969, 1973; Grell, 1973; Kent *et al.*, 1994). The members of the class Myxosporea bears striking resemblance with cnidarians with respect to spores of multicellular origin characterized by one or two sporoplasms and one to six cnidocysts and a variety of specialised cells and nuclei. They are unique parasites not closely related to any protozoan group. Siddal *et al.* (1995) reviewed both morphological and molecular phylogenetic evidences and stated that the phylum Myxozoa must be abandoned for their origins in a clade of parasitic cnidarians. Despite the similarities the relationship of the Myxozoa with the Cnidaria though well established is not incorporated in textbooks. For the benefit of readers an abbreviated current classification of Myxozoa proposed by Kent *et al.* (2001), though not adopted in this document, is given below :

Phylum MYXOZOA

Class MYXOSPOREA

Order BIVALVULIDA : Spore with 2 valves

Suborder VARIISPORINA

Genera : *Auerbachia*, *Bipteria*, *Ceratomyxa*, *Chloromyxum*, *Davisia*, *Hoferellus*, *Leptotheca*, *Myxidium*, *Myxobilatus*, *Neoparvicapsula*, *Ortholinea*, *Parvicapsula*, *Polysporoplasma*, *Sinuolinea*, *Spaerospora*, *Zschokkella*

Suborder PLATYSPORINA

Genera : *Henneguya*, *Myxobolus*, *Neohenneguya*, *Phlogospora*, *Thelohanellus*, *Unicauda*.

Suborder SPHAEROMYXINA

Genus *Sphaeromyxa*

Order MULTIVALVULIDA : Spore with more than 2 valves

Genera : *Hexacapsula, Kudoa, Trilospora, Unicapsula*

Class MALACOSPOREA

Order MALACOVALVULIDA : Spore with soft valves

Genus : *Tetracapsula*

The prime purpose of this document is that it should serve as identification manual of myxozoans for parasitological and pathobiological studies. However, in the handbook, the classification of Lom and Noble (1984) is followed considering members of myxozoans belonging to the kingdom Protista and accordingly an outline representation of the myxozoan genera and species occurring in India is given under Classified List of Species.

6. CLASSIFIED LIST OF SPECIES

Classification according to Lom and Noble, 1984; revised Lom and Dykova, 1992.

Phylum MYXOZOA Grasse, 1960

Class Myxosporea Butschli, 1881

Order Bivalvulida Schulman, 1959.

Suborder SPHAEROMYXINA Lom and Noble, 1984

Family SPHAEROMYXIDAE Lom and Noble, 1984

Genus *Sphaeromyxa* Thelohan, 1892

1. *Sphaeromyxa chacundae* Sarkar, 2004
2. *Sphaeromyxa diacanthusa* Sarkar, 2004
3. *Sphaeromyxa dighae* Sarkar and Mazumder, 1983
4. *Sphaeromyxa ganapatii* Kalavati and Vaidehi, 1991
5. *Sphaeromyxa hareni* Sarkar, 1984
6. *Sphaeromyxa opisthopterae* Sarkar, 1999
7. *Sphaeromyxa pultai* Tripathi, 1952
8. *Sphaeromyxa theraponi* Tripathi, 1952

Suborder VARIISPORINA Lom and Noble, 1984

Family MYXIDIIDAE Thelohan, 1892

Genus *Myxidium* Bütschli 1882 (= *Cystodiscus*, Lutz, 1889)

9. *Myxidium aori* Lalitha Kumari, 1969
10. *Myxidium apocryptae* Bajpai and Haldar, 1982
11. *Myxidium attuum* Sarkar, 2004
12. *Myxidium batae* Sarkar and Ghosh, 1991
13. *Myxidium boddaerti* Choudhury and Nandi, 1973
14. *Myxidium calcariferi* Chakravarty, 1943
15. *Myxidium fasciatum* Sarkar, 1985
16. *Myxidium glossogobii* Chakravarty, 1939

17. *Myxidium heteropneustesi* Chakravarty, 1943
18. *Myxidium islampurium* Sarkar, Mazumdar and Pramanik, 1985
19. *Myxidium labeonis* Gupta and Khera, 1986
20. *Myxidium leiberkuhni* Butschli, 1881
21. *Myxidium leptocephalichthysum* Sarkar and Roy Choudhury, 1997
22. *Myxidium menodae* Sarkar, 2004
23. *Myxidium molnari* Yatindra and Mathur, 1988
24. *Myxidium mystusium* Sarkar and Ray Choudhury, 1986
25. *Myxidium notopterum* Sarkar, 1996
26. *Myxidium papernae* Padma Dorothy and Kalavati, 1992
27. *Myxidium sciaenae* Sarkar, 1986
28. *Myxidium striatusi* Sarkar, 1982

Genus *Zschokkella* Auerbach, 1910

29. *Zschokkella cascasiensis* Sarkar, 1995.
30. *Zschokkella channae* Sarkar, 2004
31. *Zschokkella cirrhinae* Sarkar, 2004
32. *Zschokkella fossilae* Chakravarty, 1943
33. *Zschokkella ganapatii* Padma Dorothy and Kalavati, 1992 a
34. *Zschokkella glossogobii* Kalavati and Vaidehi, 1991
35. *Zschokkella gobiensis* Sarkar and Ghosh, 1991
36. *Zschokkella illishae* Chakravarty, 1943
37. *Zschokkella labeonis* Lalitha Kumari, 1969
38. *Zschokkella ophicephali* Lalitha Kumari, 1969
39. *Zschokkella platystomusi* Sarkar, 1986
40. *Zschokkella pseudosciaena* Sarkar, 1996

Genus *Coccomyxa* Leger and Hesse, 1907

41. *Coccomyxa baleswarensis* Sarkar, 1995

Family ORTHOLINEIDAE Lom and Noble, 1984

Genus *Ortholinea* Schulman, 1962

42. *Ortholinea gadusiae* Sarkar, 1999

43. *Ortholinea indica* Sarkar, 1999
44. *Ortholinea visakhapatnamensis* Padma Dorothy and Kalavati, 1993b
 Family SINUOLINEDAE Schulman, 1959
 Genus *Sinuolinea* Davis, 1917
45. *Sinuolinea andamani* Kalavati, Padma Dorothy and Paul Pandian, 2002
46. *Sinuolinea indica* Sarkar, 1997
 Genus *Davisia* Laird, 1953
47. *Davisia cynoglossi* Narasimhamurti, Kalavati, Anuradha and Padma Dorothy, 1990
48. *Davisia filiformis* Padma Dorothy, Kalavati and Vaidehi, 1998
49. *Davisia murtii* Padma Dorothy and Kalavati, 1994
50. *Davisia sauridae* Narasimhamurti, Kalavati, Anuradha and Padma Dorothy, 1990
 Genus *Myxoproteus* Doflein, 1898
51. *Myxoproteus cujaeus* Sarkar, 1996
 Genus *Paramyxoproteus* Wierzbicka, 1986
52. *Paramyxoproteus chlorophthalmusi* Kalavati, Padma Dorothy and Paul Pandian, 2002
 Genus *Bipteria* Koveleva, Zubchenco and Krasin, 1983
53. *Bipteria indica* Kalavati and Anuradha, 1995
 Genus *Neobipteria* Koveleva, Zubchenco and Krasin, 1983
54. *Neobipteria coramandelensis* Narasimhamurti, Kalavati, Anuradha and Padma Dorothy, 1990
 Family CERATOMYXIDAE Doflein, 1899
 Genus *Leptotheca* Thelohan, 1895
55. *Leptotheca apogoni* Narasimhamurti, Kalavati, Anuradha and Padma Dorothy, 1990
56. *Leptotheca assymetrica* Lalitha Kumari, 1969
57. *Leptotheca latesi* Chakravarty, 1943
58. *Leptotheca macronesi* Chakravarty, 1943
 Genus *Ceratomyxa* Thelohan, 1892
59. *Ceratomyxa cyanoglossi* Das, Pal and Ghosh, 1988
60. *Ceratomyxa daysciaenae* Sarkar and Pramanik 1994

61. *Ceratomyxa dissimilaris* Narasimhamurti, Kalavati, Anuradha and Padma Dorothy, 1990
 62. *Ceratomyxa etroplusi* Rajendran and Janardanan, 1992
 63. *Ceratomyxa gobioidesi* Chakravarty, 1939
 64. *Ceratomyxa hilsae* Chakravarty, 1939
 65. *Ceratomyxa kudoii* Kalavati and Anuradha, 1993
 66. *Ceratomyxa nengae* Sarkar, 2004
 67. *Ceratomyxa priacanthi* Kalavati, Padma Dorothy and Paul Pandian, 2002
 68. *Ceratomyxa sagarica* Choudhury and Nandi, 1973
 69. *Ceratomyxa sagarsampadae* Narasimhamurti, Kalavati, Anuradha and Padma Dorothy, 1990
 70. *Ceratomyxa scatophagi* Chakravarty, 1943
 71. *Ceratomyxa tenulosae* Sarkar and Pramanik, 1994
 72. *Ceratomyxa tartoori* Sarkar, 1986
 73. *Ceratomyxa thrissoclesi* Padma Dorothy, Kalavati and Vaidehi, 1998
- Family SPHAEROSPORIDAE Davis, 1917
- Genus *Sphaerospora* Thelohan, 1892
74. *Sphaerospora mayi* Moser, Kent and Dennis, 1989
 75. *Sphaerospora corsulae* Sarkar and Ghosh,
- Genus *Palliatius* Schulman, Koveleva and Dubina, 1979
76. *Palliatius indicus* Padma Dorothy and Kalavati, 1998
- Genus *Myxobilatus* Davis, 1917
77. *Myxobilatus anguillaris* Basu and Haldar, 2003
 78. *Myxobilatus fossilis* Susha and Janardanan, 1994
 79. *Myxobilatus mastacembeli* Qadri and Lalitha Kumari, 1965
 80. *Myxobilatus notoapterus* Kalavati and Vaidehi, 1996
 81. *Myxobilatus odontamblyopusi* Basu and Haldar, 2004
 82. *Myxobilatus* sp. Anuradha and Kalavati, 1987
- Family CHLOROMYXIDAE Thelohan, 1892
- Genus *Chloromyxum* Mingazzini, 1890

83. *Chloromyxum amphipnoui* Ray, 1933
84. *Chloromyxum clariasum* Sarkar, 1994
85. *Chloromyxum heteropneustes* Rajendran and Janardanan, 2005
86. *Chloromyxum hoarei* Lalitha Kumari, 1969
87. *Chloromyxum meglitschi* Sarkar, 1982
88. *Chloromyxum mitchelli* Kalavati and Narasimhamurti, 1984b
89. *Chloromyxum mrigalae* Tripathi, 1952
90. *Chloromyxum puntiusi* Rajendran and Janardanan, 2005
91. *Chloromyxum tripathii* Kalavati and Narasimhamurti, 1984b
92. *Chloromyxum* sp. Tripathi, 1952
- Family PARVICAPSULIDAE Schulman, 1953
- Genus *Parvicapsula* Schulman, 1953
93. *Parvicapsula hoffmanni* Padma Dorothy and Kalavati, 1993
- Genus *Neoparvicapsula* Gavaeskaya, Kovaleva and Schulman, 1982
94. *Neoparvicapsula monolata* Sarkar, 1999
- Family AUERBACHIDAE Evadakimova, 1973
- Genus *Auerbachia* Meglitsch, 1968
95. *Auerbachia chakravartyi* Narasimhamurti, Kalavati, Anuradha, Padma Dorothy, 1990
96. *Auerbachia chorinemusi* Padma Dorothy, Kalavati and Vaidehi, 1998
- Family NEOTHELOHANELLIDAE Sarkar and Misra, 1996
- Genus *Neothelohanellus* Das and Haldar, 1986
97. *Neothelohanellus catlae* Das and Haldar, 1986
- Genus *Lomosporous* Gupta and Khera, 1988
98. *Lomosporous krishnagarensis* (Das and Haldar, 1986) emend. Sarkar and Misra, 1996
99. *Lomosporous indicus* Gupta and Khera, 1988
- Suborder PLATYSPORINA Kudo, 1919
- Family MYXOBOLIDAE Thelohan, 1892
- Genus *Myxobolus* Butschli, 1882

100. *Myxobolus aligarhensis* Bhatt and Siddiqui, 1964
101. *Myxobolus ampullaceus* Lalitha Kumari, 1969
102. *Myxobolus andhrae* (Lalitha Kumari 1969) emend. Gupta and Khera, 1988
103. *Myxobolus anili* Sarkar, 1989
104. *Myxobolus attui* Sarkar, 1985
105. *Myxobolus bankimi* Sarkar, 1999
106. *Myxobolus barbi* Tripathi, 1952
107. *Myxobolus batae* Karamchandani, 1970
108. *Myxobolus bengalensis* Chakravarty and Basu, 1948
109. *Myxobolus bhadrensis* Seenappa and Manohar, 1981
110. *Myxobolus bhadurius* (Sarkar, 1985) emend. Gupta and Khera, 1988
111. *Myxobolus bivacuolatus* Narasimhamurti and Kalavati, 1986
112. *Myxobolus buccoroofus* Basu and Haldar, 2004
113. *Myxobolus calbasui* Chakravarty, 1939
114. *Myxobolus calcariferum* Basu and Haldar, 2003
115. *Myxobolus carnaticus* Seenappa and Manohar, 1981
116. *Myxobolus cartilaginis* Hoffman, Putz and Dunbar 1965
117. *Myxobolus catlae* Chakravarty, 1943
118. *Myxobolus catmrigalae* Basu and Haldar, 2003
119. *Myxobolus cerebralis* Hofer, 1903
120. *Myxobolus chakravartyi* Haldar, Das and Sharma, 1983
121. *Myxobolus channai* (Kalavati, Sandeep and Narasimhamurti, 1981) emend. Gupta and Khera, 1988
122. *Myxobolus chilkensis* n. comb.
123. *Myxobolus chinsurahensis* Basu and Haldar, 2003
124. *Myxobolus clarii* Chakravarty, 1943
125. *Myxobolus coeli* Haldar, Samal and Mukhopadhyay, 1996
126. *Myxobolus crucifilus* (Qadri, 1962) emend. Landsberg and Lom, 1991
127. *Myxobolus curmucae* Seenappa and Manohar, 1981
128. *Myxobolus cuttacki* Haldar, Samal and Mukhopadhyay, 1996

129. *Myxobolus cylindricus* (Sarkar, Mazumdar and Pramanik, 1985)
emend. Landsberg and Lom, 1991
130. *Myxobolus dasgupti* Haldar, Samal and Mukhopadhyay, 1996
131. *Myxobolus dermatis* (Haldar, Mukherji and Kundu, 1981)
emend. Gupta and Khera, 1988
132. *Myxobolus edellae* Sarkar, 1999
133. *Myxobolus eeli* Mandal and Nair, 1975
134. *Myxobolus encephalicus* (Muslow, 1911)
135. *Myxobolus episquammalis* Egusa, Maeno and Sorimachi, 1990
136. *Myxobolus esomi* (Kalavati and Narasimhamurti, 1984)
emend. Landsberg and Lom, 1991
137. *Myxobolus etropi* Rajendran, Vijayan and Alvandi, 1989
138. *Myxobolus filamentosus* (Haldar, Mukherji and Kundu, 1985)
emend. Landsberg and Lom, 1991
139. *Myxobolus fossilii* n. comb.
140. *Myxobolus gangulyi* (Sarkar, Haldar and Chakraborti, 1982)
emend. Gupta and Khera, 1988
141. *Myxobolus goensis* Eiras and D'souza, 2004
142. *Myxobolus haldari* Gupta and Khera, 1989
143. *Myxobolus hosadurgensis* Seenappa and Manohar, 1981
144. *Myxobolus hyderabadense* (Lalitha Kumari, 1969)
emend. Gupta and Khera, 1988
145. *Myxobolus indiae* (Lalitha Kumari, 1969) emend. Gupta and Khera, 1988
146. *Myxobolus indicum* Tripathi, 1952
147. *Myxobolus indirae* (Kundu, 1985) emend. Gupta and Khera, 1988
148. *Myxobolus karnatakae* (Hagargi and Amoji, 1981)
emend. Landsberg and Lom, 1991
149. *Myxobolus koli* Lalitha Kumari, 1969
150. *Myxobolus labeosus* Sarkar, 1995
151. *Myxobolus lalithae* Gupta and Khera, 1988
152. *Myxobolus lizae* (Narasimhamurti and Kalavati, 1979)
emend. Landsberg and Lom, 1991

153. *Myxobolus macrolepi* Padma Dorothy and Kalavati, 1992b
154. *Myxobolus magauddi* (Bajpai, Haldar and Kundu, 1981)
emend. Gupta and Khera, 1988
155. *Myxobolus magurii* Sarkar, 1993
156. *Myxobolus mahendrae* Sarkar, 1986
157. *Myxobolus manoramae* Basu and Haldar, 2002
158. *Myxobolus maruliensis* (Sarkar, Mazumdar and Pramanik, 1985)
emend. Gupta and Khera, 1988
159. *Myxobolus mathuri* Jayasri, Parvateesam and Mathur, 1981
160. *Myxobolus meglitschus* Sarkar, 1996
161. *Myxobolus molae* Sarkar, 1993
162. *Myxobolus mrigalae* Chakravarty, 1939
163. *Myxobolus mrigalhitae* Basu and Haldar, 2003
164. *Myxobolus mugcephalus* (Narasimhamurti, Kalavati and Saratchandra, 1980)
emend. Landsberg and Lom, 1991
165. *Myxobolus mugilii* Haldar, Samal and Mukhopadhyay, 1996
166. *Myxobolus multivaderis* Mukhopadyay and Haldar, 1998
167. *Myxobolus mystusius* Sarkar, 1986
168. *Myxobolus narasii* (Narasimhamurti, 1970)
emend. Landsberg and Lom. 1991
169. *Myxobolus noblei* (Sarkar, 1982) emend. Gupta and Khera, 1988
170. *Myxobolus nodularis* Southwell and Prashad, 1918
171. *Myxobolus ophthalmasculata* Basu and Haldar, 2002
172. *Myxobolus orissae* Haldar, Samal and Mukhopadhyay, 2002
173. *Myxobolus osmaniae* Lalitha Kumari, 1969
174. *Myxobolus parsi* Das, 1996
175. *Myxobolus parvus* Schulmann, 1962
176. *Myxobolus pinnaurati* Lalitha Kumari, 1969
177. *Myxobolus potaili* Lalitha Kumari, 1969
178. *Myxobolus psilorhynchi* Lalitha Kumari, 1969
179. *Myxobolus punjabensis* Gupta and Khera, 1989a

180. *Myxobolus rewensis* Srivastava, 1978
 181. *Myxobolus rigida* Sarkar, 1999
 182. *Myxobolus rocatlae* Basu and Haldar, 2002
 183. *Myxobolus rohita* Haldar, Das and Sharma, 1983
 184. *Myxobolus saranae* Gupta and Khera, 1990
 185. *Myxobolus saranai* (Tripathi, 1953)
emend. Landsberg and Lom, 1991
 186. *Myxobolus saraswatii* Gupta and Saraswat, 1993
 187. *Myxobolus scatophagi* Haldar, Samal and Mukhopadhyay, 1996
 188. *Myxobolus serrata* Pagarkar and Das, 1993
 189. *Myxobolus shantipuri* Basu and Haldar, 2002
 190. *Myxobolus shetti* Seenappa and Manohar, 1981
 191. *Myxobolus seshadri* Laitha Kumari, 1969
 192. *Myxobolus sophorae* Jayasri, 1982
 193. *Myxobolus sphaeralis* Padma Dorothy and Kalavati, 1992b
 194. *Myxobolus spinocurvatura* Maeno, Sorimachi, Ogawa and Egusa, 1990
 195. *Myxobolus trichogasteri* (Sarkar, 1982)
emend. Gupta and Khera, 1988
 196. *Myxobolus tripathii* Kalavati, Sandeep and Narasimhamurti, 1981
 197. *Myxobolus undasuturiae* Sarkar, 1994
 198. *Myxobolus vanivilasae* Seenappa and Manohar, 1980
 199. *Myxobolus variformis* n. comb.
 200. *Myxobolus vedavatiensis* Seenappa and Manohar, 1981
 201. *Myxobolus venkateshi* Seenappa and Manohar, 1981
 202. *Myxobolus yogindrai* (Tripathi, 1953)
emend. Landsberg and Lom, 1991
 203. *Myxobolus* sp. Padma Dorothy and Kalavati, 1992b
- Genus *Henneguya* Thelohan, 1892
204. *Henneguya basari* (Bhatt and Siddiqui, 1964)
emend. Gupta and Khera, 1987
 205. *Henneguya bengalensis* (Ray Chaudhuri and Chakravarty, 1970)
emend. Gupta and Khera, 1987

206. *Henneguya bicornuata* (Ray Chaudhuri and Chakravarty, 1970)
emend. Gupta and Khera, 1987
 207. *Henneguya bleekeri* Haldar and Mukherjee, 1985
 208. *Henneguya chaudhuryi* (Bajpai and Haldar, 1982)
emend. Gupta and Khera, 1987
 209. *Henneguya ganapatiae* Qadri, 1970
 210. *Henneguya latesi* Tripathi, 1952
 211. *Henneguya megalopsi* Kalavati, Venkataeswara Rao and Vaidehi, 1991
 212. *Henneguya mystasi* Haldar, Samal and Mukhopadhyay, 1997
 213. *Henneguya mystusia* Sarkar, 1985
 214. *Henneguya namae* Haldar, Das and Sharma, 1983
 215. *Henneguya nandi* Gupta and Khera, 1987
 216. *Henneguya notoapterae* Qadri, 1965
 217. *Henneguya ophicephali* Chakravarty, 1939
 218. *Henneguya otolithi* Ganapati, 1941
 219. *Henneguya qadrii* Lalitha Kumari, 1965
 220. *Henneguya renalis* Sarkar, Mazumdar and Pramanik, 1985
 221. *Henneguya ritae* (Bajpai and Haldar, 1982)
emend. Gupta and Khera, 1987
 222. *Henneguya rubicundi* Haldar and Mukherjee, 1985
 223. *Henneguya singhi* Lalitha Kumari, 1969
 224. *Henneguya tachysuri* Gopinathamenon, 1986
 225. *Henneguya thermalis* Seenappa, Manohar and Prabhu 1981
 226. *Henneguya waltairensis* Narasimhamurti and Kalavati, 1975
 227. *Henneguya zahoori* Bhatt and Siddiqui, 1964
- Genus *Neohenneguya* Tripathi, 1952
228. *Neohenneguya tetraradiata* Tripathi, 1952
- Genus *Thelohanellus* Kudo, 1933
229. *Thelohanellus andhrae* Qadri, 1962

230. *Thelohanellus auerbachii* Sarkar, 1987
231. *Thelohanellus avijiti* Basu and Haldar, 2003
232. *Thelohanellus batae* Lalitha Kumari, 1969
233. *Thelohanellus bengalensis* Sarkar and Ray Choudhury, 1986
234. *Thelohanellus bifurcata* Basu and Haldar, 1999
235. *Thelohanellus boggoti* Qadri, 1962
236. *Thelohanellus calbasui* Tripathi, 1952
237. *Thelohanellus catlae* Chakravarty and Basu, 1948
238. *Thelohanellus caudatus* Pagarkar and Das, 1993
239. *Thelohanellus chandannagarensis* Basu and Haldar, 2003
240. *Thelohanellus chelae* Lalitha Kumari, 1969
241. *Thelohanellus chilensis* Kalavati and Vaidehi, 1991
242. *Thelohanellus chrysopomati* Lalitha Kumari, 1969
243. *Thelohanellus coeli* Sarkar and Mazumder, 1983
244. *Thelohanellus endodermis* Mukhopadhyay and Haldar, 2004
245. *Thelohanellus gangeticus* Tripathi, 1952
246. *Thelohanellus jiroveci* Kundu and Haldar, 1981
247. *Thelohanellus mrigalae* Tripathi, 1952
248. *Thelohanellus narasimhamurtius* Sarkar, 1994
249. *Thelohanellus ophthalmicus* Haldar, Das and Sharma, 1983
250. *Thelohanellus orissae* Haldar, Samal and Mukhopadhyay, 1997
251. *Thelohanellus parastromataei* Narasimhamurti, Kalavati, Anuradha and Padma Dorothy, 1990
252. *Thelohanellus potaili* Lalitha Kumari, 1969
253. *Thelohanellus pyriformis* Thelohan, 1892
254. *Thelohanellus qadrii* Lalitha Kumari, 1969
255. *Thelohanellus rodgi* Hagargi, Kundu and Haldar, 1979
256. *Thelohanellus rohita* (Southwell and Prasad, 1918)
emend. Chakravarty, 1943
257. *Thelohanellus sanjibi* Sarkar and Ghosh, 1990

258. *Thelohanellus seni* (Southwell and Prasad, 1918)
emend. Chakravarty and Basu, 1948
259. *Thelohanellus shortii* Qadri, 1967
260. *Thelohanellus sudevi* Sarkar and Ghosh, 1990
261. *Thelohanellus wallagoi* Sarkar, 1980
- Genus *Unicauda* Davis, 1944
262. *Unicauda andhrae* Kalavati and Narasimhamurti, 1981
263. *Unicauda aplocheili* Kalavati, Venkataeswara Rao and Vaidehi, 1991
264. *Unicauda armati* Gupta and Khera, 1987
265. *Unicauda irregularis* Haldar, Samal and Mukhopadhyay, 1997
266. *Unicauda minuta* Haldar, Samal and Mukhopadhyay, 1997
267. *Unicauda theraponi* Haldar, Samal and Mukhopadhyay, 1997
- Genus *Phlogospora* Qadri, 1962
268. *Phlogospora mysti* Qadri, 1962
269. *Phlogospora oculatus* Susha and Janardanan, 1995
- Order MULTIVALVULIDA Schulman, 1959
- Family TRILOSPORIDAE Schulman, 1959
- Genus *Unicapsula* Davis, 1924
270. *Unicapsula chirocentrusi* Sarkar, 1993
271. *Unicapsula maxima* Sarkar, 1999
- Family KUDOIDAE Meglitsch, 1960
- Genus *Kudoa* Meglitsch, 1947
272. *Kudoa atropi* Sandeep, Kalavati and Narasimhamurti, 1986
273. *Kudoa bengalensis* Sarkar and Mazumder, 1983
274. *Kudoa cascasia* Sarkar and Ray Choudhury, 1993
275. *Kudoa chilkenis* Tripathi, 1952
276. *Kudoa coibori* Sarkar, 1999
277. *Kudoa haridasae* Sarkar and Ghosh, 1991
278. *Kudoa sagarica* Das, 1996
279. *Kudoa sphyraeni* Narasimhamurti and Kalavati, 1979

280. *Kudoa tachysuræ* Sarkar and Mazumdar, 1983
281. *Kudoa tetraspora* Narasimhamurti and Kalavati, 1979
282. *Kudoa valamugili* Kalavati and Anuradha, 1993

7. SYSTEMATIC ACCOUNT

Phylum MYXOZOA Grasse, 1960

(Classification according to Lom and Noble, 1984; revised Lom and Dykova, 1992)

Class MYXOSPOREA Butschli, 1881

Order BIVALVULIDA Schulman, 1959

Suborder SPHAEROMYXINA Lom and Noble, 1984

Family SPHAEROMYXIDAE Lom and Noble, 1984

Spore elongated, sometimes slightly curved, with two polar capsules lying at the opposite tapering, truncate ends, opening at the level of the sutural line, connecting both ends and bisecting the spore; one uninucleate plasmodium; valves smooth or ridged.

Genus *Spahaeromyxa* Thelohan, 1892

Diagnosis : With the characters of the family.

Key to the species

1. Spore slightly arched in front and sutural view 4
2. Spore fusiform, more or less S-shaped in sutural view 5
3. Spore curved or boomrang-like; suture bent, thick-walled and ridged, polar capsule broadly pyriform to oval *S. chacundae*
- 4.1 Sutural line more or less parallel to the long axis of the spore, polar capsule long, pyriform and with truncate ends *S. pultai*
- 4.2 Sutural line curved and not parallel to the long axis of the spore, polar capsule ellipsoid *S. dighae*
- 5.1 Polar capsule oval to ellipsoidal, spore measuring 27.55 μm x 7.8 μm
..... *S. hareni*
- 5.2 Polar capsule pyriform, spore measuring 19.8 μm x 5.4 μm *S. theraponi*
- 5.3 Polar capsule pyriform, spore measuring 17.5 μm x 4.48 μm *S. ganapatii*
- 5.4 Polar capsule broadly pyriform to oval, spore measuring 18.2-22.7 (20.09) μm x 4.56-5.9 (5.37) μm *S. diacanthusa*

1. *Sphaeromyxa chacundae* Sarkar, 2004
(Fig. 3 a-d)

Diagnosis : Spore either curved and boomerang-shaped in valvular view; broadest in the middle and sides narrowing down towards the ends or spatula-like or very elongate 'S' shaped; shell valves equal and symmetrical, with 4-6 deep striations; suture bent, thick-walled and ridged; polar capsules two, one on each end, equal and broadly pyriform; polar filament ribbon-like, forming 3-4 folds running parallel to the long axis of the spore while inside the capsule.

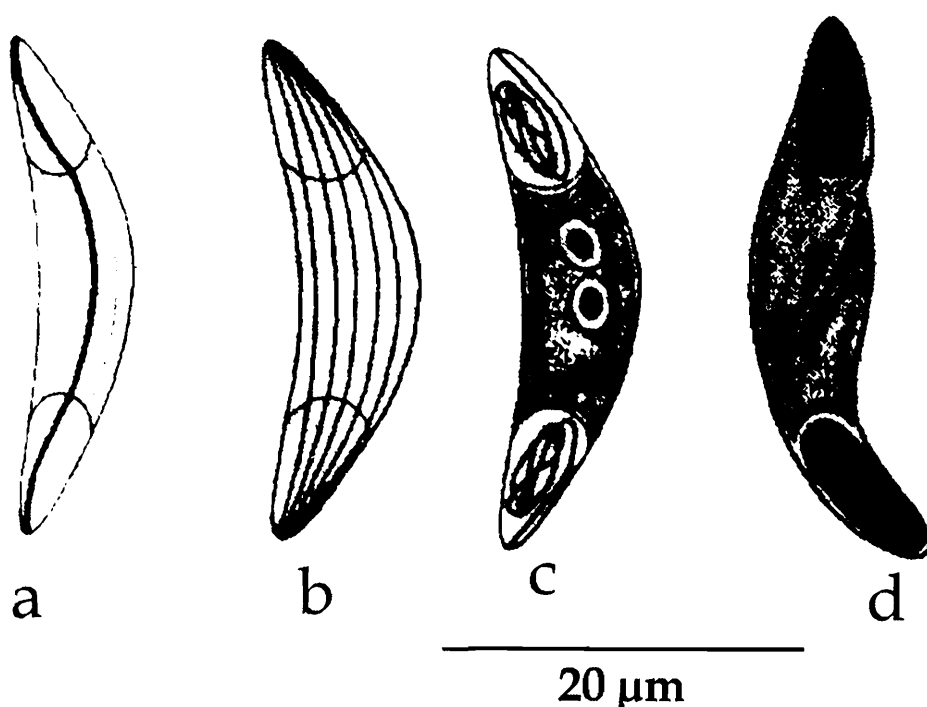


Fig. 3. *Sphaeromyxa chacundae* : a. Fresh spore sutural view; b. Valvular view, c. Spore stained with Giemsa; d. Spore treated with iodine

Size : Spore length 20.5-23.5 (21.57) μm , width 5.5-6.5 (6.12) μm ; polar capsule length 6.5-8.0 (7.65) μm , width 2.5-3.5 (2.96) μm .

Host : *Anodontostoma chacunda* (Ham-Buch); *site of infection* : gall bladder; *pathogenicity* : not apparent.

Distribution : India : West Bengal (Coastal waters of Bay of Bengal).

2. *Sphaeromyxa diacanthusa* Sarkar, 2004
(Fig. 4 a-c)

Diagnosis : Spore almost fusiform, ends bluntly rounded and sides parallel to slightly convex; shell valves symmetrical, thin-walled with 4-6 striations; sutural line moderately thick; polar capsules two, one on each end, equal and broadly pyriform to oval; polar filament ribbon-like, forming 3-4 horizontal folds while inside the capsule.

Size : Spore length 18.2-22.7 (20.09) μm , width 4.6-5.9 (5.37) μm ; polar capsule length 4.5-5.3 (5.1) μm , width 3.5-4.2 (3.67) μm .

Host : *Protonibea diacanthus* (Lacepede); **site of infection** : gall bladder; **pathogenicity** : not apparent.

Distribution : India : West Bengal (Coastal water of Bay of Bengal, Digha, Medinipur district).

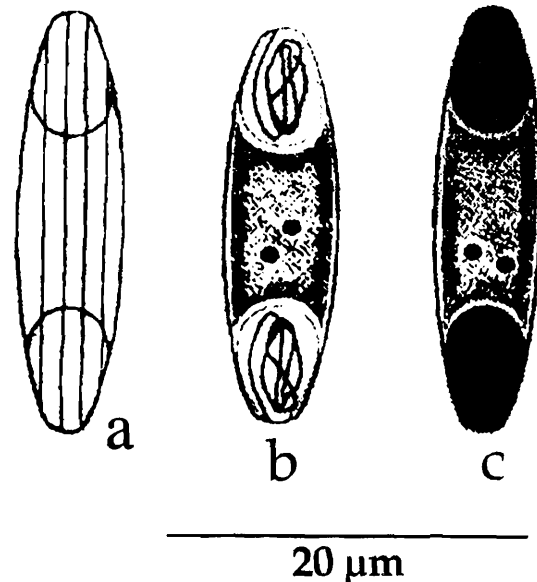


Fig. 4. *Sphaeromyxa diacanthusa* : a. Fresh spore valvular view, b. Spore stained with Giemsa; C. Spore treated with iodine

3. *Sphaeromyxa dighae* Sarkar and Mazumdar, 1983b.
(Fig. 5 a-b)

Diagnosis : Spore large, broad and bent in the middle forming an angle of 140 degrees in valvular view, arched in sutural view; shell valve smooth, elongated and curved, suture curved; polar capsules two, one on each end, subterminal and ellipsoidal; polar filament ribbon-like, forming 4-5 coils while inside the capsule.

Size : Spore length 21.0-25.0 (22.22) μm , width 2.8-4.5 (3.23) μm ; polar capsule length 7.0-10.0 (8.43) μm , width 1.8-3.0 (2.32) μm .

Host : *Hilsa ilisha* (Ham.); **site of infection** : gall bladder; **pathogenicity** : not known.

Distribution : India : West Bengal (Medinipur district).

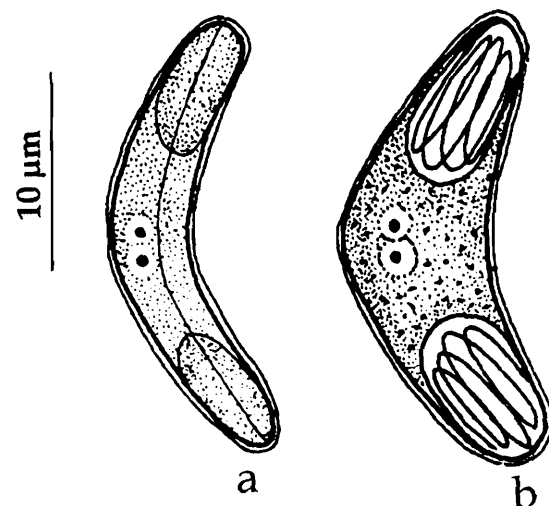


Fig. 5. *Sphaeromyxa dighae* : a. Fresh spore stained with Giemsa, b. Fresh spore sutural view

4. *Sphaeromyxa ganapatii* Kalavati and Vaidehi, 1991b
(Fig. 6 a-c)

Diagnosis : Pansporospoblast disporous, 20.8-22.6 μm in size; spore crescent-shaped with rounded ends in front view, slightly curved with convex and concave sides in lateral view; shell valves smooth, sutural ridge not distinct; polar capsule two, one on each end, subterminal and pyriform with drawn out anterior end; polar filament ribbon-like, forming 5-6 coils while inside the capsule; sporoplasm oval, uninucleate occupying entire extracapsular region.

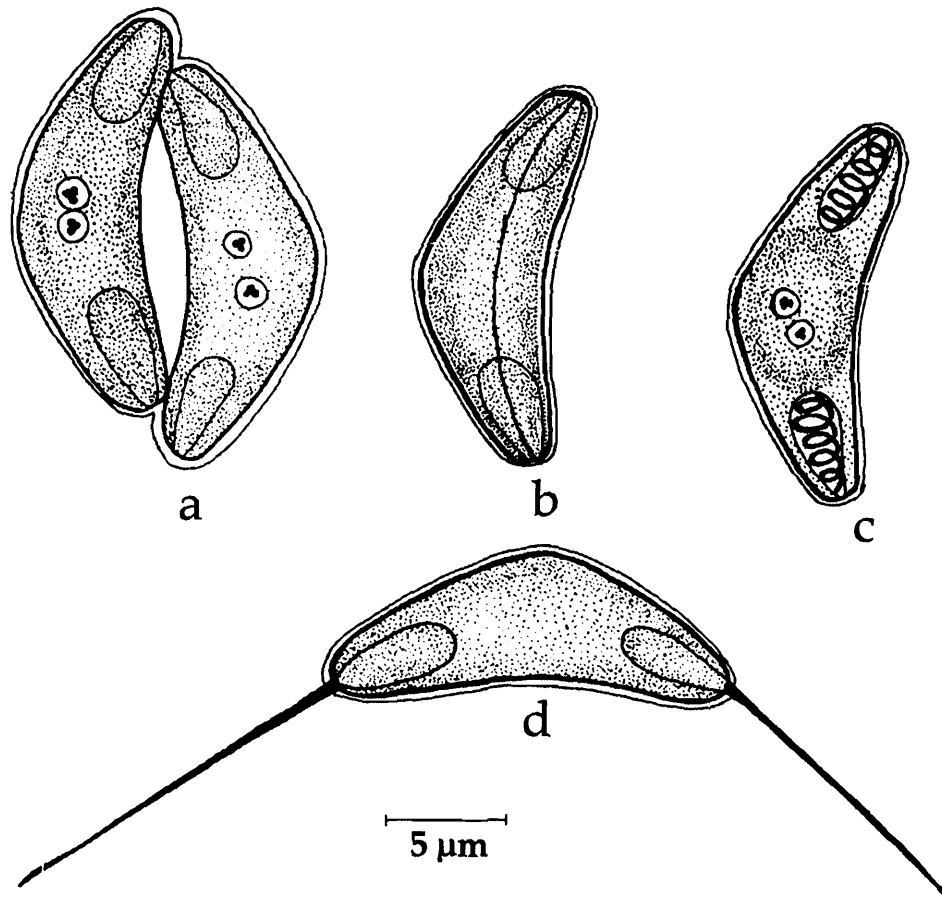


Fig. 6. *Sphaeromyxa ganapatii* : a. Disporous trphozoite, b. Fresh spore sutural view, c. Spore stained with Giemsa; d. Spore with extruded polar filaments

Size : Spore length 16.0-19.0 (17.5) μm , width 4.0-4.8 (4.48) μm , thickness 4.2-5.6 (5.02) μm ; polar capsule length 4.0-6.4 (5.6) μm , width 1.6-1.8 (1.64) μm ; polar filament length 20.2-26.8 (23.46) μm .

Host : *Therapon jarbua* (Forsk.); **site of infection** : gall bladder; **pathogenicity** : infected gall bladder hypertrophied, bile discoloured with agglutinated granules and gall bladder epithelium frayed.

Distribution : India : Orissa (Chilka Lake).

5. *Sphaeromyxa hareni* Sarkar, 1984a
(Fig. 7a-c)

Diagnosis : Trophozoites not found; spore fusiform in valvular view, sometimes slightly curved with round ends and almost "S"-shaped in sutural view; shell valve smooth, thin-walled with 'S'-shaped sutural line; polar capsule ovoid to ellipsoidal; polar filament thin and long; sporoplasm filling the extracapsular space.

Size : Spore length 23.35-28.95 (27.55) μm , width 5.6-8.87 (7.8) μm , thickness 4.6-5.6 (5.14) μm ; polar capsule length 8.87-10.27 μm , width 3.0-5.1 μm ; polar filament length 32.69-37.36 (34.5) μm .

Host : *Tachysurus platystomus* (Day); **site of infection** : gall bladder; **pathogenicity** : not apparent

Distribution : India : West Bengal (Digha coast of Bay of Bengal, Medinipur district).

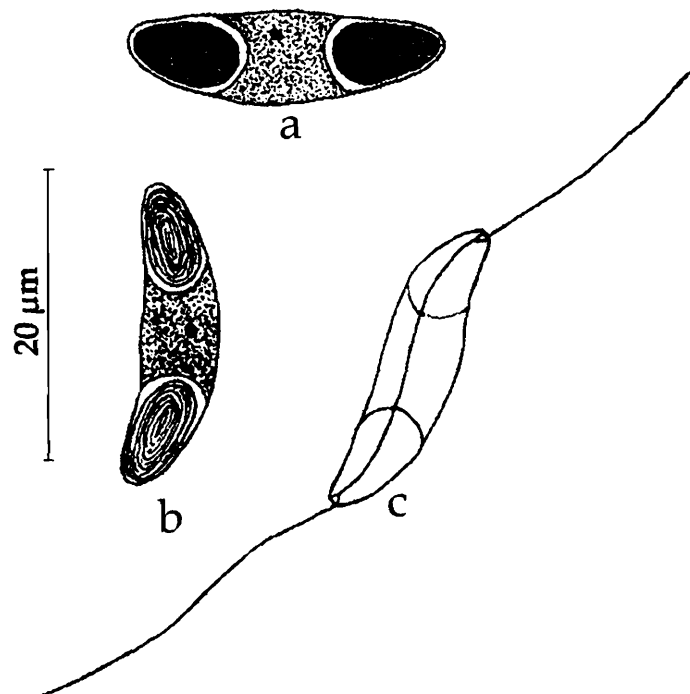


Fig. 7. *Sphaeromyxa hareni* : a. Fresh spore valvular view, b. Spore treated with iodine, c. Spore with extruded polar filaments

6. *Sphaeromyxa opisthopterae* Sarkar, 1999a
(Fig. 8 a-e)

Diagnosis : Trophozoites seen in the gall bladder; plasmodia di- or polysporic, 31.75 μm x 14.75 μm ; spore small, elongated or fusiform, ends truncated; shell valve

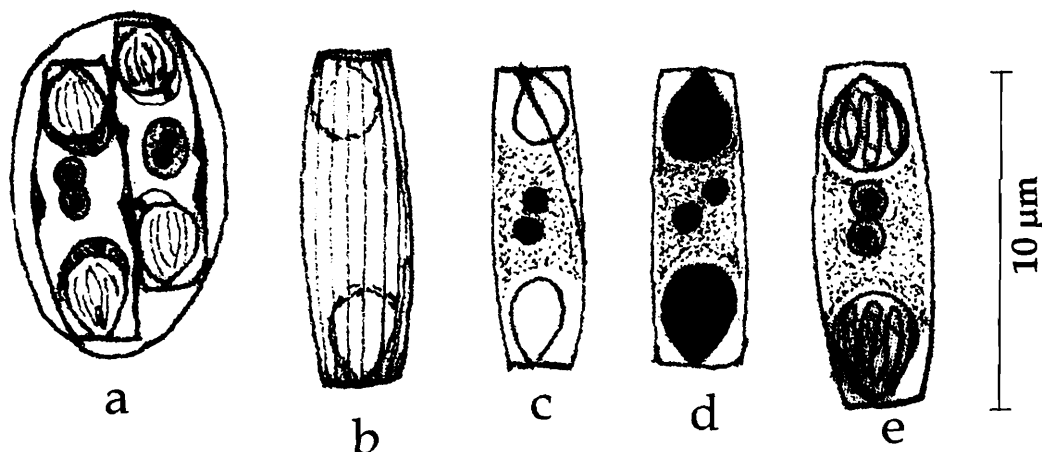


Fig. 8. *Sphaeromyxa opisthopterae* : a. Disporous trophozoite, b. Fresh spore valvular view, c. Spore treated with iodine, d. Fresh spore sutural view, e. Spore stained with Giemsa

symmetrical, longitudinally striated, with fine ornamentation; sutural line 'S'-shaped; polar capsule oval or broadly pyriform; polar filament folded longitudinally; sporoplasm filling the extracapsular space.

Size : Spore length 9.0-12.74 (11.5) μm , width 3.28-4.55 (3.9) μm , thickness 4.6-5.6 (5.14) μm ; polar capsule length 2.63-3.82 (3.6) μm , width 1.8-3.0 (2.82) μm .

Host : *Opisthopterus tardoore* (Day); *site of infection* : gall bladder; *pathogenicity* : not apparent.

Distribution : India : West Bengal (Digha coast of Bay of Bengal, Medinipur district).

7. *Sphaeromyxa pultai* Tripathi, 1952

(Fig. 9 a-b)

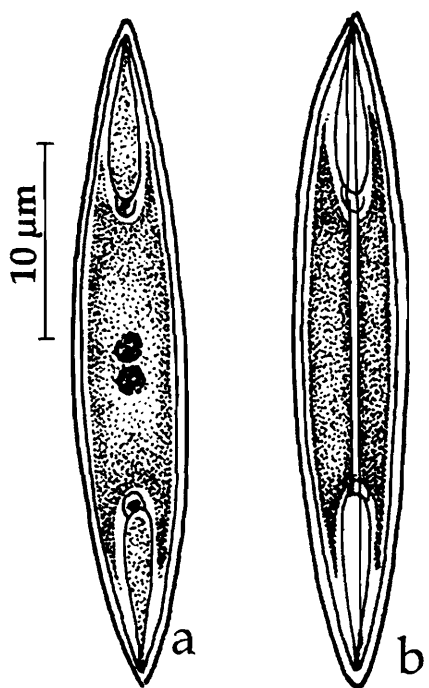


Fig. 9. *Sphaeromyxa pultai* : a. Fresh spore valvular view, b. Sutural view

Diagnosis : Young trophozoite circular 4.5 μm in diameter, mature trophozoite mono or disporous, measuring 12.6-13.9 μm , and 19-27.3 μm respectively; spore long with truncated ends, two sides slightly curved in front and sutural view; shell valves thin and smooth; sutural line more or less parallel to the long axis of the spore, sutural ridge absent; polar capsule long, pyriform with truncated ends; sporoplasm granular, not filling the whole of the extra-capsular cavity.

Size : Spore length 28.8-30.0 μm , width 5-5.5 μm .

Host : *Odontamblyopus rubicundus* (Ham.); *site of infection* : gall bladder; *pathogenicity* : not apparent.

Distribution : India : West Bengal (North 24-Parganas district).

8. *Sphaeromyxa theraponi* Tripathi, 1952

(Fig. 10 a-d)

Diagnosis : Spore arched in front view, one side more arched than the other; 'S'-shaped in sutural view; sutural line 'S'-shaped, thin and distinct; sutural ridge absent, shell valve thin and smooth; polar capsule small, pyriform with truncated ends; sporoplasm filling most of the extracapsular cavity.

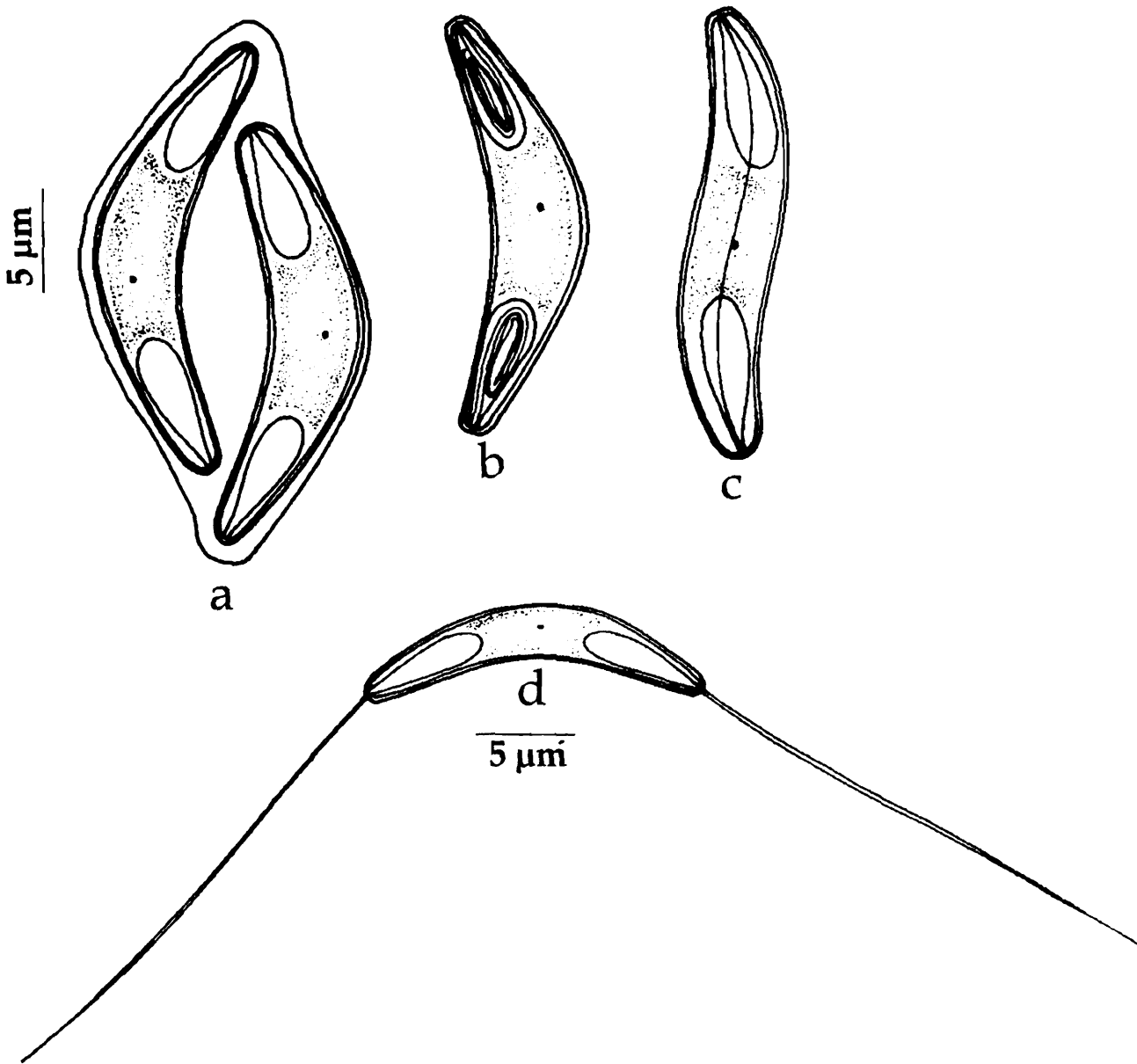


Fig. 10. *Sphaeromyxa theraponi* : a. Disporous trophozoite, b. Spore stained with Giemsa, c. Fresh spore sutural view, d. Spore with extruded polar filaments

Size : Spore length 19.8 μm, width 5.9 μm; polar capsules length 7.2 μm, width 2.7 μm.

Host : *Therapon jarbua* (Forsk.); **site of infection :** gall bladder; **pathogenicity :** not apparent.

Distribution : India : West Bengal (South 24-Parganas district).

Suborder VARIISPORINA Lom and Noble, 1984

Key to the Families

1. Spores with polar capsules located at either pole or widely separated..... 3
2. Spores with polar capsules located at the anterior pole 4
3. Spores spindle-shaped/sigmoid or crescentic; polar capsules located along the sutural plane at the opposite ends; sutural line longitudinal, straight or curved
..... MYXIDIIDAE
- 4.1 Spores with 2 polar capsules 5
- 4.2 Spores with 2 or 4 polar capsules 6
- 4.3 Spores with 1 polar capsule 7
- 5.1 Spores spherical to irregularly ellipsoidal, bilaterally symmetrical; sutural line straight; polar capsules wide apart in sutural plane, capsular foramina directed away from each other ORTHOLINEIDAE
- 5.2 Spores spherical or inversely pyramidal with or without caudal or lateral projections; polar capsules anterior, spherical or sub-spherical and perpendicular to sutural line; sutural line sinuous, often 'S'-shaped SINUOLINEIDAE
- 5.3 Spores with shell valves elongated, drawn out in the plane perpendicular to sutural line; sutural line transverse, central and straight; shell valves symmetrical or asymmetrical; polar capsule spherical or sub-spherical, perpendicular to sutural line CERATOMYXIDAE
- 5.4 Spores spherical or pyramidal with tapering anterior end or elongated often with appendages; polar capsules located at the anterior tip, perpendicular to straight sutural line SPHAEROSPORIDAE
- 6.1 Spores spherical, sub-spherical or elongated with or without caudal appendages; sutural line straight, meridional, bisecting the spore; polar capsules 4, at the apex either one pair in the level of the sutural line and second pair perpendicular or both pairs diagonally beyond the level of suture CHLOROMYXIDAE
- 6.2 Spores thin-walled, asymmetrical, elongated in sutural plane; shell valves unequal; sutural line curved; polar capsules 2 to 4, conspicuously small at the apex
..... PARVICAPSULIDAE
- 7.1 Spores with asymmetric, unequal, smooth shell valves and single elongated polar capsule with a few longitudinal coils of the filament AUERBACHIDAE

- 7.2 Spores oval, ellipsoid or globular, valves symmetrical, single polar capsule placed either perpendicular or angular to the longitudinal axis of the spore, opening laterally NEOTHELOHANELLIDAE

Family MYXIDIIDAE Thelohan, 1892

Diagnosis : As in the key.

Key to the genera

1. Spores fusiform, straight or slightly crescentic or sigmoid with more or less pointed ends; shell valves smooth or with ridges; sutural line straight, bisecting the spore; 2 pyriform polar capsules situated one at either end of the spore; capsular foramina lying in the sutural plane at or near the end of the spore and usually open in opposite directions; sporoplasm binucleate, located between the capsules, usually coelozoic, occasionally histozoic; in marine and freshwater fishes, rarely in amphibians *Myxidium*
2. Spores ellipsoidal in sutural view, slightly bent or semicircular in valvular view with rounded bluntly pointed ends; sutural line straight, curved or sinuous; polar capsules almost spherical, usually open slightly subterminally and both to one side; sporoplasm binucleate, coelozoic in marine and freshwater fishes *Zschokkella*
3. Spore ellipsoidal, rounded in transverse section; polar capsule single, elongated, pyriform; capsular foramen in the sutural plane, sutural line sigmoid; one binucleate sporoplasm; trophozoite mono to polysporous; coelozoic in marine fishes *Coccomyxa*

Genus *Myxidium* Bütschli 1882 (= *Cystodiscus*, Lutz, 1889)

Diagnosis : As in the key.

Key to the species

1. Shell valve smooth and non-striated 3
2. Shell valve striated 4
- 3.1 Spore fusiform
 - 3.1.1 Both extremities of spore drawn out into transparent needle-like structures
..... *M. boddaerti*
 - 3.1.2 Large, over 30 μm in length *M. apocryptae*
 - 3.1.3 Small, less than 20 μm in length with 'S'-shaped sutural ridge *M. fasciatum*

- 3.1.4 More arched on upper side, shell valve not 'S'-shaped *M. islampurium*
- 3.2 Spore elongately oval
- 3.2.1 Spores with pointed extremities and pyriform polar capsule *M. glossogobi*
- 3.2.2 Spores with pointed extremities and spherical or oval polar capsules
..... *M. mystusium*
- 3.3 Spore cylindrical
- 3.3.1 Spores small, less than 20 μm in length with 'S'-shaped sutural ridge
..... *M. notopterum*
- 4 .1 Spores fusiform to ovoidal or spindle-shaped
- 4.1.1 Spores with drawn out extremities *M. lieberkunhi*
- 4.1.2 Spore more or less spindle-shaped with bluntly pointed extremities, 14.42 μm x
6.18 μm *M. heteropneustesi*
- 4.1.3 Spore slightly curved, with one side more convex than the other, measuring 11.4
-12.6 μm x 5.4-6.4 μm ; shell valves uniformly thick, asymmetrical with 8–10
striations *M. aori*
- 4.1.4 Spore broadly fusiform *M. batae*
- 4.1.5 Spore with finely curved or nearly 'S'-shaped valves *M. sciaenae*
- 4.1.6 Spore with almost acuminate ends, 16.5–19.5 (18.6) μm x 9.0–10.5 (9.95) μm ,
shell valves transparent with many striations *M. menodae*
- 4.1.7 Spore arched on upper surface, suture 'S'-shaped *M. leptocephalichthysum*
- 4.1.8 Spore fusiform slightly twisted into 'S'-shape with pointed ends *M. molnari*
- 4.2 Spores cylindrobiconical
- 4.2.1 Shell valves straight *M. striatusi*
- 4.2.2 Shell valves bent with a depression in the center *M. attuum*
- 4.3 Spores rectangular with rounded ends /dumb bell-shaped *M. papernae*
- 4.4 Spores elongated and fusiform with pointed ends; 23-27 μm x 6-8 μm in size...
..... *M. calcariferi*
- 4.5 Spore elliptical with round extremities; 12.66 μm x 6.46 μm in size *M. labeonis*

9. *Myxidium aori* Lalitha Kumari, 1969
(Fig. 11 a-c)

Diagnosis : Spores fusiform with flat ends, slightly curved, with one side more convex than the other; shell valves uniformly thick, asymmetrical with 8–10 striations; sutural ridge wide and straight, sutural line fine; polar capsules oval or pyriform; polar filament forming 4–5 oblique coils while inside the capsule, thin and uniform when extended; sporoplasm granular, homogenous, occupying the space between the capsules.

Size : Spore length 11.4–13.6 (12.6) μm , width 5.4–7.1 (6.4) μm ; polar capsule length 3.6–4.3 (4.1) μm , width 2.1–2.9 (2.7) μm ; polar filament length 73–118 (94.5) μm .

Host : *Macrones aor*; **site of infection** : gall bladder; **pathogenicity** : not apparent.

Distribution : India : Andhra Pradesh (Hyderabad and Warangal districts).

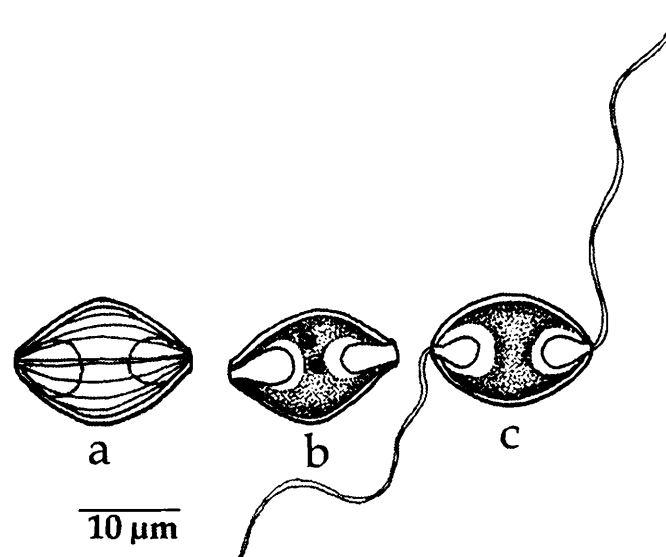


Fig. 11. *Myxidium aori* : a. Fresh spore valvular view, b. Spore stained with Giemsa, c. Spore with extruded polar filaments

10. *Myxidium apocryptae* Bajpai and Haldar, 1982c
(Fig. 12 a-c)

Diagnosis : Mature spore more or less spindle-shaped with pointed extremities; valves very thin without any striations; polar capsules equal, elongated, pyriform; polar filaments not forming any coils but remained entangled in the capsule; polar filaments unequal; sporoplasm granular and located in between the two polar capsules; iodophilous vacuole absent.

Size : Spore length 30.7–38.2 (32.2) μm , width 4.2–6.6 (5.1) μm ; polar capsule length 9.1–12.5 (11.0) μm , width 2.5 μm ; polar filament length (short) 9.1–15.8 (12.3) μm , (long) 66.4–87.5 (74.5) μm .

Host : *Apocryptes bato* Ham; **site of infection** : gall bladder; **pathogenicity** : not apparent.

Distribution : India : West Bengal (Kalyani, Nadia district).

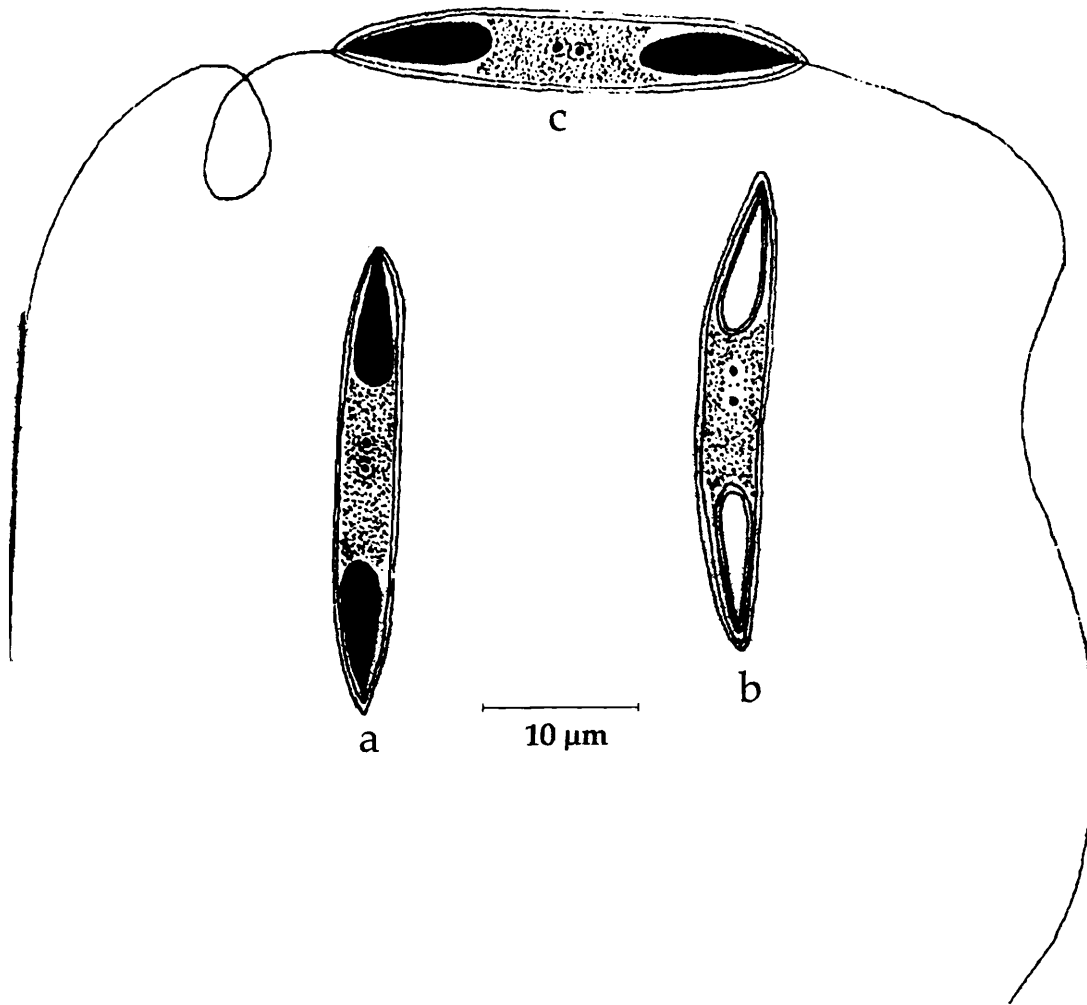


Fig. 12. *Myxidium apocryptae* : a. Fresh spore valvular view, b. Spore stained with Giemsa, c. Spore with extruded polar filaments

11. *Myxidium attuam* Sarkar, 2004

(Fig. 13 a-c)

Diagnosis : Spore cylindrobiconical to fusiform, ends not pointed; shell valves symmetrical, with 6-9 striations and a depression at the center; sutural line straight or bent, thin, not ridged; polar capsule broadly pyriform; polar filament forming 5-7 coils while inside the capsule; sporoplasm granular filling the extra capsular spore cavity; iodophilous vacuole absent.

Size : Spore length 23.8–28.9 (27.3) μm , width 9.5–11.9 (10.79) μm ; polar capsules length 6.8–10.2 (7.45) μm , width 2.5–3.0 (2.6) μm .

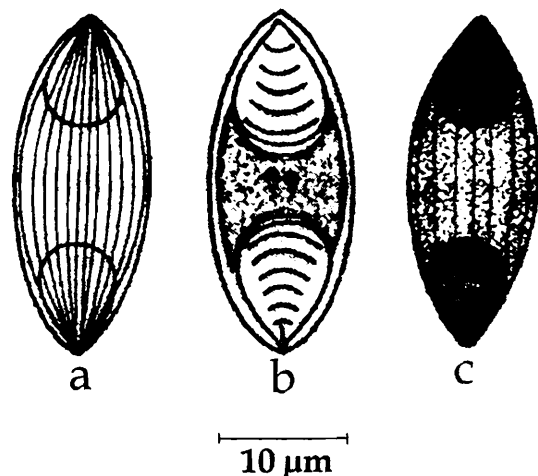


Fig. 13. *Myxidium attuam* : a. Fresh spore valvular view, b. Spore stained with Giemsa, c. Spore with treated with iodine

Host : *Wallago attu*; *site of infection* : gall bladder; *pathogenicity* : not apparent.

Distribution : India : West Bengal (exact locality not mentioned).

12. *Myxidium batae* Sarkar and Ghosh, 1991a
(Fig. 14 a-c)

Diagnosis : Spore broadly fusiform in valvular view and cylindrobiconical in sutural view with pointed ends; shell valve thick and striated with 7-10 longitudinal striations converging towards the ends; sutural line thin; polar capsules equal in size, pyriform to ovoidal; sporoplasm finely granular filling the intercapsular space.

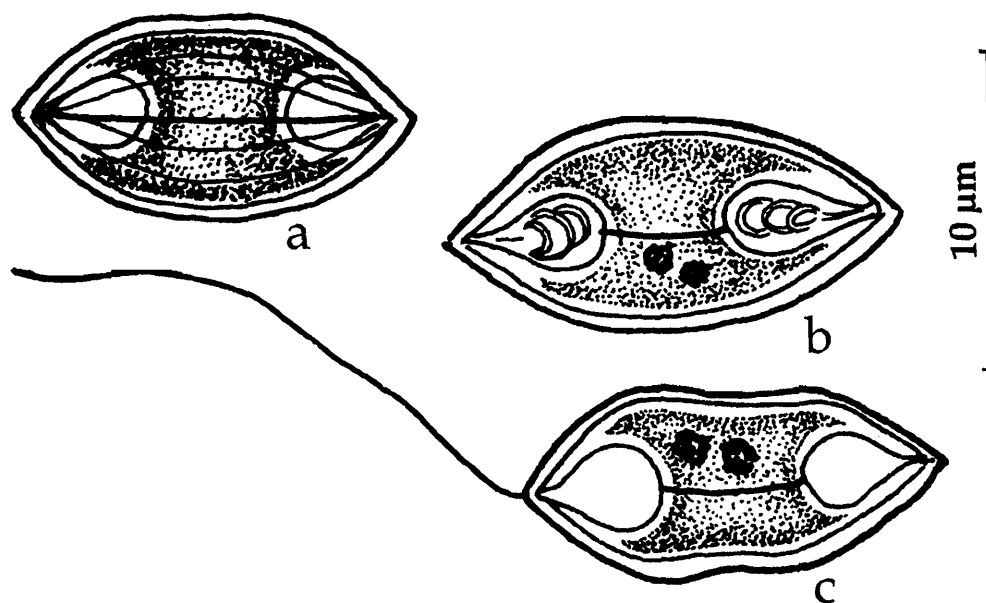


Fig. 14. *Myxidium batae* : a. Fresh spore valvular view, b. Spore stained with Giemsa, c. Spore with extruded polar filaments

Size : Spore length 14.0–17.0 (15.43) μm , width 6.0–8.0 (6.92) μm ; polar capsule length 3.5–4.5 (3.97) μm , width 2.5–3.0 (2.82) μm .

Host : *Labeo bata* (Ham); *site of infection* : gall bladder; *pathogenicity* : not apparent.

Distribution : India : West Bengal (Chinsurah, Hugli district)

13. *Myxidium boddaerti* Choudhury and Nandi, 1973
(Fig. 15 a-c)

Diagnosis : Spore fusiform with both the extremities drawn out into transparent needle-like structures; shell valve thick and smooth; sutural line indistinct; polar capsules equal in size, pyriform; sporoplasm granular and filling the extracapsular space.

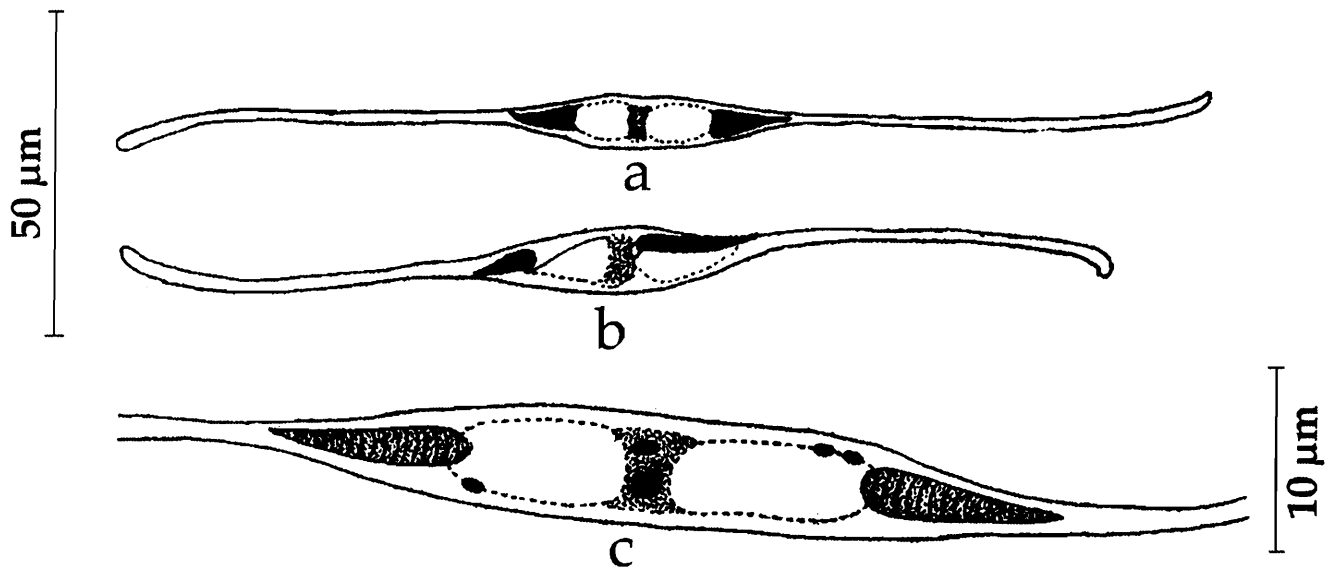


Fig. 15. *Myxidium boddaerti* : a & b. Fresh spore valvular view, b. Spore enlarged view

Size : Spore length 133.3–166.8 μm, width 6.4–8.3 μm; polar capsule length, 7.4–10.3 μm, width 3.0–4.0 μm.

Host : *Boleophthalmus boddaerti* Palbs; *site of infection* : gut; *pathogenicity* : not apparent.

Distribution : India : West Bengal (South 24 Parganas district)

14. *Myxidium calcariferi* Chakravarty, 1943

(Syn. *Myxidium procerum* var. *caliariferi* Chakravarty, 1943)

(Fig. 16 a-b)

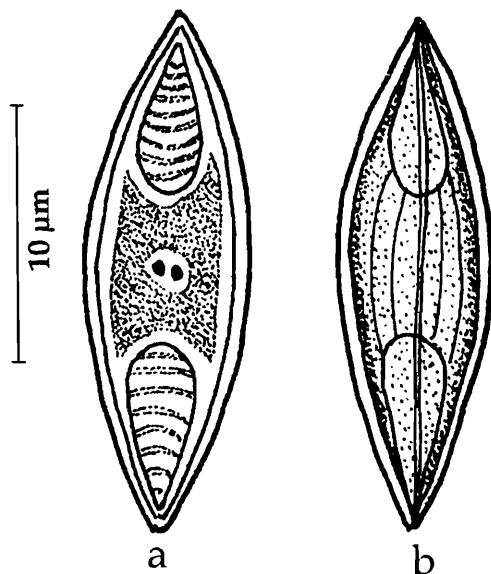


Fig. 16. *Myxidium calcariferi* : a. Fresh spore valvular view, b. Spore stained with Giemsa

Diagnosis : Spore elongately fusiform with pointed ends; shell valves longitudinally striated; sutural line indistinct; polar capsules equal in size, pyriform; sporoplasm granular and filling the extracapsular space.

Size : Spore length 23–27 μm, width 6.0–8.0 μm; polar capsule length 8.24 μm, width 4.12 μm.

Host : *Lates calcarifer*; *site of infection* : gall bladder; *pathogenicity* : not apparent.

Distribution : India : West Bengal (exact locality not mentioned).

15. *Myxidium fasciatum* Sarkar, 1985c
(Fig. 17 a-b)

Diagnosis : Vegetative form hyaline oval (17.6–22.5 μm x 12.8–19.0 μm) to spherical (19.0–21.0 μm in diameter), disporous; spore cylindrobiconical; polar capsule pear-shaped; polar filament having 2-3 coils while inside the capsule, short and ribbon-like when extended; iodonophilous vacuole absent.

Size : Spore length 14.4–17.6 (16.0) μm , width 5.6–6.4 (5.9) μm ; polar capsule length 4.0–4.8 (4.5) μm , width 3.2–4.8 (4.0) μm

Host : *Trichogaster fasciatus* Bl.; **site of infection :** gall bladder; **pathogenicity :** not apparent.

Distribution : India : West Bengal (North 24 Parganas district).

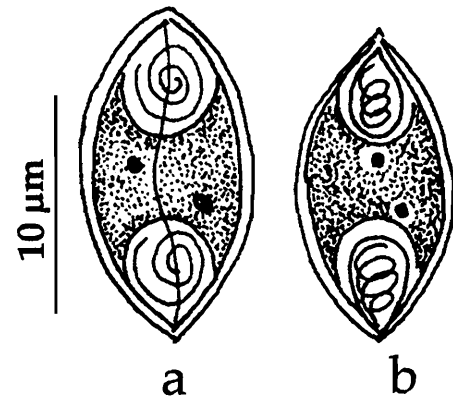


Fig. 17. *Myxidium fasciatum* : a. Spore sutural view, b. Spore valvular view

16. *Myxidium glossogobi* Chakravarty, 1939
(Fig. 18 a-d)

Diagnosis : Spore elongately oval with rounded extremities; shell valve nonstriated; sutural plane indistinct; polar capsules pyriform, one at each end of spore; shell slightly

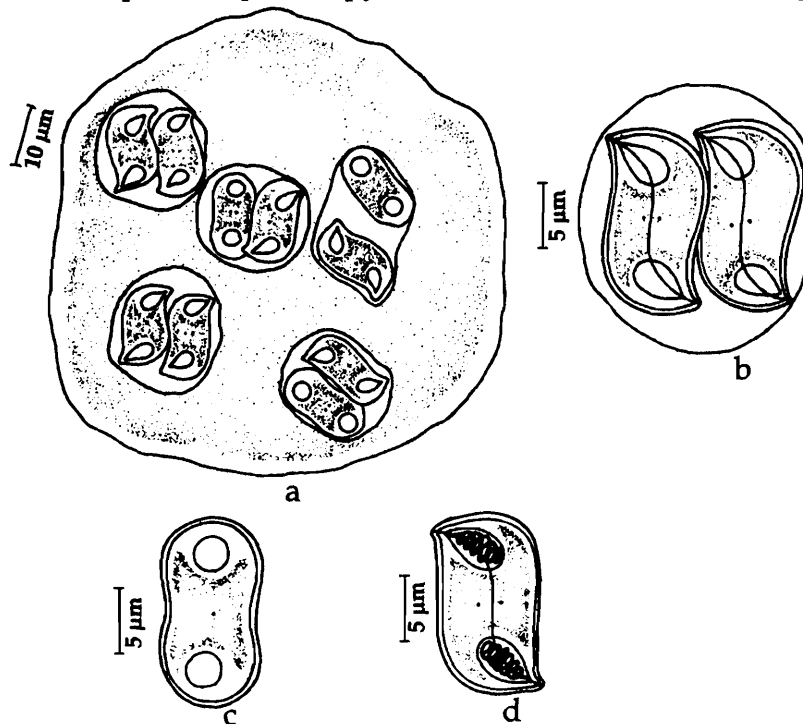


Fig. 18. *Myxidium glossogobi* : a. Trophozoite, b. Disporous trophozoite, c. Fresh spore valvular view, d. Spore stained with Giemsa (sutural view)

elevated in front of filament openings; polar filament thin, long; sporoplasm uniformly granular and located at the middle portion of the spore.

Size : Spore length 12-15 μm , width 8.5-10 μm ; polar capsule length 3.1-4.1 μm ; polar filament length 40-50 μm .

Host : *Glossogobius giuris* (Ham); *site of infection* : gall bladder; *pathogenicity* : not apparent.

Distribution : India : West Bengal (Calcutta district); Kerala (Veli Lake).

Remarks : Krishnakumar (2000) described this species from Kerala.

17. *Myxidium heteropneustes* Chakravarty, 1943

(Fig. 19 a-b)

Diagnosis : Spores more or less spindle-shaped with bluntly pointed extremities; shell valves striated; sutural line indistinguished among striations; polar capsule equal, slightly ovoidal with pointed anterior ends; sporoplasm granular, rectangular and located in the space between the polar capsules.

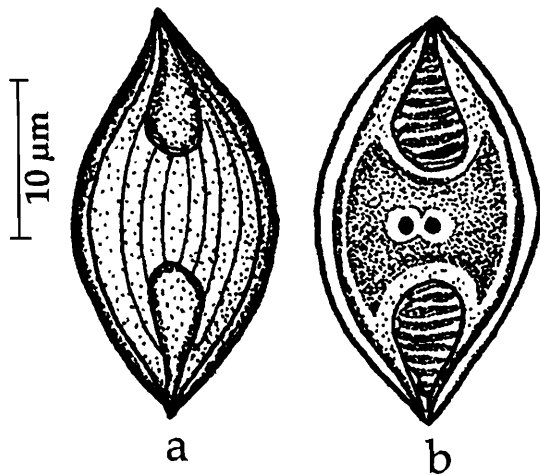


Fig. 19. *Myxidium heteropneustes* : a. Fresh spore valvular view, b. Spore stained with Giemsa

Size : Spore length 14.42 μm , width 6.18 μm ; polar capsule length 4.12-6.18 μm , width 4.12 μm .

Host : *Heteropneustes fossilis* (Bloch); *site of infection* : gall bladder; *pathogenicity* : not apparent.

Distribution : India : West Bengal (Calcutta district).

18. *Myxidium islampurium* Sarkar, Mazumdar and Pramanik, 1985

(Fig. 20 a-c)

Diagnosis : Spore almost fusiform in valvular view and more arched on the upper side, cylindrobiconical in sutural view; shell valve thin and smooth; suture thin and straight; polar capsule conical; polar filament forming 3-4 coils while inside the capsule; iodophilous vacuole absent.

Size : Spore length 8.5-12 (9.93) μm , width 3.0-6.0 (3.62) μm ; polar capsule length 3.0-4.5 (3.59) μm , width 2.0-3.0 (2.89) μm .

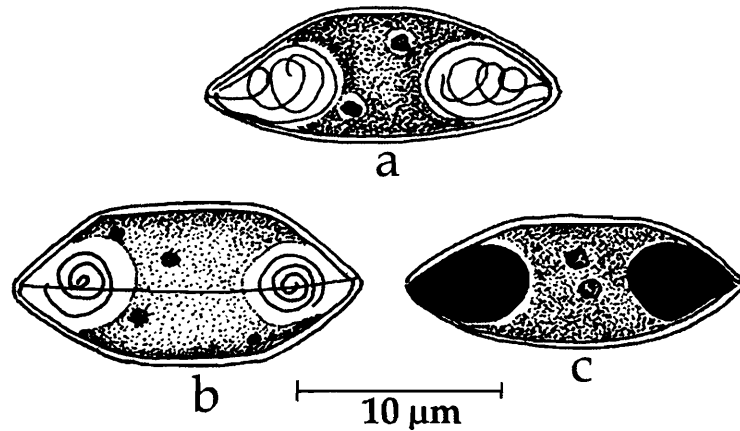


Fig. 20. *Myxidium islampurium* : a. Spore Stained with Giemsa, b. Spore sutural view, c. Spore treated with iodine

Host : *Channa marulius* Ham.; *site of infection* : gall bladder; *pathogenicity* : not apparent.

Distribution : India : West Bengal (Murshidabad district).

19. *Myxidium labeonis* Gupta and Khera, 1988d
(Fig. 21 a-c)

Diagnosis : Spore elliptical with rounded extremities; shell valves symmetrical with 5 longitudinal striations; suture fine, median, straight; polar capsule conical; polar filament forming 5 coils while inside the capsule; sporoplasm intercapsular, uniformly granular, uni or binucleate; iodophilous vacuole absent.

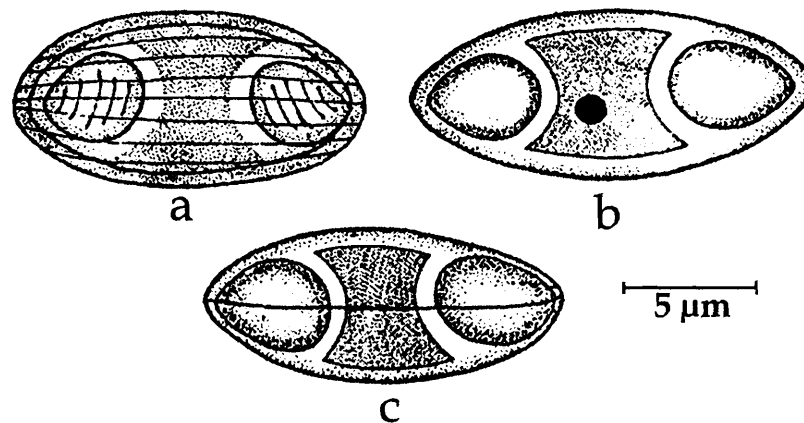


Fig. 21. *Myxidium labeonis* : a. Fresh spore valvular view, b. Spore stained with Giemsa, c. Spore sutural view

Size : Spore length 11.0–14.0 (12.66) µm, width 5.0–7.0 (6.46) µm; polar capsule length 3.0–5.0 (4.04) µm, width 2.0–5.0 (3.26) µm.

Host : *Labeo dero*, *L. dyocheilus* Ham.; *site of infection* : gall bladder; *pathogenicity* : not apparent

Distribution : India : Punjab (Ludhiana and Nangal districts).

20. *Myxidium leiberkuhni* Butschli, 1881
(Syn. *Myxidium mukundae* Sarkar, 1985c)
(Fig. 22 a-c)

Diagnosis : Spores fusiform with both extremities pointed; size variable; shell valves thin, striated; sutural line very faint; polar capsule pyriform, equal; polar filament thin.

Size : Spore length 12.4–15.0 μm , width 5–6 μm ; polar capsule length 4.12 μm , width 2.06 μm ; polar filament length 15 μm .

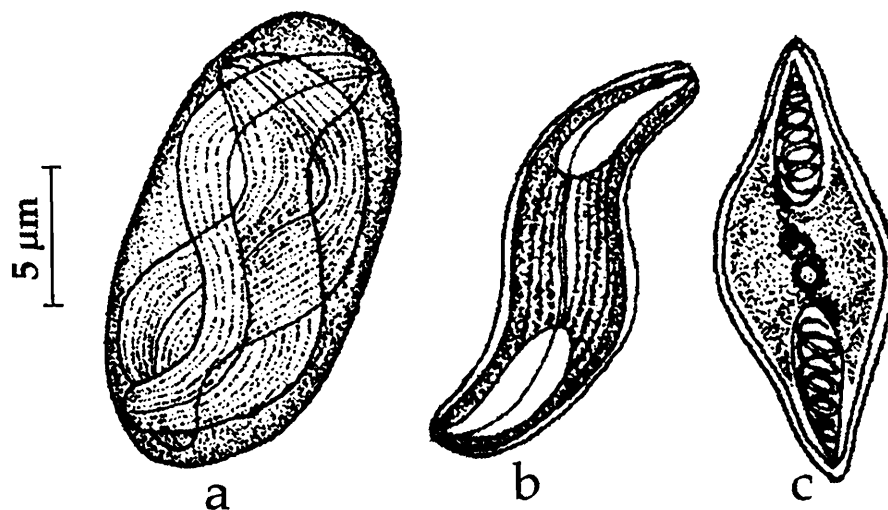


Fig. 22. *Myxidium leiberkuhni* : a. Disporous trophozoite, b. Fresh Spore sutural view, c. Spore Stained with Giemsa

Host : *Anabas testudineus* (Bloch), *Bolephthalmus boddarti* Palbs from India and *Esox lucinus* Linn., *Lota lota*, etc. from Canada, Europe and USA; **site of infection** : gall bladder; **pathogenicity** : not reported.

Distribution : India : West Bengal (Calcutta and South 24–Parganas districts); Andaman Sea. **Elsewhere** : This species has cosmopolitan distribution and was reported from a variety of hosts, both marine and freshwater fishes in Canada, U.S.A, Belgium, Czechoslovakia, France, Germany and USSR.

Remarks : *Myxidium leiberkuhni* Butschli (1882) is very widely distributed among marine and freshwater fishes, namely, *Acipenser sturio*, *Esox lucius*, *E. niger*, *E. reticularis*, *Lota lota*, *Lucius lucius*, *Anabas testudineus*, *Bolephthalmus boddarti* and *Porogadus miles* and is described from different geographical regions. The species is known to infect urinary bladder, ureters, urinary tubules and gall bladder. In India, Chakravarty (1943) recorded the species from the gall bladder of an anabantid fish, *Anabas testudineus*, Choudhury and Nandi (1973) reported from the gall bladder of a gobiid fish, *Bolephthalmus boddarti* and Kalavati *et al.* (2002) from the gall bladder of *Porogadus miles*. Spore size varying from 17.6–22.4 μm x 4.5–9.6 μm . Sarkar (1985c), however, considered Chakravarty's species as new and named it *M. mukundae* since the spore size was relatively small. Das *et al.* (1993) did not agree with Sarkar and preferred to retain *M. leiberkuhni* for Indian forms until further study and reexamination of material from the Indian hosts. For the present we consider *M. mukundae* as a junior synonym of *M. leiberkuhni*.

21. *Myxidium leptocephalicichthysum* Sarkar and Roy Choudhury, 1997
(Fig. 23 a-d)

Diagnosis : Cysts small; spore fusiform or cylindroconical, arched on upper surface and straight on lower surface in valvular view; shell valves symmetrical with 7-10 striations; suture oblique 'S'-shaped, sigmoid; polar capsule equal, broadly pyriform; polar filament forming 4-6 coils while inside the capsule; sporoplasm granular, filling the extracapsular cavity; iodophilous vacuole absent.

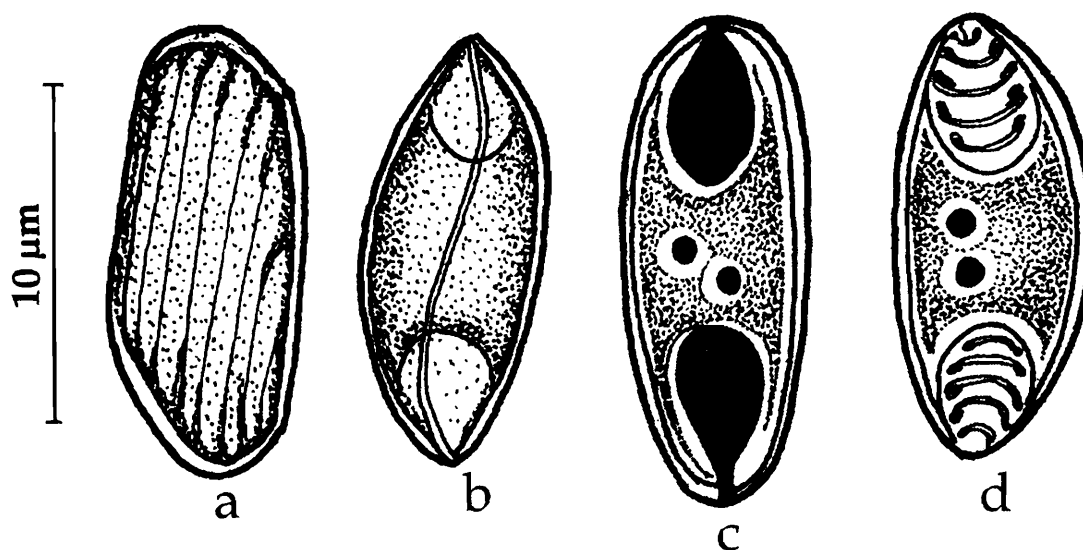


Fig. 23. *Myxidium leptocephalicichthysum* : a. Fresh spore valvular view, b. Fresh spore sutural view, c. Spore treated with iodine, d. Spore Stained with Giemsa

Size : Spore length 13.0–14.5 (13.85) μm , width 5.0–6.0 (5.2) μm ; polar capsule length 4.0–5.0 (4.42) μm , width 2.5–3.5 (3.05) μm .

Host : *Lepidocephalicichthys thermalis* (Ham.Buch.); **site of infection** : kidney; **pathogenicity** : not apparent.

Distribution : India : West Bengal (South 24 Paragnas district).

22. *Myxidium menodae* Sarkar, 2004
(Fig. 24 a-d.)

Diagnosis : Spore broadly fusiform to ovoidal with almost acuminate ends; shell valves transparent with many striations; suture straight or slightly bent; polar capsule equal, pyriform; polar filament having 5-7 coils, sporoplasm finely granular filling the extracapsular cavity; iodophilous vacuole absent.

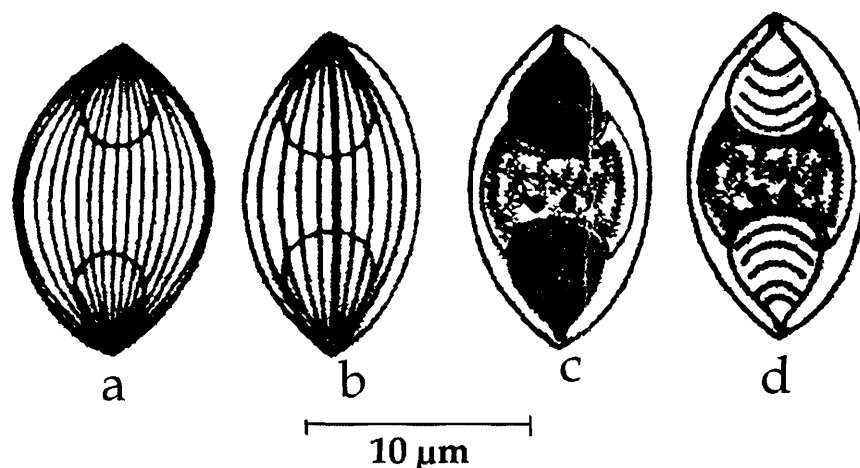


Fig. 24. *Myxidium menodae* : a. Fresh spore valvular view, b. Fresh spore sutural view, c. Spore treated with iodine, d. Spore Stained with Giemsa

Size : Spore length 16.5–19.5 (18.6) μm , width 9.0–10.5 (9.95) μm ; polar capsule length 4.5–6.75 (6.2) μm , width 4.25–6.0 (4.95) μm .

Host : *Aorichthys menoda menoda* (Ham.Buch.); *site of infection* : gall bladder; *pathogenicity* : not apparent.

Distribution : India : West Bengal.

23. *Myxidium molnari* Yatindra and Mathur, 1988

(Fig. 25 a-c)

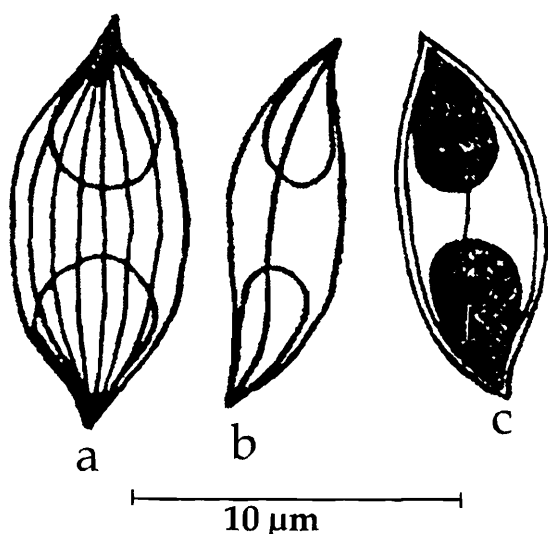


Fig. 25. *Myxidium molnari* : a. Disporous trophozoite, b. Fresh spore sutural view, c. Spore Stained with Giemsa

Diagnosis : Spores irregular, broad, fusiform and slightly twisted into S-form with pointed ends; shell valves transparent with 6-7 longitudinal striations; sutural line distinct in side view; polar capsule equal, pyriform; sporoplasm uninucleate; iodophilous vacuole absent.

Size : Spore length 8.34–10.09 (10.42) μm , width 2.92–5.00 (3.81) μm ; polar capsule length 3.34–5.00 (3.93) μm , width 2.08–3.34 (2.5) μm .

Host : *Cirrhina reba* (Ham.); *site of infection* : gall bladder; *pathogenicity* : not apparent.

Distribution : India : Punjab (Ajmer).

24. *Myxidium mystusium* Sarkar and Ray Choudhury, 1986
(Fig. 26a-c)

Diagnosis : Spore fusiform with pointed end; shell valve smooth; suture slightly curved, ridged and very distinct; polar capsule spherical to ovoidal, polar filament forming 4-5 coils while inside the capsule; sporoplasm granular, biconcave filling the extracapsular cavity; iodophilous vacuole absent.

Size : Spore length 11.0–16.65 μm ; width 5.0–7.49 μm ; polar capsule diameter 3.33–7.49 μm ; polar filament length 36.0 μm .

Host : *Mystus vittatus* Day; **site of infection** : gall bladder; **pathogenicity** : not apparent.

Distribution : India : West Bengal (Hugli district).

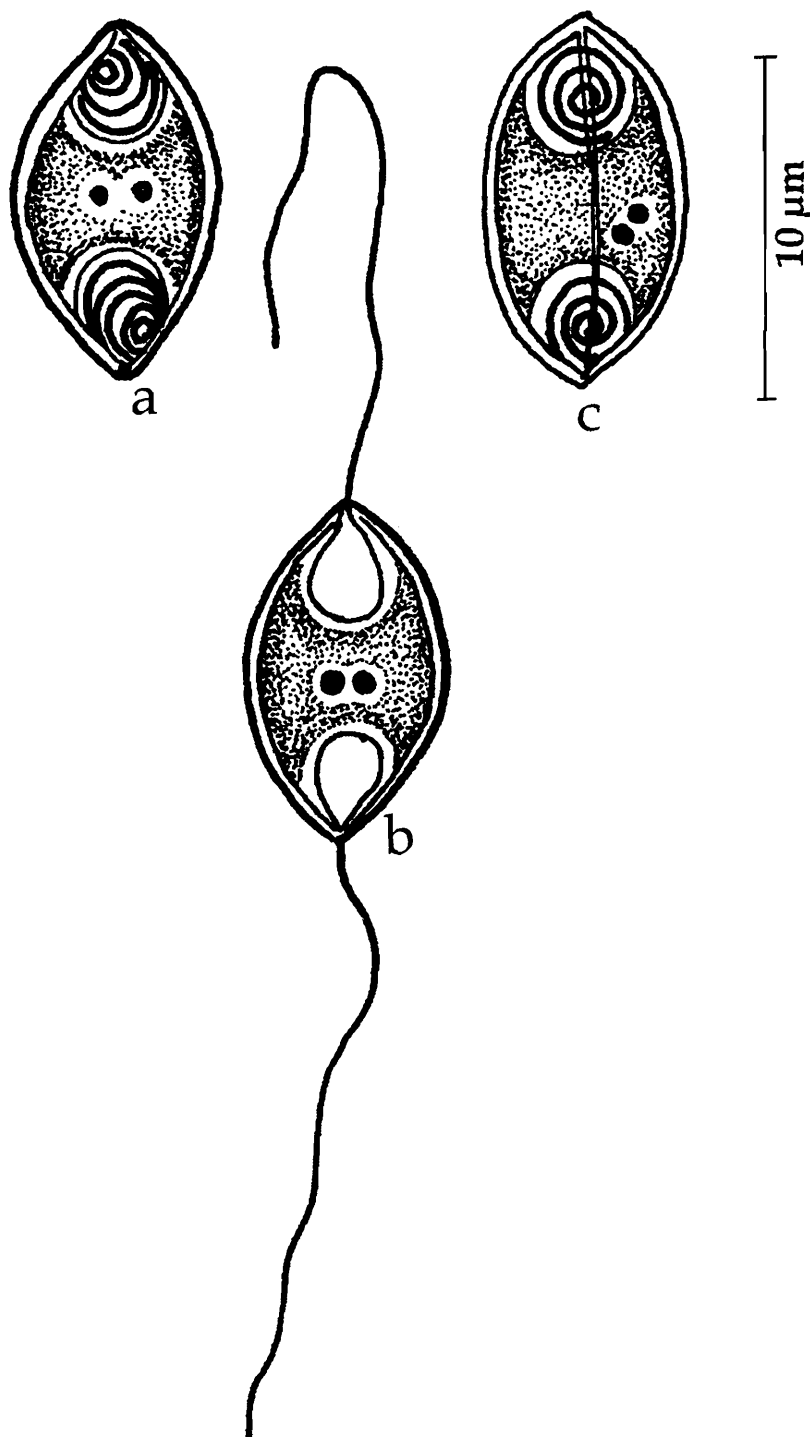


Fig. 26. *Myxidium mystusium* : a. Fresh spore valvular view, b. Fresh spore sutural view, c. Spore with extruded polar filaments

25. *Myxidium notopterum* Sarkar, 1996b

(Fig. 27 a-e)

Diagnosis : Spore cylindrical with rounded ends; shell valves smooth, symmetrical; suture 'S'-shaped; polar capsule spherical to oval; polar filament forming 3-4 coils while inside the capsule; sporoplasm granular, binucleate filling the extracapsular cavity; iodophilous vacuole absent.

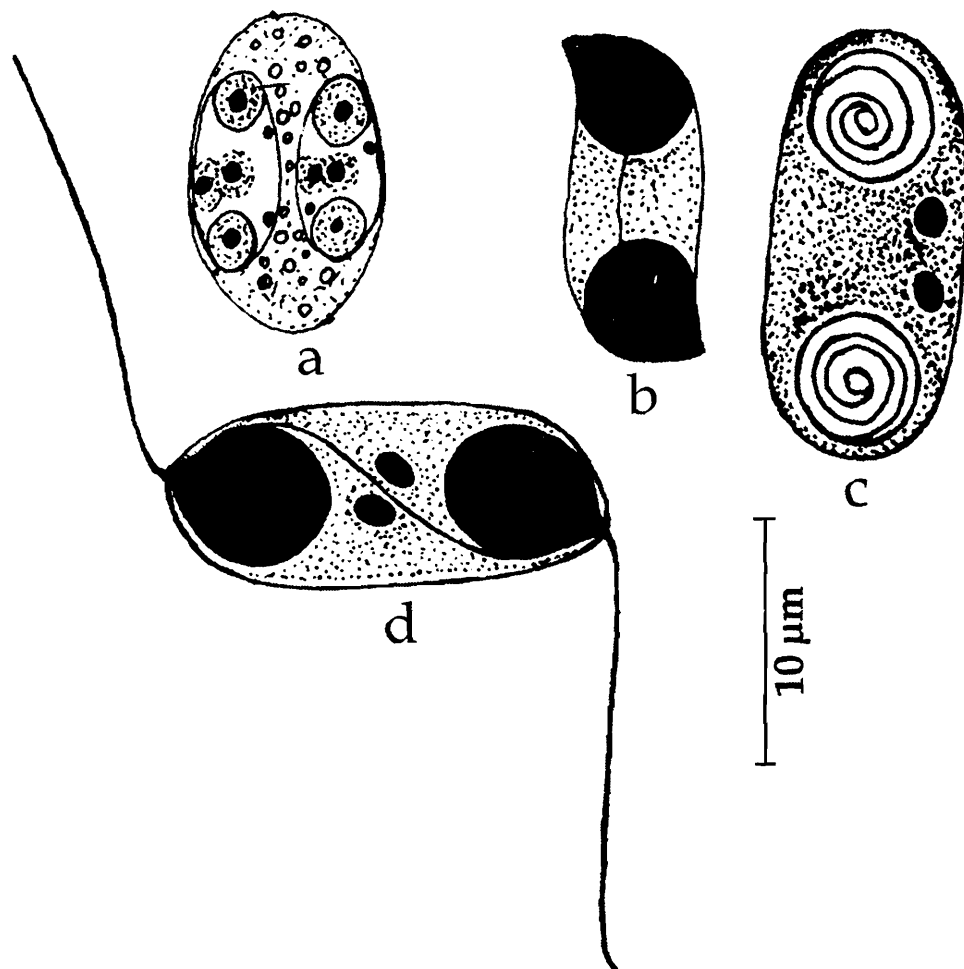


Fig. 27. *Myxidium notopterum* : a. Disporous trophozoite, b. Spore Stained with Giemsa, c. Fresh spore sutural view, d. spore with extruded polar filaments

Size : Spore length 13.5–16.5 (15.37) μm , width 7.0–9.0 (8.3) μm ; polar capsule (spherical) 4.5–6.0 (5.65) μm in diameter; polar capsule when oval, length 4.5–6.0 (5.65) μm , width 4.5–5.5 (5.05) μm .

Host : *Notopterus notopterus* Day; *site of infection* : liver; *pathogenicity* : not apparent.

Distribution : India : West Bengal (Hugli district).

26. *Myxidium papernae* Padma Dorothy and Kalavati, 1992a
(Fig. 28 a-b)

Diagnosis : Pansporoblast disporous; spores transparent, rectangular with rounded ends or dumb-bell-shaped; lateral walls concave; shell valves equal, striated, 4-5 striations seen on each valve; polar capsules spherical, terminal at either end of the spore; capsular foramina located at the tip of a beak-like projection; polar filament thin; sporoplasm hyaline, binucleate occupying the entire spore cavity.

Size : Spore length 9.6-14.4 (11.04) μm , width 4.8-8.0 (7.04) μm ; polar capsule 3.2-4.8 (3.36) μm in diameter; polar filament length 16.1-22.7 (22.5) μm .

Host : *Liza macrolepis*; **site of infection** : gall bladder; **pathogenicity** : infected gall bladder visibly distended.

Distribution : India : Andhra Pradesh (Gosthani Estuary, Bheemunipatnam and backwaters of Visakhapatnam, Bay of Bengal, Visakhapatnam district).

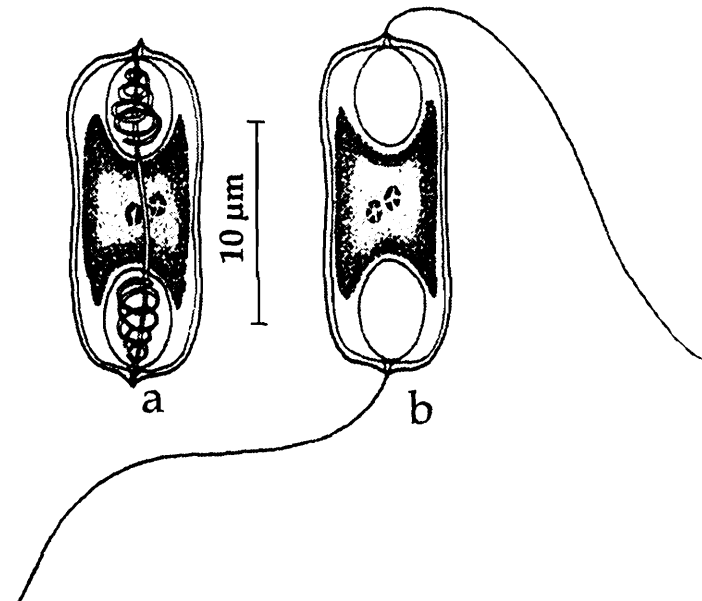


Fig. 28. *Myxidium papernae* : a. Spore stained with Giemsa, b. Spore with extruded polar filaments

27. *Myxidium sciaenae* Sarkar, 1986c
(Fig. 29 a-d)

Diagnosis : Spore fusiform both in valvular and sutural views; shell valves having 5-6 longitudinal striations; suture distinct, finely curved, nearly 'S'-shaped; polar capsules

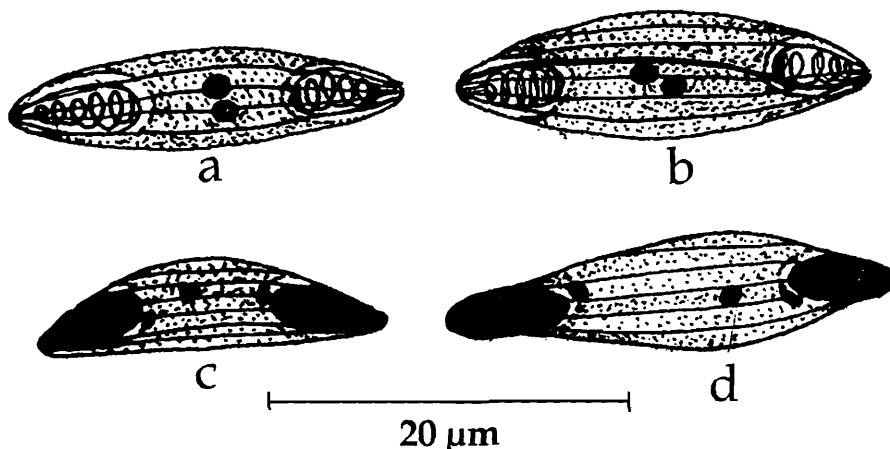


Fig. 29. *Myxidium sciaenae* : a & b. Spores Stained with Giemsa, c & d. Spores treated with iodine

small, pyriform; polar filament forming 6-7 coils while inside the capsule, sporoplasm filling the entire extracapsular biconcave cavity; iodophilous vacuole absent.

Size : Spore length $19.36 (\pm 0.47) \mu\text{m}$, width $5.32 (\pm 0.28) \mu\text{m}$; polar capsule length $5.2 (\pm 0.13) \mu\text{m}$, width $2.50 (\pm 0.12) \mu\text{m}$.

Host : *Sciaena bleekeri* Day; site of infection : gall bladder; pathogenicity : not apparent.

Distribution : India : West Bengal (Digha coast, Bay of Bengal).

28. *Myxidium striatusi* Sarkar, 1982b

(Fig. 30 a-b)

Diagnosis : Spore, cylindro-biconical in sutural view, bilobate in valvular view due to depression around the intercapsular region; shell valve with fine longitudinal striations; suture straight; polar capsules pyriform, open almost vertically to the sutural line; sporoplasm uninucleate, finely granulated, completely filling the extracapsular cavity.

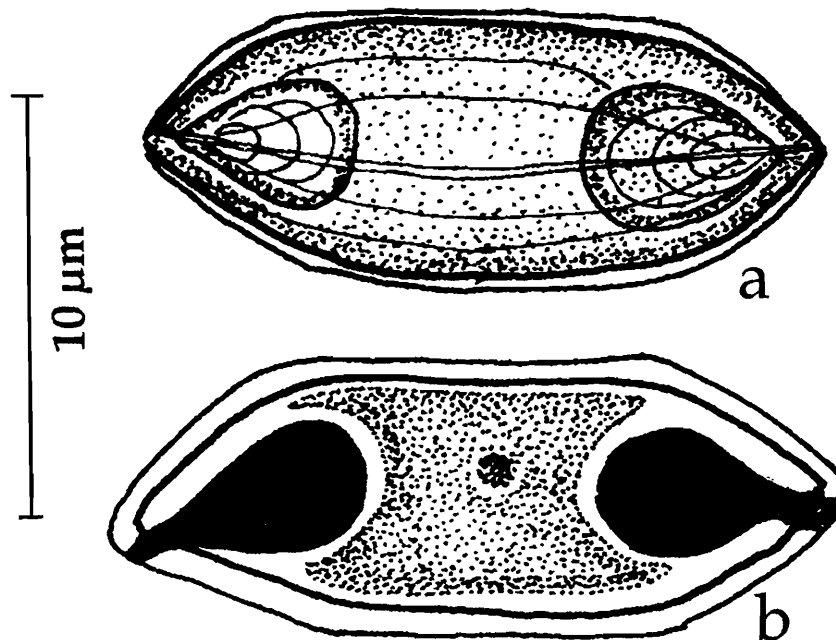


Fig. 30. *Myxidium striatusi* : a. Spore Stained with Giemsa, b. Spores treated with iodine

Size : Spore length $11.1-18.7 (14.53) \mu\text{m}$, width $4.7-7.0 (5.61) \mu\text{m}$; polar capsule length $3.7-5.6 (4.47) \mu\text{m}$, width $2.8-3.7 (3.04) \mu\text{m}$.

Host : *Ophicephalus striatus* Bloch; site of infection : gall bladder; pathogenicity : not reported.

Distribution : India : West Bengal (Hugli district).

Genus *Zschokkella* Aurebach, 1910

Diagnosis : As in the key.

Key to the species

1. Shell valves thin and smooth, suture thin and 'S'-shaped 3
2. Shell valves thin and striated, suture not 'S'-shaped 4
- 3.1 Spore broad, 10.50-12.25 μm x 6.50-7.35 μm , parasitic in marine fish *Tachysurus platystomus* *Z. platystomusi*
- 3.2 Spore narrow, 10.3 μm x 4.12-5.18 μm , parasitic in freshwater fish, *Heteropneustes fossilis* *Z. fossillae*
- 3.3 Spore ellipsoidal, large, 12.25 μm x 7.2 μm *Z. gobiensis*
- 3.4 Spore rectangular to ellipsoidal, with flat to rounded ends, 20.4 -23.8 μm x 10.2-2.7 μm *Z. cirrhinae*
- 3.5 Spores broadly oval with flat, truncate ends, 9.6-11.4 μm x 6.4 – 8.0 μm *Z. glossogobi*
- 3.6 Spore large, ellipsoidal with rounded ends, 8.0-10.5 μm x 6.5-8.0 μm *Z. cascasiensis*
- 3.7 Spore cylindrical, upper surface arched, 11.48 μm x 5.9 μm *Z. pseudosciaena*
- 4.1 Polar capsules spherical without a neck 5
- 4.2 Polar capsules spherical with a neck 6
- 5.1 Spore semicircular, 12.36 μm x 6.18 μm , striations longitudinal *Z. illishae*
- 5.2 Spore oval, transversely striated, 9-12 striae, 11.18-15.48 μm x 7.74-10.32 μm *Z. ganapatii*
- 5.3 Spores large, ellipsoidal with rounded ends, 16.5 -18.7 μm x 8.5-11.05 μm *Z. channae*
- 6.1 Spores hemispherical /gibbous, neck short, valves striated, 10-12 striae, 9.3-12.9 μm x 4.3–7.1 μm *Z. labeonis*
- 6.2 Spores ellipsoidal/gibbous with prominent neck, 12.9–14.3 μm x 5.0–7.1 μm *Z. ophicephali*

29. *Zschokkella cascasiensis* Sarkar, 1995b
(Fig. 31 a-e)

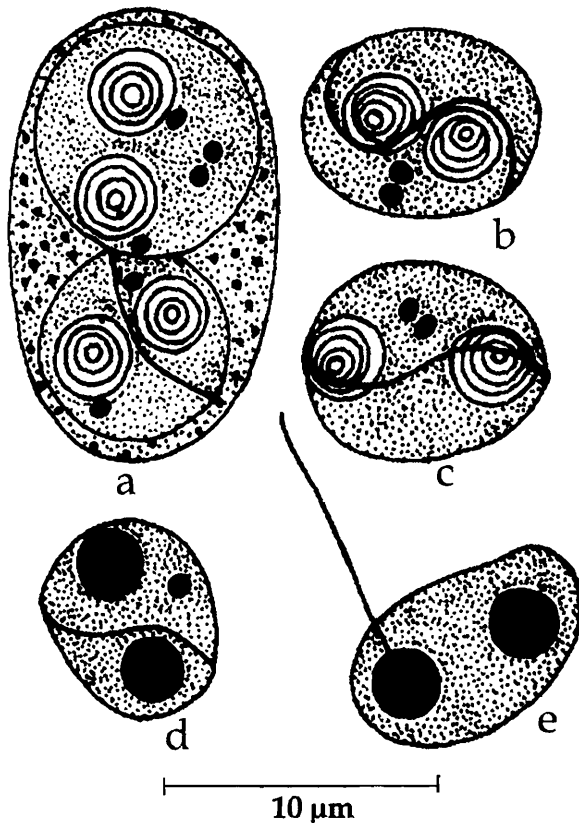


Fig. 31. *Zschokkella cascasiensis* : a. Disporous trophozoiete, b. Spore valvular view, c. Fresh spore sutural view, d. Spore treated with iodine, e. Spore with extruded polar filament

Diagnosis : Sporogonic plasmodia very small, oval to ellipsoidal, disporic, 20.0 μm x 16.0 μm ; spore spherical to ellipsoid with rounded ends rarely with acuminate ends; shell valves thin, smooth; sutural line thin, strongly 'S'-shaped; polar capsules equal, spherical; polar filament forming 3-4 coils while inside the capsule; sporoplasm uni or binucleate, granular, filling the extracapsular spore cavity; no mucous membrane; polar filament thick and extruded perpendicular to the axis of the spore.

Size : Spore length 8.0-10.5 (9.54) μm , width 6.5-8.0 (7.48) μm ; polar capsule 3.0-4.0 (3.36) μm in diameter.

Host : *Sicamugil cascasia* (Ham.); **site of infection** : gall bladder; **pathogenicity** : not apparent.

Distribution : India : West Bengal (24 Paraganas).

30. *Zschokkella channae* Sarkar, 2004
(Fig. 32 a-d)

Diagnosis : Sporogonic plasmodia spherical, disporic, 52 μm ; spores large, ellipsoidal with rounded ends; shell valve thin with 5-7 longitudinal striations; sutural line bent thick and oblique; polar capsules equal, spherical; sporoplasm located in between the polar capsules extending dorsally over the capsules.

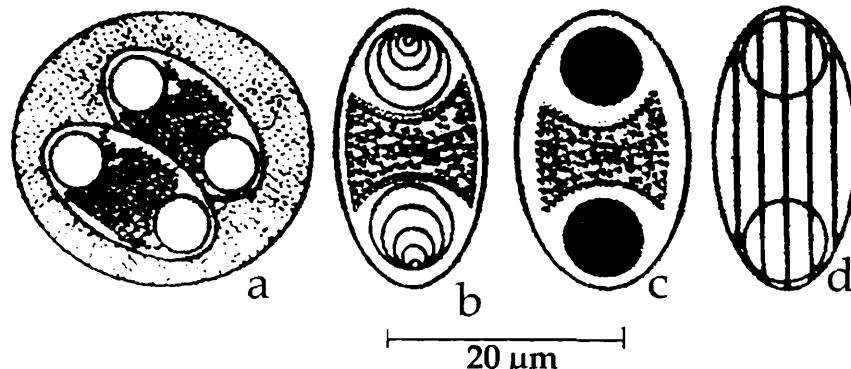


Fig. 32. *Zschokkella channae* : a. Disporous trophozoiete, b. Spore valvular view, c. Spore treated with iodine, d. Spore showing striations

Size : Spore length 16.5-18.7 (17.21) μm , width 8.5-11.05 (9.88) μm ; polar capsule 4.25-6.8 (5.54) μm in diameter.

Host : *Channa punctata* (Bloch); *site of infection* : kidney tubules; *pathogenicity* : not apparent.

Distribution : India : West Bengal (exact locality not mentioned).

31. *Zschokkella cirrhinae* Sarkar, 2004

(Fig. 33 a-d)

Diagnosis : Sporogonic plasmodia spherical, disporic, 12.0-15.0 μm ; spore rectangular to ellipsoidal, with flat to rounded ends; shell valve thin, smooth; sutural line ridged, 'S'-shaped; polar capsules equal, spherical; polar filament making 4-6 coils while inside the capsule; sporoplasm located in between the polar capsules extending dorsally over the capsules.

Size : Spore length 20.4-23.8 (21.66) μm , width 10.2-12.7 (11.51) μm ; polar capsule 4.25-7.65 (5.56) μm in diameter.

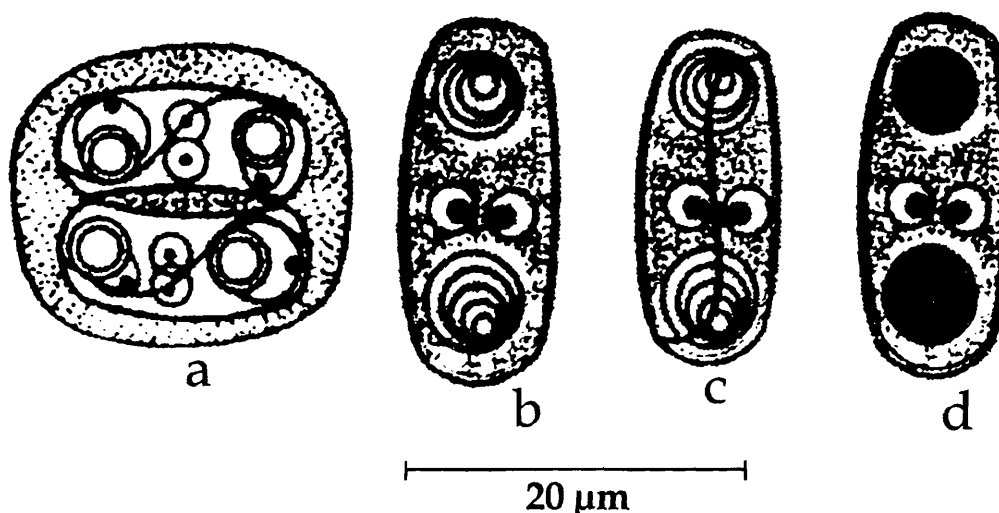


Fig. 33. *Zschokkella cirrhinae* : a. Disporous plasmodium, b. Spore valvular view, c. Spore sutural view, d. Spore treated with iodine

Host : *Cirrhinus reba* (Bloch); *site of infection* : gall bladder; *pathogenicity* : not apparent.

Distribution : India : West Bengal (exact locality not mentioned).

32. *Zschokkella fossilae* Chakravarty, 1943
(Fig. 34)

Diagnosis : Trophozoite disc-shaped, non-motile, 12.36-16.48 μm in longest diameter; spore more or less semicircular, shell valve thin with longitudinal striations; polar capsules equal, spherical; sporoplasm located in between the polar capsules extending dorsally over the capsules.

Size : Spore length 10.3 μm , width 4.12-5.18 μm ; polar capsule 3.1 μm in diameter.

Host : *Hilsa ilisha* (Ham.); **site of infection** : gall bladder; **pathogenicity** : not reported.

Distribution : India : West Bengal.

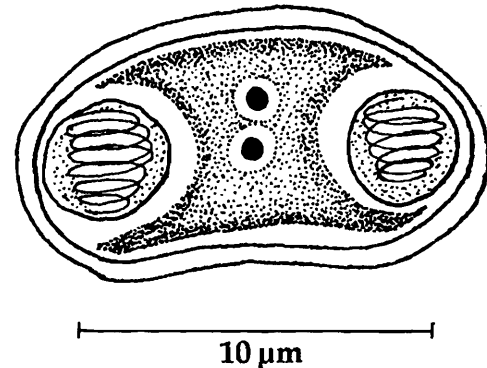


Fig. 34. *Zschokkella fossilae* : Spore valvular view

33. *Zschokkella ganapatii* Padma Dorothy and Kalavati, 1992 a
(Fig. 35 a-c)

Diagnosis : Pansporoblast disporous; spores oval; shell valves thick, refringent, transversely striated, 9-12 striations seen; sutural ridge 'S'-shaped; polar capsules spherical, one at either end, subterminal, capsular foramina diagonally opposite with thick cushion-like annuli; polar filament making 3-4 coils while inside the capsule, long and thin when fully extended; sporoplasm hyaline, lightly stained, intercapsular.

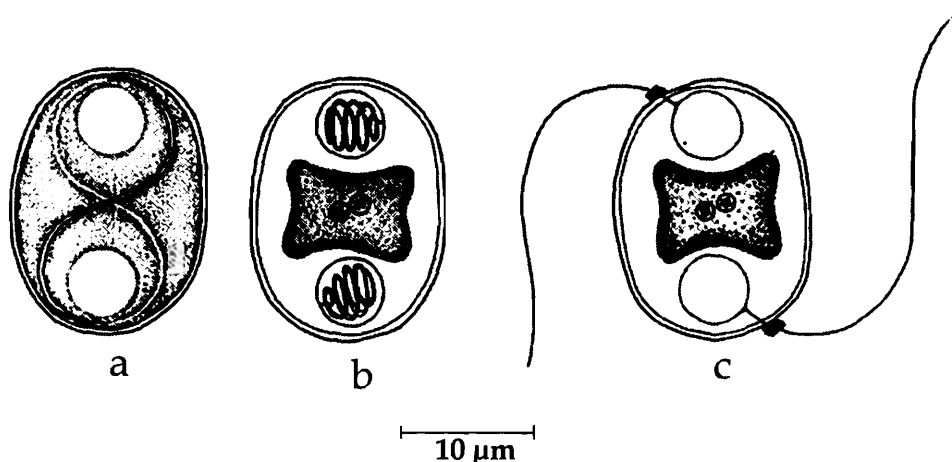


Fig. 35. *Zschokkella ganapatii* : a. Fresh spore valvular view, b. Spore stained with Giemsa, c. Spore with extruded polar filaments

Size : Spore length 11.18-15.48 (12.84) μm ; width 7.74 10.32 (9.81) μm ; polar capsule 2.58 4.3 (3.41) μm ; polar filament length 28.0-40.0 (34.1) μm .

Host : *Liza macrolepis*; **site of infection** : gall bladder; **pathogenicity** : not apparent.

Distribution : India : Andhra Pradesh (Gosthani estuary, Bay of Bengal, Bheemunipatnam and Visakhapatnam; Visakhapatnam district).

34. *Zschokkella glossogobi* Kalavati and Vaidehi, 1991b
(Fig. 36 a-d.)

Diagnosis : Pansporoblasts oval, disporoblastic, 11.2 -12.8 μm ; spores broadly oval in both valvular and sutural views with flat and truncate ends; valves smooth; sutural ridge 'S'-shaped; polar capsules spherical, one at either end, subterminal; polar filaments short and thick making only 2 coils while inside the capsule; sporoplasm diffuse, lightly stained, intercapsular.

Size : Spore length 9.6-11.4 (10.64) μm , width 6.4-8.0 (7.03) μm ; polar capsule 1.4-2.4 (1.78) μm in diameter; polar filament length 18.6-24.8 (21.26) μm .

Host : *Glossogobius giuris*; **site of infection** : gall bladder; **pathogenicity** : not apparent.

Distribution : India : Orissa (Chilka Lake, Ganjam district).

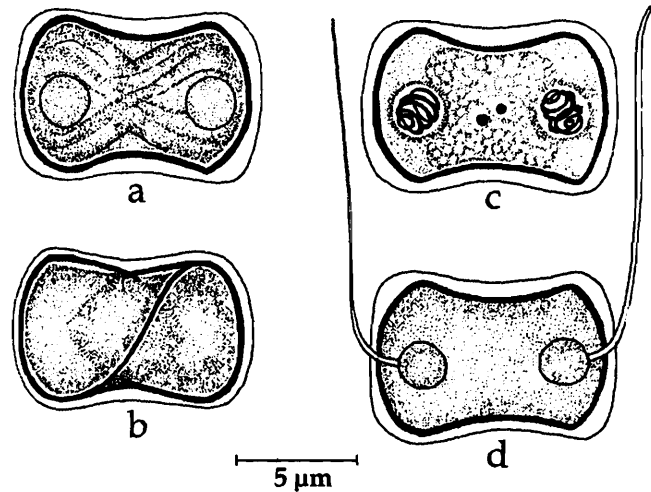


Fig. 36. *Zschokkella glossogobi* : a. Fresh spore valvular view, b. Sutural view, c. Spore stained with Giemsa, Spore with extruded polar filament

35. *Zschokkella gobiensis* Sarkar and Ghosh, 1991a
(Fig. 37 a-c)

Diagnosis : Spore ellipsoidal; valves smooth, thin, symmetrical; suture thick 'S'-shaped; polar capsule broadly ovoidal to spherical with short neck; polar filament forming 3-4 coils while inside the capsule; sporoplasm binucleate, granular, filling the intercapsular space; iodophilous vacuole absent.

Size : Spore length 10.0-13.5 (12.25) μm , width 6.0-9.0 (7.2) μm ; polar capsule 3.0-4.0 (3.35) μm in diameter.

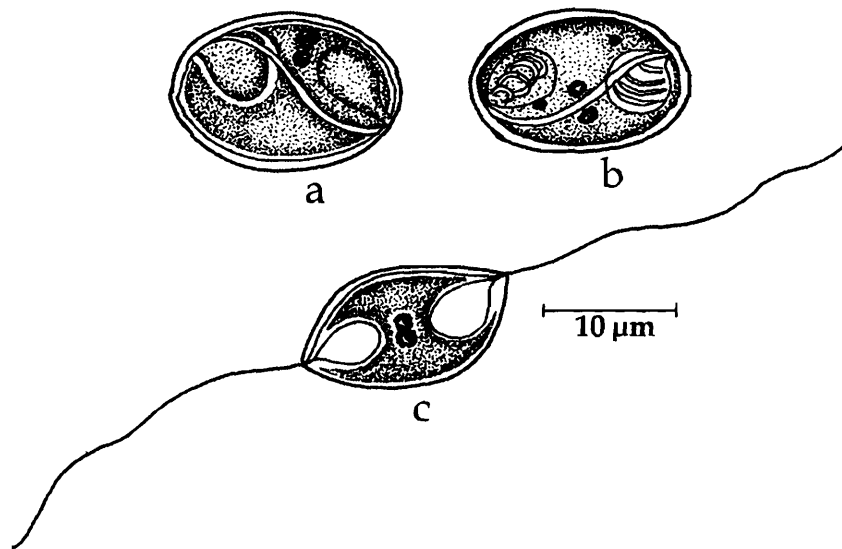


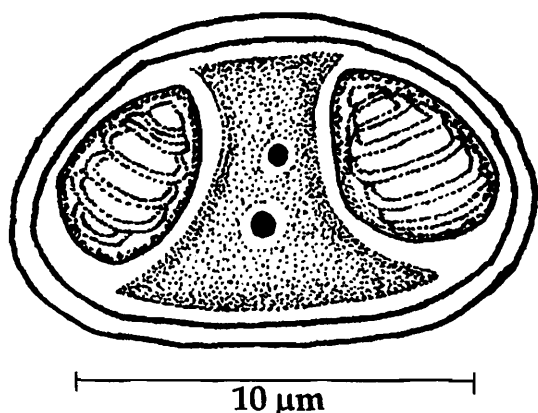
Fig. 37. *Zschokkella gobiensis* : a. Fresh spore valvular view, b. Spore stained with Giemsa, c. Spore with extruded polar filaments

Host : *Gobius giuris* Day; *site of infection* : gall bladder; *pathogenicity* : not reported.

Distribution : India : West Bengal (Chinsurah, Hugli district).

36. *Zschokkella illishae* Chakravarty, 1943
(Fig. 38)

Diagnosis : Trophozoite disc-shaped, 14.5-22.6 μm in diameter, nonmotile, disporous; spore more or less semicircular; shell valve thin with longitudinal striations; polar capsules equal, spherical; sporoplasm located in between the polar capsules but extending dorsally over the capsule.



Size : Spore length 12.36 μm ; width 6.18 μm ; polar capsule 4.26 μm in diameter.

Host : *Hilsa ilisha* (Ham.); *site of infection* : gall bladder; *pathogenicity* : not reported.

Distribution : India : West Bengal.

Fig. 38. *Zschokkella illishae* : spore

37. *Zschokkella labeonis* Lalitha Kumari, 1969
(Fig. 39 a-c)

Diagnosis : Spores hemispherical or gibbous in valvular view and ellipsoidal in sutural view; valves uniformly thick, asymmetrical with 10-12 striae curved and running parallel to sutural line converging at the poles; sutural line oblique, sinuous, elongated and 'S'-shaped in sutural view; polar capsules two, located one at each pole, spherical with short neck; polar filament forming 4-5 oblique coils while inside the capsule; sporoplasm finely granular forming a compact mass below the capsules.

Size : Spore length 9.3-12.9 (10.3) μm , width 4.3-7.1 (6.2) μm ; polar capsule length 2.9-4.3 (3.7) μm , width 2.1-3.6 (2.9) μm ; polar filament length 30-42 μm .

Host : *Labeo nigripinnis*; *site of infection* : gall bladder; *pathogenicity* : not reported.

Distribution : India : Andhra Pradesh (Hyderabad city).

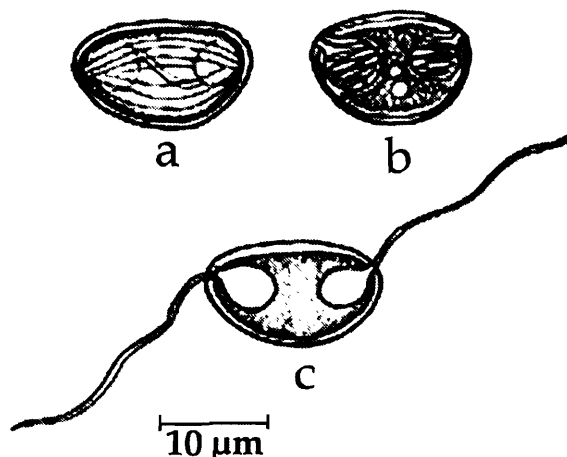


Fig. 39. *Zschokkella labeonis* : a. Fresh spore valvular view, b. Spore stained with Giemsa, c. Spore with extruded polar filaments

38. *Zschokkella ophicephali* Lalitha Kumari, 1969
(Fig. 40 a-b)

Diagnosis : Pansporoblasts monosporous; spores gibbous-shaped in valvular view and ellipsoidal in sutural view one side straight and the other curved, poles pointed; valves uniformly thick, asymmetrical with 10–12 striations; sutural line oblique, sinuous, elongated and 'S'-shaped in sutural view; polar capsules 2, located one at each pole, spherical with prominent neck; polar filament forming 6–7 coils while inside the capsule; sporoplasm finely granular, trapezoidal, forming a compact mass between the capsules.

Size : Spore length 12.9–14.3 μm , width 5.0–7.1 μm ; polar capsule length 3.6–3.9 μm , width 2.9–3.2 μm .

Host : *Channa* (= *Ophicephalus*) *striatus*; site of infection : gall bladder; pathogenicity : not reported.

Distribution : India : Andhra Pradesh (Hyderabad city; Srungavarapukota, Visakhapatnam district).

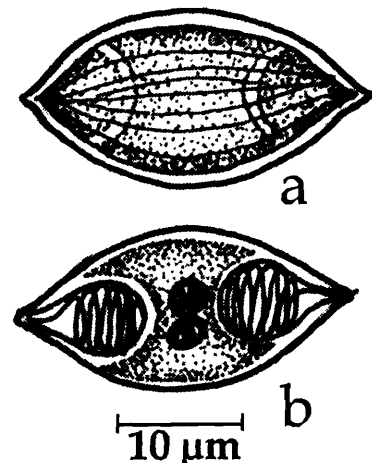


Fig. 40. *Zschokkella ophicephali* : a. Fresh spore valvular view, b. Spore stained with Giemsa

39. *Zschokkella platystomusi* Sarkar, 1986c
(Fig. 41 a-c)

Diagnosis : Spores ellipsoidal in valvular view with one edge highly convex and the other slightly concave, dumb-bell-shaped to nearly fusiform in sutural view; shell valves thin, hyaline and smooth; suture thin, not ridged and S-shaped; polar capsule two, spherical to ovoidal, polar filament uniformly thin when extruded; sporoplasm granular and filling the extracapsular cavity.

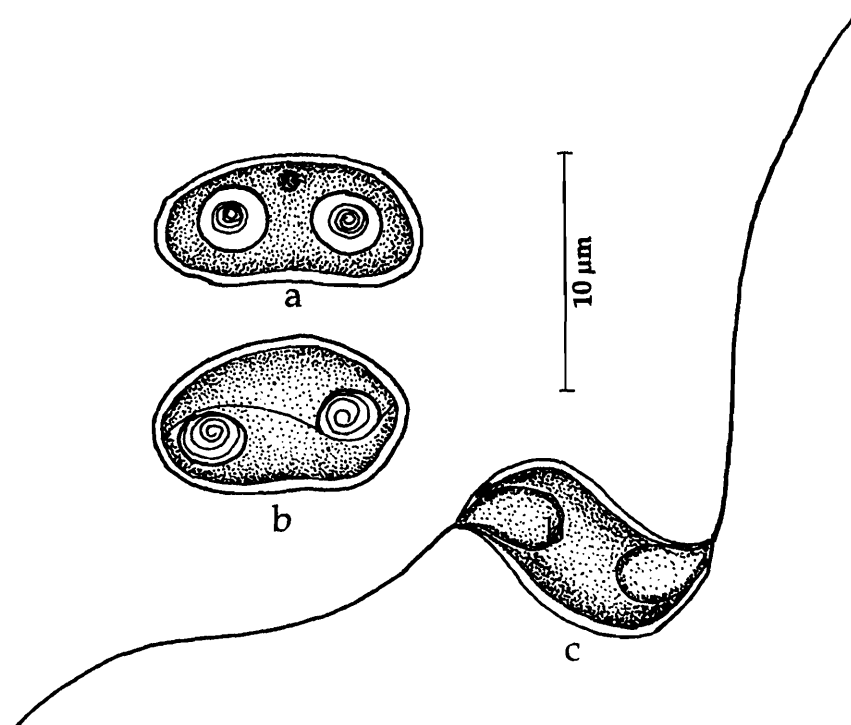


Fig. 41. *Zschokkella platystomusi* : a. Fresh spore valvular view, b. Sutural view, c. Spore with extruded polar filament

Size : Spore length 10.50-12.25 μm , width 6.50-7.35 μm ; polar capsule 2.8-3.5 μm in diameter; polar filament length 84.0 μm .

Host : *Tachysurus platystomus* (Day); *site of infection* : gall bladder; *pathogenicity* : not reported.

Distribution : India : West Bengal (Medinipur district).

40. *Zschokkella pseudosciaena* Sarkar, 1996a
(Fig. 42 a-d.)

Diagnosis : Coelozoic, trophozoite disporous; spore cylindrical to ellipsoidal, upper surface slightly arched, rarely flat, opposite surface concave; valves thin, smooth, symmetrical; suture elongated, 'S'-shaped, not ridged; polar capsules, equal, spherical, subterminal, open at opposite directions; polar filament forming 3-4 coils while inside the capsule; sporoplasm binucleate, finely granular filling the extracapsular space; iodophilous vacuole absent.

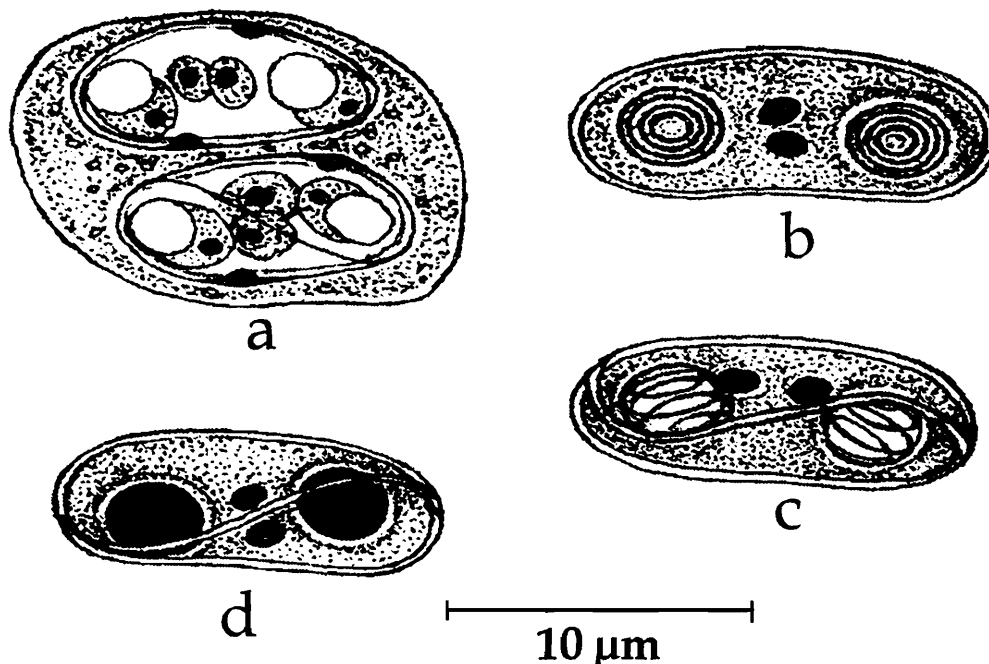


Fig. 42. *Zschokkella pseudosciaena* : a. Disporous trophozoite, b. Spore valvular view, c. Spore sutural view, d. Spore treated with iodine

Size : Spore length 9.5–13.0 (11.48) μm , width 5.0-7.0 (5.9) μm ; polar capsule 3.5–4.5 (3.58) μm in diameter.

Host : *Pseudosciaena coibor*; *site of infection* : kidney tubules and ureter; *pathogenicity* : not apparent.

Distribution : India : West Bengal (Hooghly estuary).

Genus *Coccomyxa* Leger and Hesse, 1907

Diagnosis : As in the key.

41. *Coccomyxa baleswarensis* Sarkar, 1995a
(Fig. 43 a-d)

Diagnosis : Coelozoic; plasmodia with several spores floating in bile; spore ellipsoid, anterior end broad and rounded, posterior end narrow; shell valves thin, smooth, symmetrical; suture thin, 'S'-shaped or sigmoid; single polar capsule, broadly pyriform, placed more or less obliquely at the anterior end, opening through fine orifice at the sutural plane; polar filament making 3-4 oblique turns while inside the capsule; sporoplasm finely granular, spherical, binuclate, filling the extracapsular spore cavity; no iodophilous vacuole.

Size : Spore length 10.0–13.0 (11.36) μm , spore width 4.5–6.0 (5.17) μm ; polar capsule length 4.0–6.0 (5.2) μm , width 2.0–3.0 (2.43) μm .

Host : *Hilsa ilisha* (Hamilton);
site of infection : gall bladder;
pathogenicity : not apparent.

Distribution : India : Orissa
(Baleswar coast, Bay of Bengal).

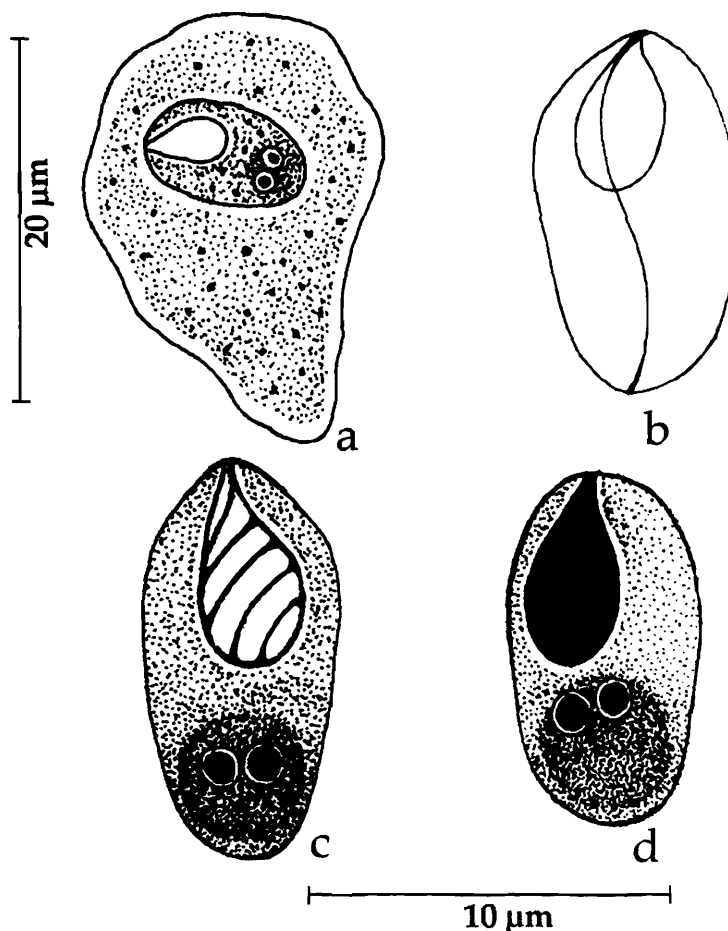


Fig. 43. *Coccomyxa baleswarensis* : a. Trophozoite with spore, b. Spore sutural view, c. Spore stained with Giemsa, d. Spore treated with iodine

Family ORTHOLINEIDAE Lom and Noble, 1984

Diagnosis : As in the key.

Genus *Ortholinea* Schulman, 1962

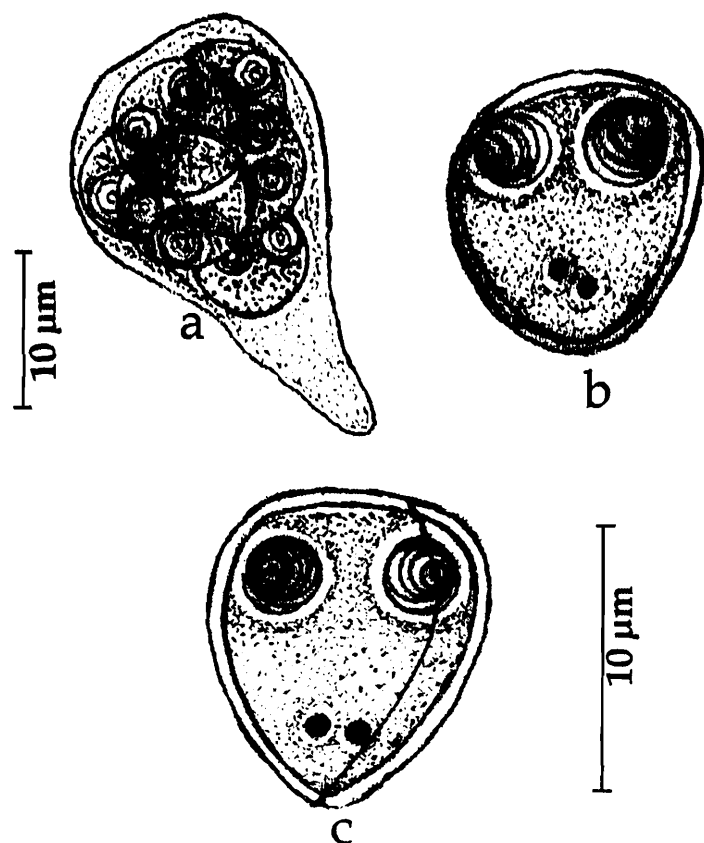
Diagnosis : As in the key.

Key to the species

1. Spores spherical or broadly triangular 3
2. Spores elongated, oval to egg-shaped; valves equal, smooth *O. indica*
- 3.1 Valves equal, striated; sutural line straight, prominent; polar capsules subspherical to pyriform *O. visakhapatnamensis*
- 3.2 Valves equal, smooth with an inconspicuous ridge *O. gadusiae*

42. *Ortholinea gadusiae* Sarkar, 1999a
(Fig. 44 a-c)

Diagnosis : Plasmodia free in the lumen of the urinary bladder, 24.0-57.5 x 14.0-37.5 (31.75 x 20.0) μm ; spores oval, spherical or triangular anterior end broad, flat, slightly convex, posterior end narrow, round; shell valves equal, smooth, with an



inconspicuous ridge, symmetrical; sutural line thin, bent but never sinuous; polar capsules spherical, widely placed at the broad end, appearing equal in valvular view and unequal in sutural view; polar filaments making 4-5 coils while inside the capsule; sporoplasm uni or binucleate, granular, occupying the entire spore cavity; no iodophilous vacuole.

Size : Spore length 9.0-11.7 (10.8) μm , width 9.0 - 9.9 (9.2) μm , thickness 7.2-9.0 (8.0) μm ; polar capsule 2.3-3.2 (3.0) μm in diameter, when oval length 1.8 -3.0 (2.8) μm , width 1.0-2.5 (2.0) μm .

Host : *Gadusia chapra*; **site of infection :** urinary bladder and kidney; **pathogenicity :** not apparent.

Distribution : India : West Bengal (Digha coast of Bay of Bengal).

Fig. 44. *Ortholinea gadusiae* : a. Polysporous trophozoite, b. Spore valvular view, c. Spore sutural view

43. *Ortholinea indica* Sarkar, 1999b
(Fig. 45 a-c)

Diagnosis : Spores elongated, oval to egg-shaped in both valvular and sutural views; valves equal, smooth, thin, symmetrical; sutural line thin, bent but not ridged; polar capsules spherical, widely placed, open laterally in opposite direction; polar filaments making 3-5 coils while inside the capsule, thin and uniform when extended; no iodophilous vacuole; sporoplasm hyaline non vacuolated, occupying the entire spore cavity.

Size : Spore length 6.5-9.0 (7.38) μm , width 5.5-8.0 (6.17) μm ; polar capsule 1.5-2.0 (1.72) μm in diameter.

Host : *Microspinosa cuja*; site of infection : urinary bladder and kidney; pathogenicity : not apparent.

Distribution : India : West Bengal (24 Parganas district).

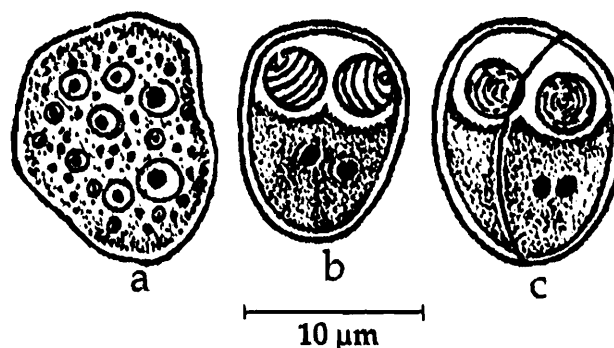


Fig. 45. *Ortholinea indica* : a. Developing plasmodium, b. Spore valvular view, c. Spore sutural view

44. *Ortholinea visakhapatnamensis* Padma Dorothy and Kalavati, 1993b
(Fig. 46 a-e)

Diagnosis : Cysts elongate or oval 0.7-1.3 mm x 0.5-0.9 mm; trophozoites disporous, spores spherical or broadly triangular with bluntly pointed posterior end; anterior end broad, corners round; shell valves equal, striated, 8 longitudinal striations; sutural line straight, prominent; polar capsules subspherical to pyriform, parallel on either side of sutural line; capsular foramina widely separated with a deeply stained thickening in between; polar filaments making 5-6 coils while inside the capsule, thin and uniform when extended; sporoplasm hyaline extending into intercapsular region and occupying the entire spore cavity; no iodophilous vacuole.

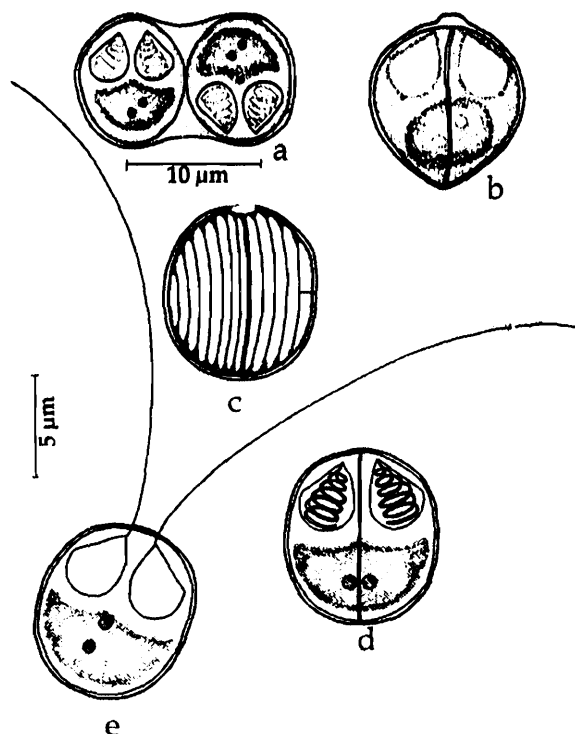


Fig. 46. *Ortholinea visakhapatnamensis* : a. Disporous trophozoite, b. Spore valvular view, c. Spore stained with Giemsa, d. Spore with extruded polar filaments

Size : Spore 5.16-6.0 (5.9) μm in diameter or 6.88 μm x 5.1 μm when triangular; polar capsule length 2.6-3.5 (3.0) μm , width 1.7-2.6 (2.2) μm ; polar filament length 17.6-24.0 (19.9) μm .

Host : *Liza macrolepis*; *site of infection* : visceral peritoneum; *pathogenicity* : not apparent.

Distribution : India : Andhra Pradesh (Visakhapatnam backwater region, Bay of Bengal, Visakhapatnam district).

Family SINUOLINEDAE Schulman, 1959

Diagnosis : As in the key.

Key to the genera

1. Spores spherical or subspherical 3
2. Spores inversely pyramidal 4
- 3.1 Spherical or subspherical spores, sutural line sinuous or extremely sinuous and its orientation to the two polar capsules set widely apart posing difficulty to determine; sporoplasm binucleate; trophozoites mono to polysporous; coelozoic in the urinary tract of marine fishes *Sinuolinea*
- 3.2 Spores spherical or sub-spherical; sutural line straight or sinuous; shell valves bearing hollow lateral appendages, the cavity showing discontinuity with spore cavity; polar capsules anterior, sub-terminal; coelozoic *Davisia*
- 4.1 Spores inversely pyramidal or triangular in sutural view with rounded corners, anterior end broad and flat; spore valves thick sometimes with various projections; sutural line straight or sinuous; polar capsules widely separated; sporoplasm binucleate; trophozoite mono or disporous *Myxoproteus*
- 4.2 Spores with stiff keel-like, meridianally running membranous valvular projections; sutural line running obliquely to the plane of two polar capsules; in urinary bladder of marine fishes *Paramyxoproteus*
- 4.3 Spores inversely pyramidal in sutural view, ellipsoidal in transverse side, ends pointed extending backwards; sutural line sinuous; anterior end of the shell valves drawn out into wing-like projections containing valvogenic nucleus; polar capsules spherical *Bipteria*
- 4.4 Spores inversely pyramidal with anterior wing-like projection of shell valves; in addition a 'keel'-like extension running meridionially along the sutural line; polar capsules spherical *Neobipteria*

Genus *Sinuolinea* Davis, 1917

Diagnosis : As in the key.

Key to the species

Spore slightly oval; shell valves thin, smooth; sutural line extremely thin, sinuous, coils round the spore, 10.83 μm x 10.3 μm in size; polar capsule spherical, widely spaced, divergent, 3.6 – 4.8 μm in diameter *S. andamani*

Spore spherical, 12.02 μm in diameter, thickwalled, nonappendiculate; suture slightly ridged, sutural line extremely sinuous, twisted on its axis; polar capsule spherical widely separated 3.45 μm in diameter. *S. indica*

45. *Sinuolinea andamani* Kalavati, Padma Dorothy and Paul Pandian, 2002
(Fig. 47 a-c)

Diagnosis : Trophozoite spherical, polysporous 30-35 μm in size, with 5-8 spores, pseudopodium absent; spore slightly oval; shell valves thin, smooth, nonappendiculate; sutural line extremely thin, sinuous, 'S'-shaped, coils round the spore; polar capsule spherical, widely spaced, divergent; polar filament forms 2 coils while inside the capsule; no intercapsular ridge; sporoplasm binucleate limited to the posterior part of the spore cavity.

Size : Spore length 9.6-12.8 (10.83) μm , width 8.0-12.8 (10.3) μm ; polar capsule 3.6 – 4.8 (3.73) μm in diameter.

Host : *Porogadus miles*; *site of infection* : gall bladder; *pathogenicity* : not reported.

Distribution : India : Andaman & Nicobar sea

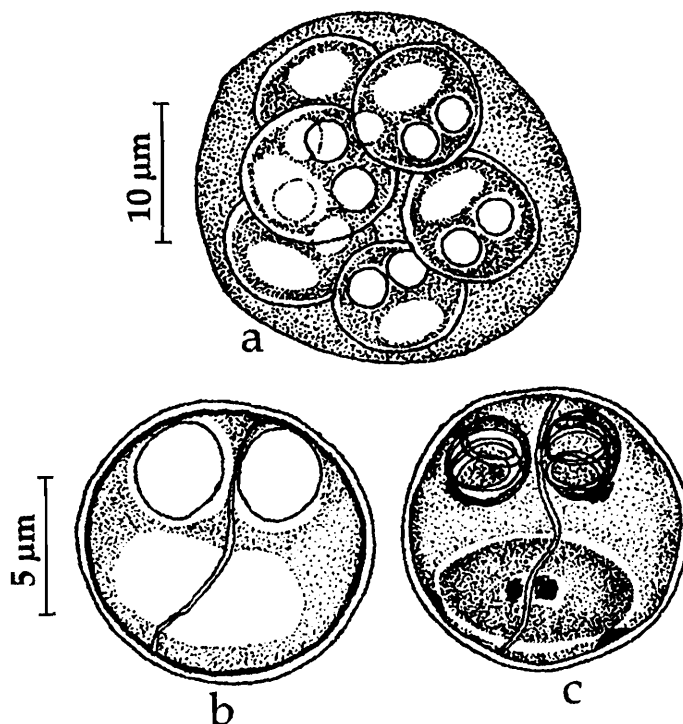
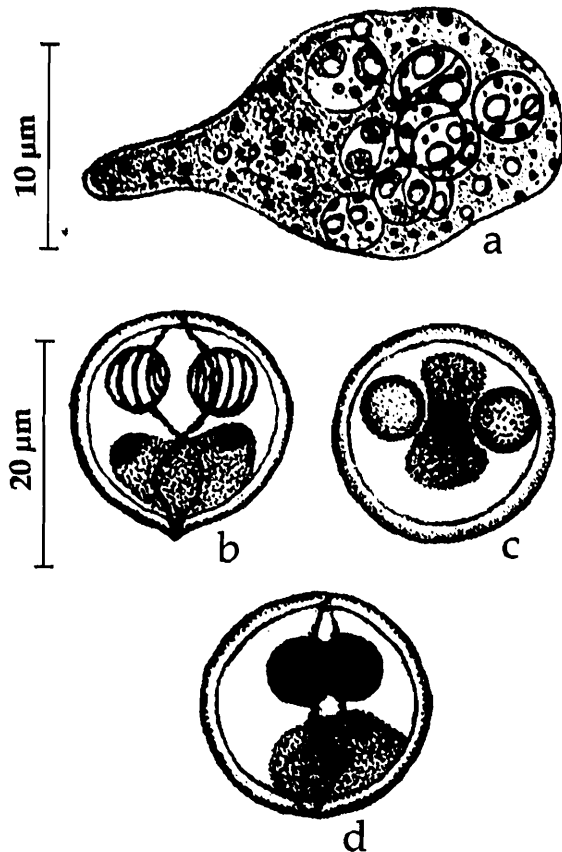


Fig. 47. *Sinuolinea andamani* : a. Polysporous trophozoite, b. Fresh spore (sutural view), c. Spore stained with Giemsa

46. *Sinuolinea indica* Sarkar, 1997

(Fig. 48 a-d)



Diagnosis : Trophozoite disporous, triangular or polysporous with lobose pseudopodium, 20.0-25.0 μm x 13.5-17.0 μm in size; spore spherical, thick-walled, nonappendiculate; suture slightly ridged; sutural line extremely sinuous, twisted on its axis; polar capsule spherical widely separated; polar filament making 4-5 coils while inside the capsule; sporoplasm binucleate limited to the posterior part of the spore cavity.

Size : Spore 10.0-13.5 (12.02) μm in diameter; polar capsule 3.0- 4.0 (3.45) μm in diameter.

Host : *Pseudosciaena coibor* (Ham.); **site of infection :** urinary bladder; **pathogenicity :** not apparent.

Distribution : India : West Bengal (Hooghly estuary).

Fig. 48. *Sinuolinea indica* : a. Polysporous trophozoite, b. Fresh spore (sutural view), c. Spore apical view, d. Spore stained with Giemsa

Genus *Davisia*, Laird, 1953

Diagnosis : As in the key.

Key to the species

1. Lateral appendages hollow 3
2. Lateral appendages solid 4
- 3.1 Spores flattened oval, lateral appendages equal with broad end, 32.2-42.2 (37.01) μm x 11.4-15.8 (12.6) μm *D. cynoglossi*
- 3.2 Spores crescent-shaped, spore body triangular or oval, lateral appendages equal 4.8-11.2 μm x 19.8-36.2 μm *D. murti*
- 3.3 Spores oval, lateral appendages unequal, filamentous, 120-176 μm x 13-14 μm ...
..... *D. filiformis*
4. Spore transversely elongated, slightly bent, spore body rectangular, lateral appendages oval, 17.4-28.0 μm x 7.24-10.8 μm *D. sauridae*

47. *Davisia cynoglossi* Narasimhamurti, Kalavati, Anuradha and Padma Dorothy, 1990
(Fig. 49 a-c)

Diagnosis : Spores flattened, bent with hollow lateral appendages having distinct junction to spore body; proximal portion of appendage broad, distal end narrow and oval; spore body oval; lateral appendages broad, valves thin, sutural line distinct, slightly wavy; polar capsules oval; polar filament thin; sporoplasm oval, granular, binucleate.

Size : Spore total width including appendages 32.2-42.2 (37.01) μm ; spore body length 12.6-16.8 (14.24) μm , width 11.4-15.8 (12.6) μm ; lateral appendage length 20.8-36.4 (28.5) μm , width 10.4-18.2 (14.5) μm ; polar capsule length 5.8-6.8 (6.2) μm , width 2.8-4.2 (3.4) μm ; polar filament length 22.4-28.6 (24.8) μm

Host : *Cynoglossus* sp.; **site of infection :** gall bladder; **pathogenicity :** not apparent.

Distribution : India : Andhra Pradesh (Off Masulipatnam, Krishna district, Bay of Bengal, Lat. 15°58' N Long. 81°31'E).

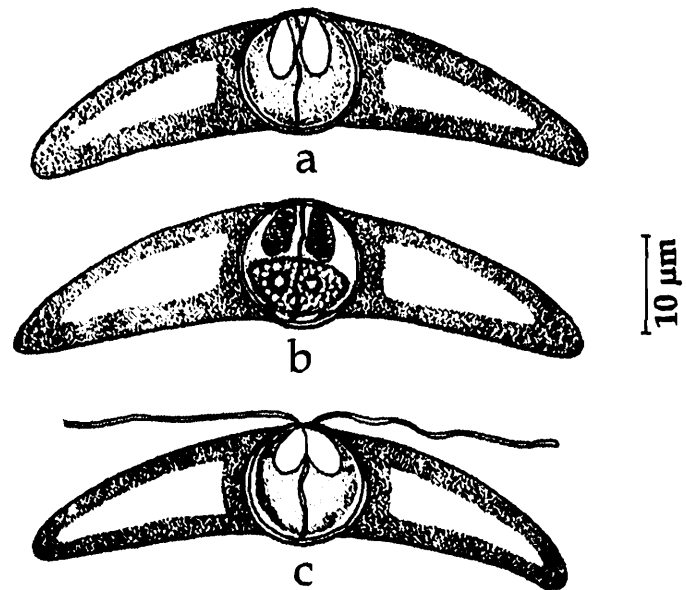


Fig. 49. *Davisia cynoglossi* : a. Fresh spore valvular view, b. Spore stained with Giemsa, c. Spore with extruded polar filament

48. *Davisia filiformis* Padma Dorothy, Kalavati and Vaidehi, 1998
(Fig. 50 a-b)

Diagnosis : Pansporoblast disporous; spore body oval with distinct joints of lateral appendages demarcated by a deeply stained cushion-like structure; lateral appendages hollow, unequal, long, filamentous in fresh spores; valves thin, smooth; sutural line thin,

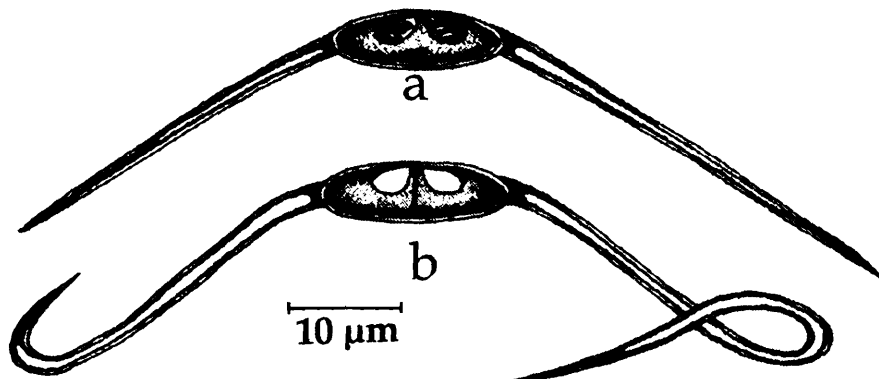


Fig. 50. *Davisia filiformis* : a. Fresh spore valvular view, b. Spore stained with Giemsa

straight; polar capsule pyriform; polar filament forming 2 to 3 coils while inside the capsule; sporoplasm hyaline, binucleate, filling the entire spore cavity.

Size : Spore total width including appendages 120.0-176.0 (152.7) μm ; spore body length 12.0-14.0 (12.3) μm , width 16.0-20.0 (19.73) μm ; polar capsule length 8.0 - 10.0 (8.73) μm , width 6.0- 8.0 (7.7) μm .

Host : *Thrissocles setirostris*; *site of infection* : gall bladder; *pathogenicity* : not apparent.

Distribution : India : Andhra Pradesh (Bay of Bengal, off Visakhapatnam).

49. *Davisia murtii* Padma Dorothy and Kalavati, 1994
(Fig. 51 a-c)

Diagnosis : Trophozoites small, round or oval, disporous; spore crescent-shaped with a triangular or oval spore body, valves smooth, lateral appendages hollow, equal, distal end blunt; sutural line wavy; polar capsules spherical, overlapping; polar filaments making 4-5 coils while inside the capsule, thin and uniform when extended.

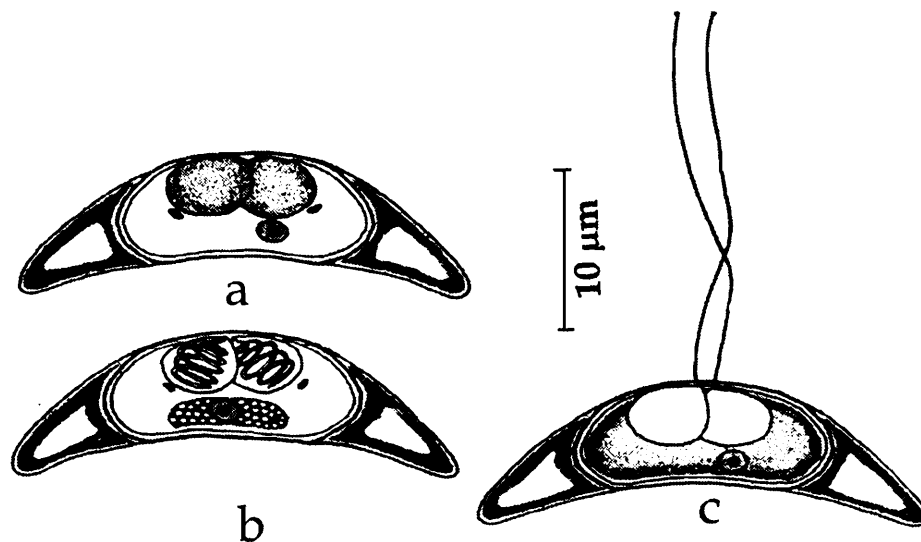


Fig. 51. *Davisia murtii* : a. Fresh spore valvular view, b. Spore stained with Giemsa, c. Spore with extruded polar filament

Size : Spore length 11.2-17.6 (13.86) μm , width 4.8-11.2 (7.31) μm ; lateral appendage 4.2-9.6 (6.6) μm ; polar capsule 3.2-4.8 (4.56) μm in diameter; polar filament length 15-30 μm .

Host : *Liza macrolepis*; *site of infection* : gall bladder; *pathogenicity* : hypertrophy and discolouration of the gall bladder; sinusoidal dilatation associated with enlargement of hepatic ducts and accumulation of mononuclear leucocytes and also aggregation of bile salts.

Distribution : India : Andhra Pradesh (Off Bheemunipatnam, Bay of Bengal, Visakhapatnam district).

50. *Davisia sauridae* Narasimhamurti, Kalavati, Anuradha and Padma Dorothy, 1990
(Fig. 52 a-b)

Diagnosis : Trophozoite di or polysporous; spore tranversely elongated, slightly bent; spore body rectangular, broad, width almost twice the body length, anterior end broader than posterior; sutural ridge sinuous, distinct; lateral appendages oval and solid and forming distinct junction to spore body marked like a furrow; polar capsules oval, very small, one on either side of the sutural ridge; polar filament making 2-3 coils while inside the capsule; thick and deeply stained when extruded; sporoplasm oval, granular, binucleate; no iodophilous vacuole.

Size : Spore total width including appendages 17.4 -28.0 (22.65) μm ; spore body length 7.24-10.8 (9.6) μm , width 14.8-22.6 (18.2) μm ; lateral appendage length 2.6-5.4 (3.52) μm ; polar capsule length 3.2-1.6 (1.8) μm , width 2.4-1.2(1.6) μm ; polar filament length 12.0-29.8 (22.65) μm .

Host : *Saurida tumbil*; **site of infection :** gall bladder; **pathogenicity :** not apparent.

Distribution : India : Orissa (Off Paradip, Bay of Bengal, Lat. 18°41' N Long. 84°58'E).

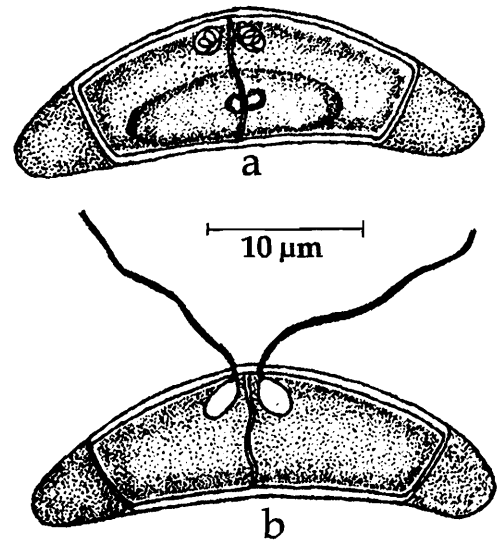


Fig. 52. *Davisia sauridae* : a. Fresh spore valvular view, b. Spore with extruded polar filament

Genus *Myxoproteus* Doflein, 1898

Diagnosis : As in the key.

51. *Myxoproteus cujaeus* Sarkar, 1996
(Fig. 53 a-c)

Diagnosis : Spore inversely pyramidal or triangular in valvular view, anterior end flat, posterior narrow, rounded; shell valves smooth, non-appendiculate; sutural line moderately thick weakly sinuous and slightly bent; polar capsule spherical, equal, placed wide apart at flat end; sporoplasm binucleate, oval filling the entire extracapsular spore cavity.

Size : Spore length 9.0-12.0 (10.45) μm , width 8.0 -10.0 (9.16) μm ; polar capsule 3.0-4.0 (3.27) μm in diameter.

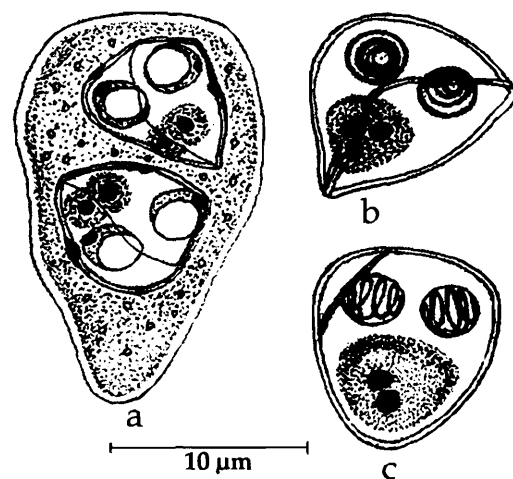


Fig. 53. *Myxoproteus cujaeus* : a. Disporous trophozoite, b. Spore sutural view, c. Spore valvular view

Host : *Macrospinosa cuja*; *site of infection* : urinary bladder; *pathogenicity* : not apparent.

Distribution : India : West Bengal (Hooghly estuary).

Genus *Paramyxoproteus* Wierzbicka, 1986

Diagnosis : As in the key.

52. *Paramyxoproteus chlorophthalmusi* Kalavati,
Padma Dorothy and Paul Pandian, 2002
(Fig. 54a-c)

Diagnosis : Trophozoite large, disporous, 45.0–58.0 μm , two spores in juxtaposition; spore inversely pyramidal or triangular in valvular view, rhomboidal in sutural view, anterior end flat, posterior tapering, spore valves thin, smooth with meridionally running stiff lateral extensions; sutural line oblique, distinct, running diagonal to the long axis of the spore; polar capsule large, oval, widely separated, lying in the plane marked by sutural line; polar filament making 3-4 coils while inside the capsule; sporoplasm binucleate in the posterior half of the spore cavity.

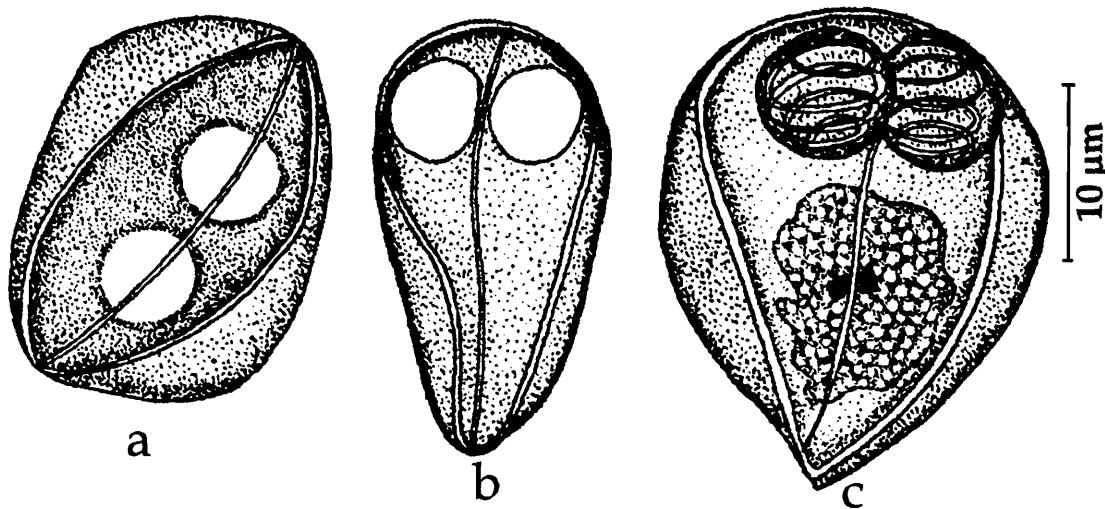


Fig. 54. *Paramyxoproteus chlorophthalmusi* : a. Spore sutural view, b. Spore valvular view, c. Spore stained with Giemsa

Size : Spore length 24.0–32.0 (27.2) μm ; width 18.6–26.4 (21.4) μm ; polar capsule 4.8–6.4 (5.2) μm in diameter.

Host : *Chlorophthalmus punctatus*; *site of infection* : gall bladder; *pathogenicity* : not apparent.

Distribution : India : Andaman & Nicobar sea.

Genus *Bipteria* Kovaleva, Zubchenco and Krasin 1983

Diagnosis : As in the key.

53. *Bipteria indica* Kalavati and Anuradha, 1995
(Fig. 55 a-c)

Diagnosis : Pansporoblast disporous.; spores inversely pyramidal, anterior end broad, corners rounded, posterior end narrow, blunt; two delicate wing-like appendages arise from the anterior region of spore and extend almost up to posterior end enclosing the spore body; shell valves thin, smooth, refractive; sutural line curved at posterior end; polar capsules spherical widely spaced; polar filament forming 5-6 coils while inside the capsule, long and thin when extended; sporoplasm homogenous, hyaline occupying the entire extra capsular cavity, iodophilous vacuole absent.

Size : Spore length 5.6-6.8 (5.8) μm , width 5.4-6.8 (5.7), thickness 4.8-5.2 (5.0) μm ; polar capsule 1.8-2.6 (2.0) μm in diameter; polar filament length 16.0-20.0 (18.0) μm .

Host : *Mugil cephalus* and *Liza macrolepis*; *site of infection* : gall bladder; *pathogenicity* : not apparent.

Distribution : India : Andhra Pradesh (Off Bheemunipatnam, Visakhapatnam, Bay of Bengal, Visakhapatnam district), Orissa (Chilka Lake).

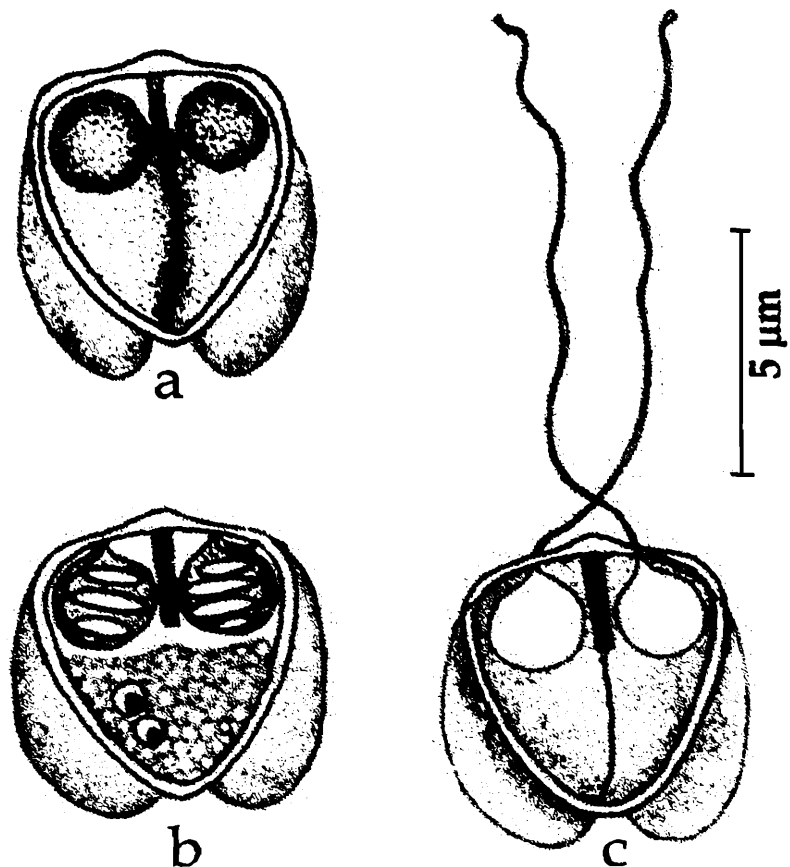


Fig. 55. *Bipteria indica* : a. Fresh spore valvular view, b. Spore stained with Giemsa, c. Spore with extruded polar filament

Genus *Neobipteria* Kovaleva, Zubchenco and Krasin, 1983

Diagnosis : As in the key.

54. *Neobipteria coramandelensis* Narasimhaurti, Kalavati, Anuradha and Padma Dorothy, 1990
(Fig. 56 a-b)

Diagnosis : Spore triangular, posterior end pointed, anterior flattened with a small depression at the center; sutural line thick, straight; a pair of median, keel-like membranes arising from the sutural line; shell valves smooth, symmetrical, with 2 ring-like appendages at the center; polar capsules spherical; polar filament forming 6-7 coils while inside the capsule; sporoplasm homogenous, oval, binucleate; no iodophilous vacuole.

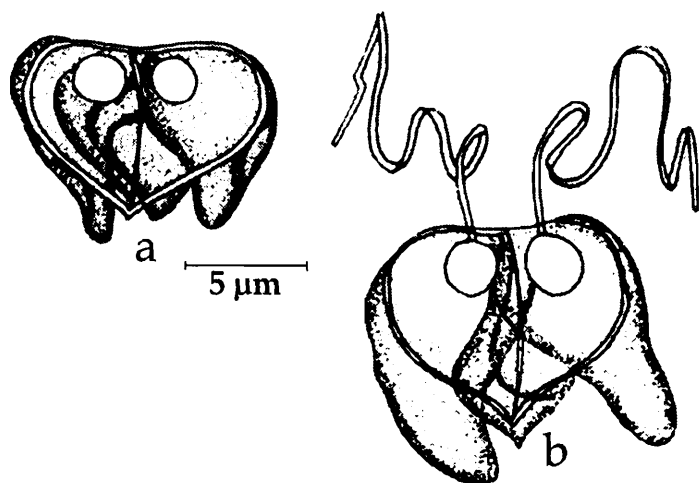


Fig. 56. *Neobipteria coramandelensis* : a. Fresh spore valvular view, b. spore with extruded polar filament

Size : Spore length 4.8-6.8 (5.9) μm , width 7.2-10.4 (8.76) μm ; polar capsule 2.6-3.4 (3.18) μm in diameter; polar filament length 36.8-52.6 (43.75) μm .

Host : *Nemipterus mesoprion*; *site of infection* : gall bladder; *pathogenicity* : not reported.

Distribution : India : Andhra Pradesh (Off Masulipatnam, Lat. 15°58' N Long. 81°31'E, Bay of Bengal, Krishna district).

Family CERATOMYXIDAE Doflein, 1899

Diagnosis : As in the key.

Key to the genera

1. Spores oval, ellipsoidal, arcuate or elongated in the direction perpendicular to sutural plane; length of individual shell valve not exceeding the axial diameter of spore but significantly more than one half of the diameter; capsular foramina near sutural plane; sporoplasm mostly one, binucleate, sometimes 2 uninucleate sporoplasms seen..... *Leptotheca*
2. Spores elongated, crescent-shaped or arcuate; shell valves conical always exceeding the axial diameter of the spore in length; polar capsules sub-spherical, equal or unequal. Sporoplasm binucleate, not completely filling the spore cavity *Ceratomyxa*

Genus *Leptotheca* Thelohan, 1895

Diagnosis : As in the key.

Key to the species

- 1. Spore valves smooth..... 3
- 2. Spore valves striated..... 4
- 3.1 Spore bean – shaped with both extremities rounded; shell valves symmetrical; sporoplasm not occupying entire extracapsular cavity of the spore *L. lateri*
- 3.2. Spore elliptical, shell valves unequal, sporolasm occupying entire extracapsular cavity*L. macronesi*
- 4.1. Spores hemispherical or trapezoidal; shell valves usually thick, transvesly striated; two uninucleate sporoplasms.....*L. apogoni*
- 4.2. Spores elliptical or oval; shell valves usually thick characteristically ornamented with three longitudinal striae converging towards the sutural ridge*L. assymetrica*

55. *Leptotheca apogoni* Narasimhamurti, Kalavati, Anuradha and Padma Dorothy, 1990 (Fig. 57a-c)

Diagnosis : Pansporoblast disporous; spores hemispherical or trapezoidal, anterior end broad, flat, posterior bluntly rounded, breadth being more than sutural diameter; shell valves usually thick, transvesly striated; sutural ridge prominent clearly visible near the posterior end; polar capsules equal, spherical, one on either side of the sutural ridge, opening independently; polar filaments coiled watch-spring-like when inside the capsule; two uninucleate sporoplasms; polar filament thick, short.

Size : Spore length 16.8–18.2 (17.56) µm, width 24.6–26.2 (25.4) µm; polar capsule 2.4–4.2 (3.8) µm in diameter; polar filament length 22.0–28.0 (24.82) µm.

Host : *Apogon aureus*; *site of infection* : gills, gall bladder and intestine; *pathogenicity* : gall bladder hardened and discoloured; no apparent changes in gills or intestine.

Distribution : India : Orissa (Bay of Bengal, off Paradeep).

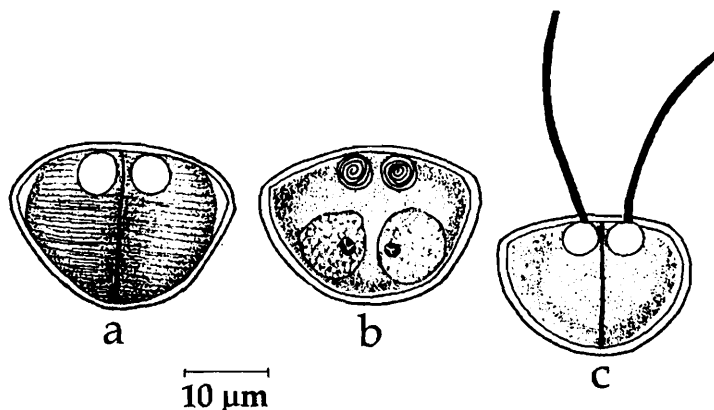


Fig. 57. *Leptotheca apogoni* : a. Fresh spore valvular view, b. Spore stained with Giemsa, c. Spore with extruded polar filament

56. *Leptotheca assymetrica* Lalitha Kumari, 1969

(Fig. 58a-c)

Diagnosis : Spores elliptical or oval, breadth being more than sutural diameter, ends rounded; shell valves usually thick characteristically ornamented with a horizontal transverse striation and three longitudinal striae converging towards the sutural ridge; polar capsules unequal, pyriform, opening independently; polar filaments unequal; sporoplasm clear, finely granular, forming a compact mass and occupying little space behind the large polar capsule.

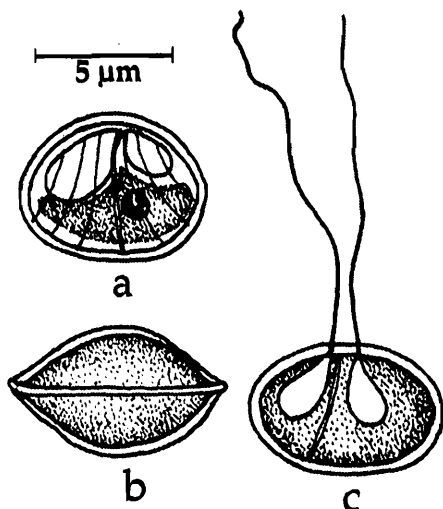


Fig. 58. *Leptotheca assymetrica* :
a. Spore valvular view, b. Spore sutural view, c. Spore with extruded polar filament

Size : Spore length 5.7–7.9 (6.8) μm , width 8.6–10.0 (9.4) μm ; polar capsule (large) length 4.3–5.4 (4.9) μm , width 2.9–4.3 (3.1) μm ; polar capsule (small) length 3.6–4.3 (4.0) μm , width 2.1–2.9 (2.8) μm ; polar filament (long) length 32–41 (37.7) μm ; polar filament (short) length 27–32 (29.8) μm .

Host : *Osteochilus neilli*; **site of infection :** gills, gall bladder and intestine; **pathogenicity :** not apparent.

Distribution : India : Andhra Pradesh (Hyderabad city).

57. *Leptotheca latesi* Chakravarty, 1943

(Fig. 59a-b)

Diagnosis : Trophozoites circular 10–14 μm in diameter, disporous; spore bean-shaped in lateral view with both extremities rounded; shell valves smooth and symmetrical; sutural line prominent, sutural diameter 6.2 μm , sutural ridge absent; polar capsules spherical, equal, one on either side of the sutural ridge; polar filament thin and long; sporoplasm not filling the entire extracapsular cavity.

Size : Spore width 10.3–12.4 μm ; polar capsule 3.1 μm in diameter; polar filament length 50–80 μm .

Host : *Lates calcarifer* (Bloch); **site of infection :** gall bladder; **pathogenicity :** not apparent.

Distribution : India : West Bengal (exact locality not mentioned).

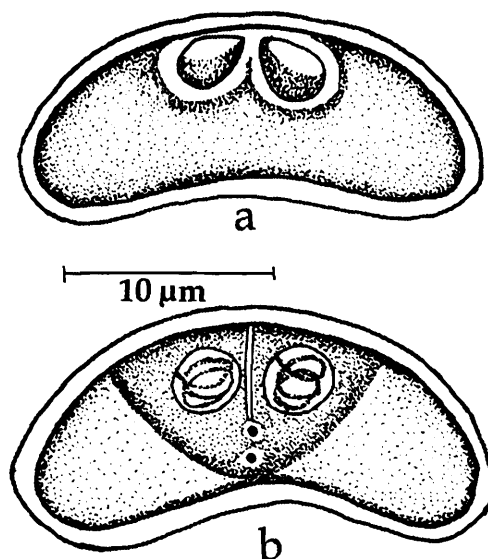


Fig. 59. *Leptotheca latesi* : a. Fresh spore valvular view, b. Spore stained with Giemsa

58. *Leptotheca macronesi* Chakravarty, 1943
(Fig. 60a-b)

Diagnosis : Trophozoties circular, 10.3 μm in diameter, monosporous; spore elliptical with ventral side more or less flattened, extremities rounded; shell valves smooth, unequal and thin; sutural line distinct; polar capsules equal, spherical, one on each side of sutural line; sporoplasm filling the entire extracapsular cavity.

Size : Spore breadth 10-14.4 μm , sutural diameter 6.18-7.2 μm ; polar capsule 3.1 μm in diameter.

Host : *Macrones gilio* (Ham.); site of infection; gall bladder; pathogenicity : not apparent.

Distribution : India; West Bengal (exact locality not mentioned).

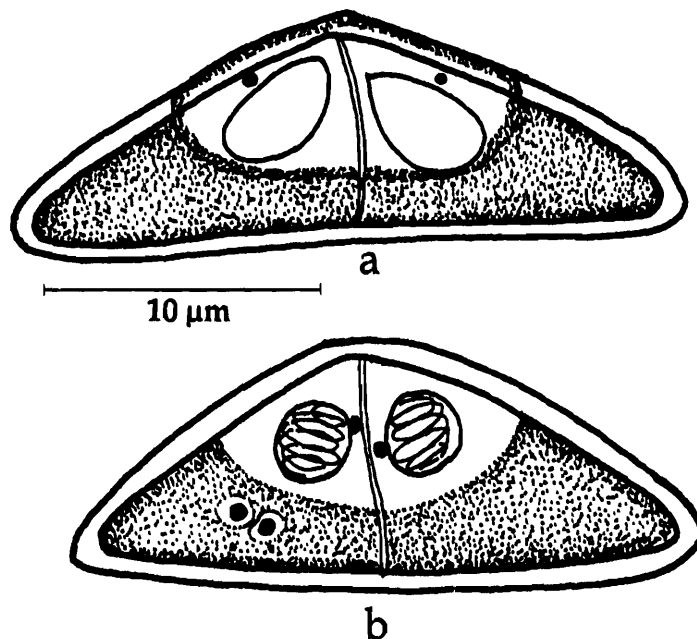


Fig. 60. *Leptotheca macronesi* : a. Fresh spore valvular view, b. Spore stained with Giemsa

Genus *Ceratomyxa* Thelohan, 1892

Diagnosis : As in the key.

Key to the species

1. Spores transversely elongated, shell valves unequal 3
2. Spores transversely elongated, shell valves equal 4
- 3.1 Spores arcuate, asymmetrical, 9.2-11.8 (10.36) μm x 36.4-45.8 (41.6) μm ; valves smooth, unequal; polar capsules spherical, unequal *C. dissimilaris*
- 3.2 Spore hemispherical in sutural view; shell valve with 2-5 hollow appendages; sutural diameter of spore 14-19 μm *C. tartoori*
- 3.3 Spores arched; polar capsules equal round to pyriform *C. etroplusi*
- 3.4 Spores elongated extending laterally, polar capsules equal *C. nengae*
- 3.5 Spore crescent-shaped, polar capsules equal, nearly spherical *C. cyanoglossi*

- 4.1 Spore flat, compressed, 2.75-4.0 (3.7) μm x 12.9-19.8 (16.7) μm ; shell valves smooth; polar capsules large, subspherical *C. kudo*
- 4.2 Spores transversely elongated, 8.6-10.32 (9.53) μm x 81.7-98.7 (88.58) μm ; valves thick, smooth, drawn out laterally with pointed ends; polar capsules oval *C. thrissoclesi*
- 4.3 Spores hat-shaped, 14.2-18.4 (16.2) μm x 68.6-82.4 (74.2) μm ; valves smooth; polar capsule spherical *C. sagarsampadae*
- 4.4 Spore arcuate or crescent-shaped
- 4.4.1 Shell valves with lateral prolongation, breadth of the spore about 9 times the length or sutural diameter *C. sagarica*
- 4.4.2 Shell valves with blunt terminal end; polar capsule spherical, equal 4-5 μm x 14-15 μm *C. gobioidesi*
- 4.4.3 Shell valves with rounded extremities; polar capsule spherical; 4.2-7.2 μm x 16-20 μm *C. scatophagi*
- 4.4.4 Shell valves very long laterally drawn out, downwardly directed, greatly compressed parallel to sutural line *C. dasysciaenae*
- 4.5 Spore elliptical; polar capsules equal; sporoplasm not filling entirely extracapsular cavity *C. hilsae*
- 4.6 Spore more or less rod-shaped, polar capsules pyriform, equal *C. priacanthi*
- 4.7 Spore elongated; valves extending laterally to form cones; polar capsules pyriform *C. tenulosae*

59. *Ceratomyxa cyanoglossi* Das, Pal and Ghosh 1988b

(Fig. 61a-b)

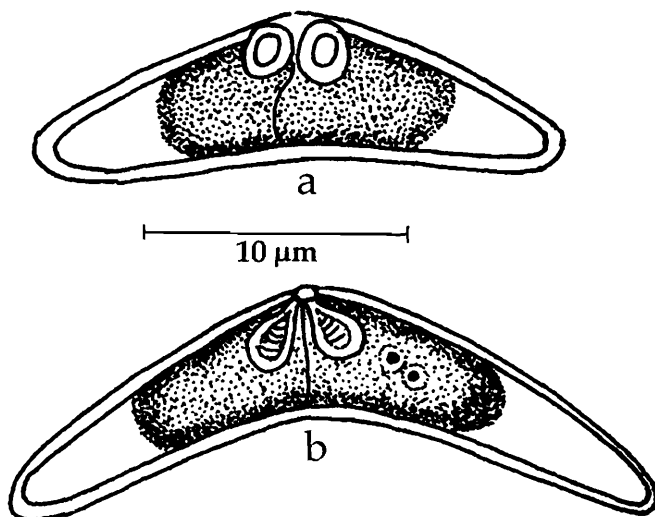


Fig. 61. *Ceratomyxa cyanoglossi* : a. Fresh spore valvular view, b. Spore stained with Giemsa

Diagnosis : Fully grown trophozoites colourless, transparent, irregular to round in shape, 42.5 μm x 20.0 μm ; spores crescent-shaped; shell valves cylindrical, assymetrical gradually tapering towards the end; polar capsules large, approximately spherical, opening close together; polar filament coils distinct; sporoplasm binucleate, finely granular, situated in the central part of the spore.

Size : Spore length 8.5-9.5 (9.07) μm , width 47.0-58.0 (53.95) μm ; polar capsule length 4.5-5.0 (4.9) μm , width 4.0 μm ; polar filament length 20.0-27.0 (24.0) μm .

Host : *Cyanoglossus lingua* (Cuv.); *site of infection* : gall bladder; *pathogenicity* : not apparent.

Distribution : India : West Bengal : (Jumbo island, Kakdweep, South 24-Parganas district).

60. *Ceratomyxa daysciaenae* Sarkar and Pramanik 1994a
(Fig. 62a-d)

Diagnosis : Fully grown trophozoites large ellipsoidal with one end more pointed than the other, 80.2 μm x 25.65 μm ; spores strongly arcuate to crescent-like, with broad ellipsoid valves; shell valves very long, laterally drawn out, downwardly directed, smooth, equal, thin, greatly compressed parallel to sutural axis and gradually tapering to a point; sutural line very thin, slightly sinuous; polar capsules usually equal, small, spherical, subterminal, convergent; polar filament coils inside the capsule insufficiently distinct; sporoplasm finely granular filling the spore cavity.

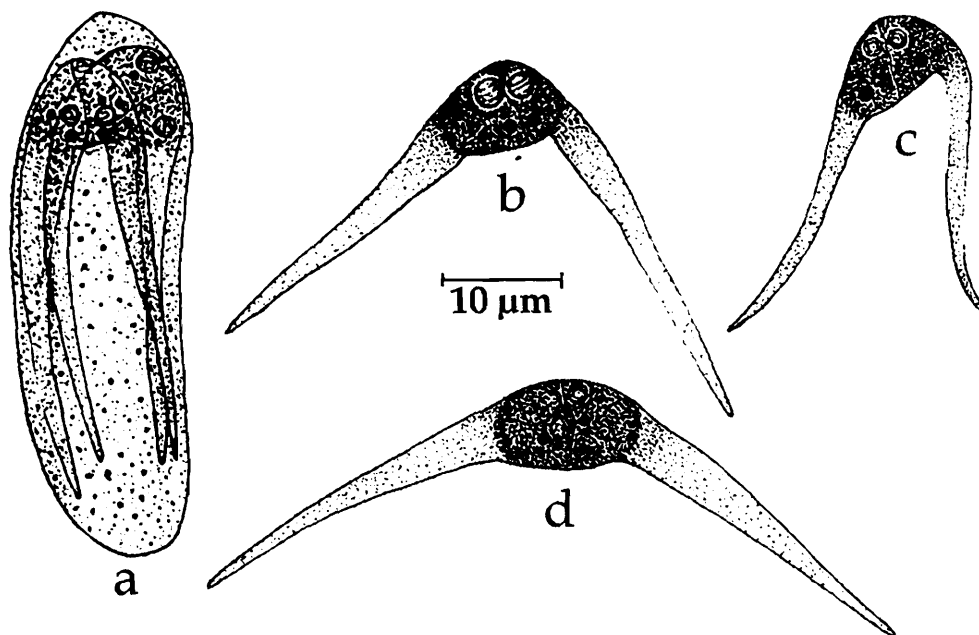


Fig. 62. *Ceratomyxa daysciaenae* : a. Disporous trophozoite, b-d. Spores different views

Size : Spore length 5.5-7.0 (6.04) μm , width 55.0-75.0 (65.13) μm ; polar capsule diameter 1.8-3.0 (2.14) μm .

Host : *Daysciaena albida* (Cuv); *site of infection* : gall bladder; *pathogenicity* : not apparent.

Distribution : India : West Bengal (Hooghly estuary near Kakdweep).

61. *Ceratomyxa dissimilaris* Narasimhamurti, Kalavati, Anuradha and Padma Dorothy, 1990
(Fig. 63a-b)

Diagnosis : Pansporblast disporous; spores arcuate, asymmetrical, transversely elongated with slightly bent oval ends; shell valves smooth, unequal; sutural line straight; polar capsules spherical, unequal; polar filaments forming 3-4 coils while inside the capsule; sporoplasm irregular with numerous eosinophilic granules, extending into lateral arms, usually displaced towards larger valve.

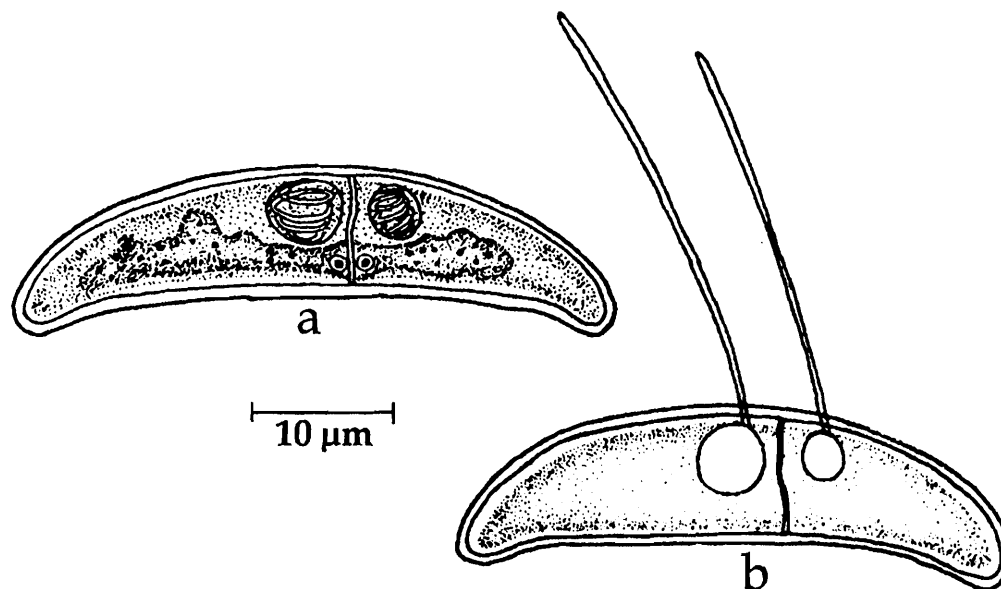


Fig. 63. *Ceratomyxa dissimilaris* : a. Spore stained with Giemsa, c. Spore with extruded polar filament

Size : Spore length 9.2-11.8 (10.36) µm, width 36.4-45.8 (41.6) µm; spore valve (large) 17.6-22.4 (19.2) µm; spore valve (small) 20.8-26.8 (22.4) µm; polar capsule (large) 3.0-5.2 (4.82) in diameter; polar capsule (small) 2.4-3.8 (3.56) µm in diameter; polar filament (short) length 24.4-32.2 (28.6) µm; polar filament (long) length 34.8-38.4 (36.2) µm.

Host : *Nemipterus mesoprion*; *site of infection* : gall bladder; *pathogenicity* : not reported.

Distribution India : Andhra Pradesh (Off Kalingapatnam, Bay of Bengal, Srikakulam district).

62. *Ceratomyxa etroplusi* Rajendran and Janardanan, 1992
(Fig. 64a-c)

Diagnosis : Trophozoites coelozoic, variable in shape, 3.0-53.25 µm x 3.0-18.0 µm (15.52 µm x 7.29) µm, with one to several, slender and tapering filiform pseudopodia; spores arched in sutural view, straight in capsular view; shell valves thin, unequal;

sutural line faintly marked; polar capsules round to pyriform, equal; sporoplasm finely granular with refractile bodies extending into lateral arms.

Size : Spore length 4.5-6.0 (4.97) μm , width 12.38-18.0 (15.41) μm ; polar capsule length 1.5-2.63 (1.95) μm , polar capsule width 1.88-3.0 (2.66) μm .

Host : *Etroplus maculatus*; *site of infection* : gall bladder; *pathogenicity* : not reported.

Distribution India : Kerala (Rivulets of Iringal and Ramanttukara, Calicut district).

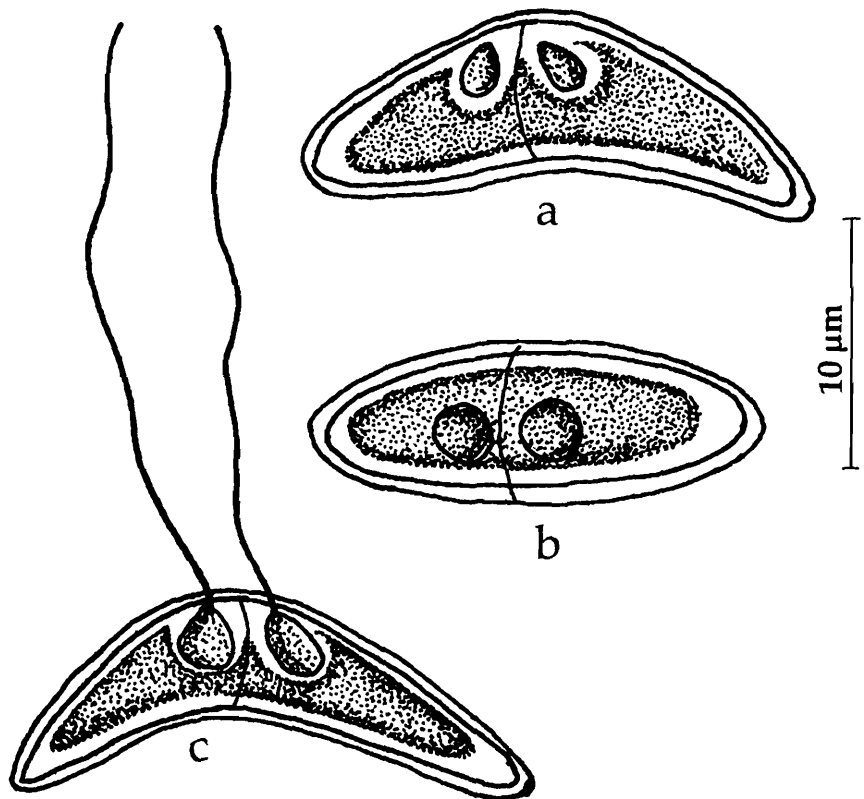


Fig. 64. *Ceratomyxa etropusi* : a. spore valvular view, b. spore sutural view, c. spore with extruded polar filament

63. *Ceratomyxa gobioidesi* Chakravarty, 1939
(Fig. 65a-c)

Diagnosis : Trophozoite circular or disc-shaped, 500-650 μm in diameter, disporous; spore crescent-shaped; shell valve symmetrical with blunt terminal end; sutural plane distinct; polar capsules spherical, equal, one on each side of the sutural line; polar filament short; sporoplasm granular, filling the extracapsular cavity.

Size : Spore breadth 14.0-15.0 μm , sutural diameter 4.0-5.0 μm ; polar capsule 2.5-3.0 μm in diameter; polar filament length 15.0 μm .

Host : *Odontoamblypus (Gobioides) rubicundus* (Ham); *site of infection* : gall bladder; *pathogenicity* : not reported.

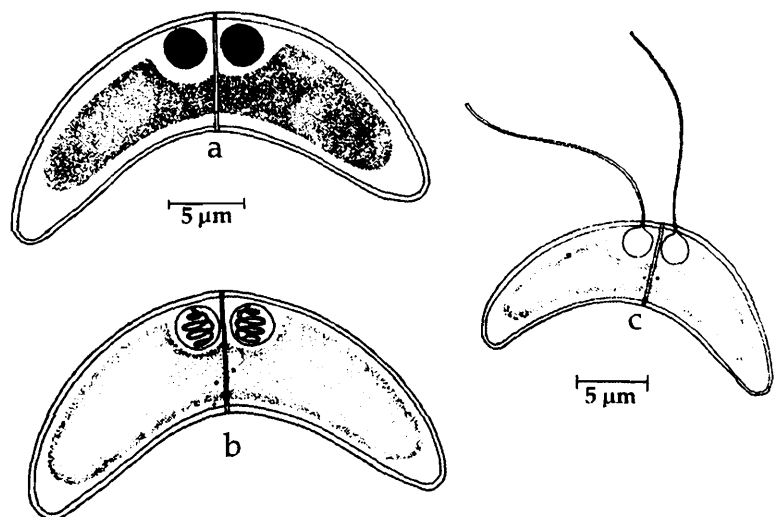


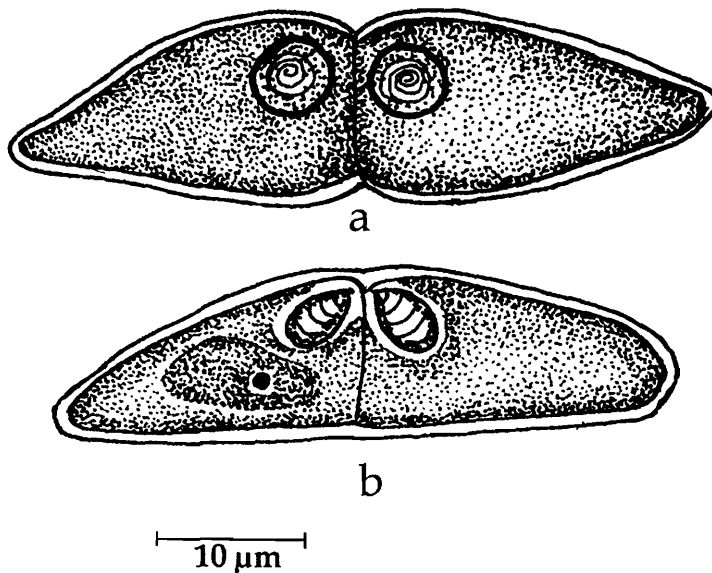
Fig. 65. *Ceratomyxa gobioidesi* : a. Spore treated with iodine, b. Spore stained with Giemsa, c. Spore with extruded polar filament

Distribution : India : West Bengal (Calcutta district.), Kerala (Neendakara).

Remarks : Krishnakumar (2000) described this species from Kerala infecting *Monomitopus nigripinis*.

64. *Ceratomyxa hilsae* Chakravarty, 1939
(Fig. 66a-b)

Diagnosis : Trophozoite spherical and usually disporous; spore elliptical in front view, anteriorly arched in lateral view, posteriorly almost straight; shell valves tapering



with rounded or blunt extremities; sutural plane prominent, polar capsules spherical equal in size; polar filament thin, long; sporoplasm asymmetrically placed and not filling the entire extracapsular cavity.

Size : Spore breadth 25.0-40.0 μm ; sutural diameter 10 μm ; polar capsule 5.0 μm in diameter; polar filament length 35-40 μm .

Host : *Hilsa ilisha* (Ham); *site of infection* : gall bladder; *pathogenicity* : not reported.

Distribution : India : West Bengal (Calcutta district).

Fig. 66. *Ceratomyxa hilsae* : a. Fresh spore valvular view, b. Spore stained with Giemsa

65. *Ceratomyxa kudoi* Kalavati and Anuradha, 1993
(Fig. 67a-c)

Diagnosis : Pansporoblasts disporous, oblong with filiform pseudopodia at either end; spores transversely elongated, compressed, flat, and ribbon-like with rounded lateral ends; anterior end pointed, posterior with small indent line; length : width ratio 1 : 5.0-5.6; shell valves smooth and equal; sutural line distinct and straight; polar capsules large, subspherical, terminal; polar filament forming 4-5 coils while inside the capsule; sporoplasm granular extending into valves; each valve with a characteristic hollow (vacuole?), iodophilous vacuole absent.

Size : Spore length 2.75-4.0 (3.7) μm , width 12.9-19.8 (16.7) μm , polar capsule 1.5-2.5 (2.0) μm ; polar filament length 10.0-15.5 (13.2) μm .

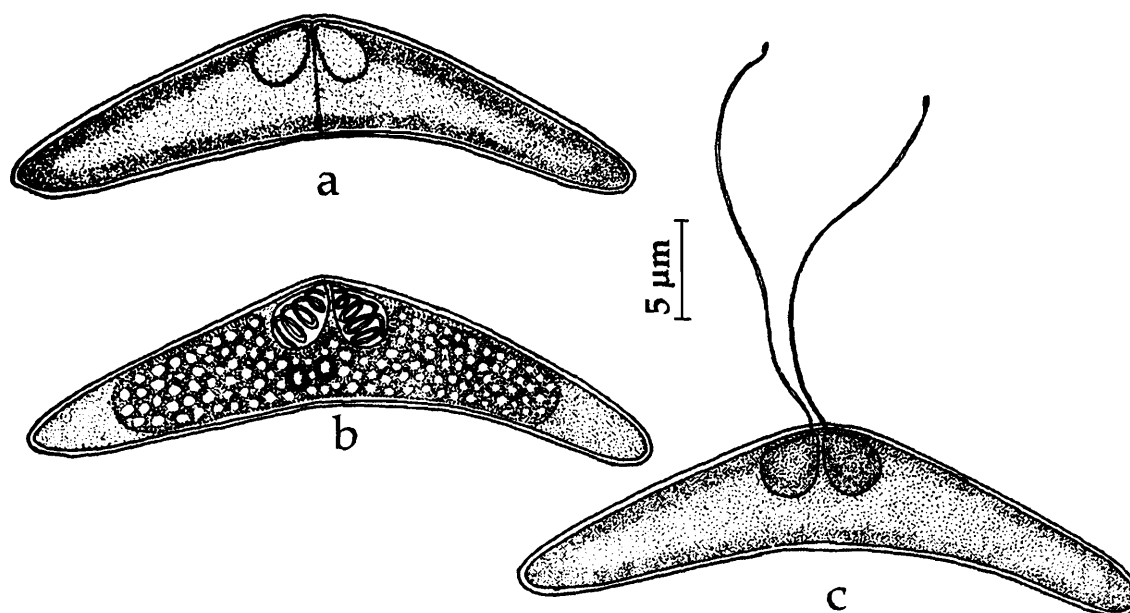


Fig. 67. *Ceratomyxa kudoi* : a. Fresh spore valvular view, b. Spore stained with Giemsa, c. Spore with extruded polar filament

Host : *Valamugil cunnesius*; *site of infection* : gall bladder; *pathogenicity* : not apparent.

Distribution : India : Andhra Pradesh (Gosthani estuary and Visakhapatnam harbour, Visakhapatnam district).

66. *Ceratomyxa nengae* Sarkar 2004
(Fig. 68a-c)

Diagnosis : Spores elongated extending laterally; shell valves asymmetrical, unequal, smooth broadly rounded or with clavate ends; sutural line slightly bent, thin; polar capsules equal, pyriform, convergent; polar filament forming 4-5 coils while inside the capsule, coiling perpendicular to the long axis of the capsule; sporoplasm finely granular filling the spore cavity.

Size : Spore length 6.8-10.2 (8.98) μm , width 33.15-42.5 (38.6) μm ; polar capsule diameter 5.0-6.8 (5.82) μm .

Host : *Tachysurus nenga*; *site of infection* : gall bladder; *pathogenicity* : not apparent.

Distribution : India : West Bengal (Bay of Bengal, Digha coast).

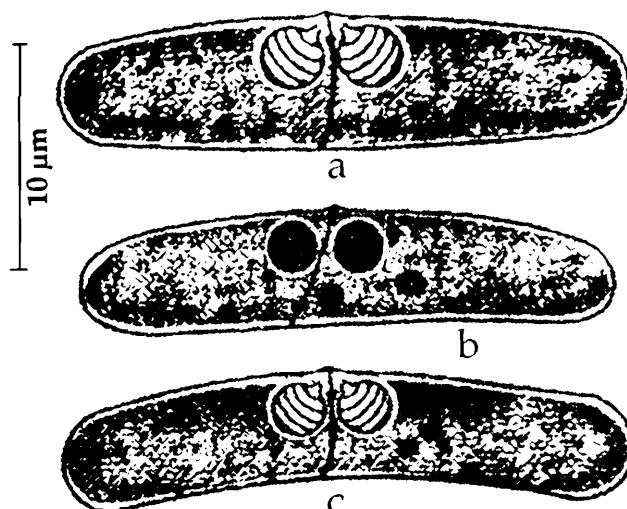


Fig. 68. *Ceratomyxa nengae* : a. Fresh spore, b. Spore treated with iodine, c. Spore stained with Giemsa

67. *Ceratomyxa priacanthi* Kalavati, Padma Dorothy and Paul Pandian, 2002
(Fig. 69a-c)

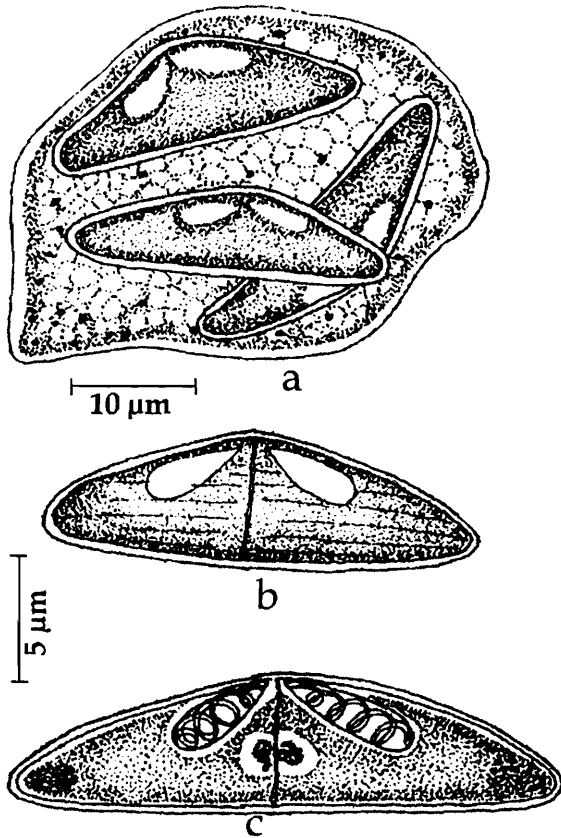


Fig. 69. *Ceratomyxa priacanthi* : a. Polysporous trophozoite, b. Fresh spore valvular view, c. Spore stained with Giemsa

Diagnosis : Trophozoites coelozoic di or trisporous, irregular, transparent, 38.4 -54.6 μm x 25.6 -30.8 μm ; spores characteristically flat, rigid, more or less rod-like, length : width ratio 1 : 3.0-4.0; shell valves symmetrical, finely striated with lobose ends; sutural line thick and straight; polar capsules equal, pyriform, parallel to the spore body; polar filament forming 3-4 coils while inside the capsule; sporoplasm granular extending into valves; iodophilous vacuole absent.

Size : Spore length 5.4-8.0 (5.8) μm , width 15.6-28.8 (17.64) μm ; polar capsule length 4.8-6.4 (5.2) μm , polar capsule width 1.8 - 3.2 (2.8) μm ; polar filament length 10.0-15.5 (13.2) μm .

Host : *Priacanthus hamrur*; **site of infection** : gall bladder; **pathogenicity** : not apparent.

Distribution : India : Andman sea.

68. *Ceratomyxa sagarica* Choudhury and Nandi, 1973
(Fig. 70a-d)

Diagnosis : Spore crescentic to arched with two lateral prolongations ending almost in needle point; breadth of spore about nine times the length of sutural diameter; shell valve thin and asymmetrical; sutural ridge vertically curved; polar capsule pyriform, unequal, one on each side of sutural plane; sporoplasm not filling the entire extracapsular cavity.

Size : Spore length 3.3-4.1 (3.55) μm , width 26.5-36.3 (17.64) μm ; polar capsule length 4.8-6.4 (5.2) μm , width 1.8-3.2 (2.8) μm ; polar filament length 10.0-15.5 (13.2) μm .

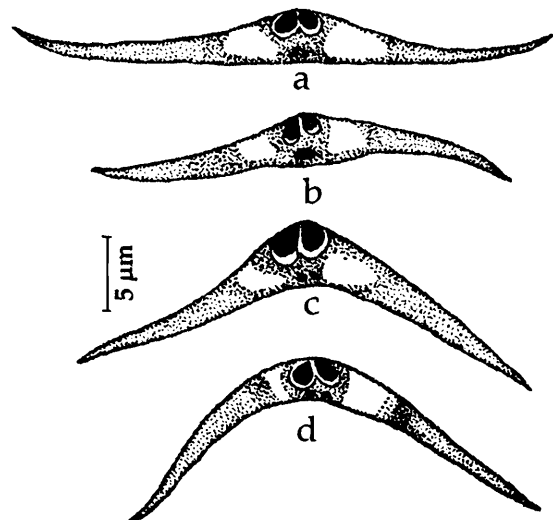


Fig. 70. *Ceratomyxa sagarica* : a-d. Spores in different views showing variations

Host : *Boloepthalmus boddaerti* Palbs; *site of infection* : gall bladder; *pathogenicity* : not apparent.

Distribution : India : West Bengal (South 24 - Parganas district).

69. *Ceratomyxa sagarsampadae* Narasimhamurti, Kalavati, Anuradha and Padma Dorothy, 1990
(Fig. 71a-b)

Diagnosis : Pansporblast disporous; spores transversely elongated and hat-shaped, shell valves thick, smooth; sutural line wavy; polar capsules equal, spherical, sub terminal; polar filaments forming 6-7 coils while inside the capsule, long and fine when extended; both the filaments extruded through a common foramen forming a cross at the point of extrusion; sporoplasm hyaline, extending below the capsules in the entire spore cavity; no iodophilous vacuole.

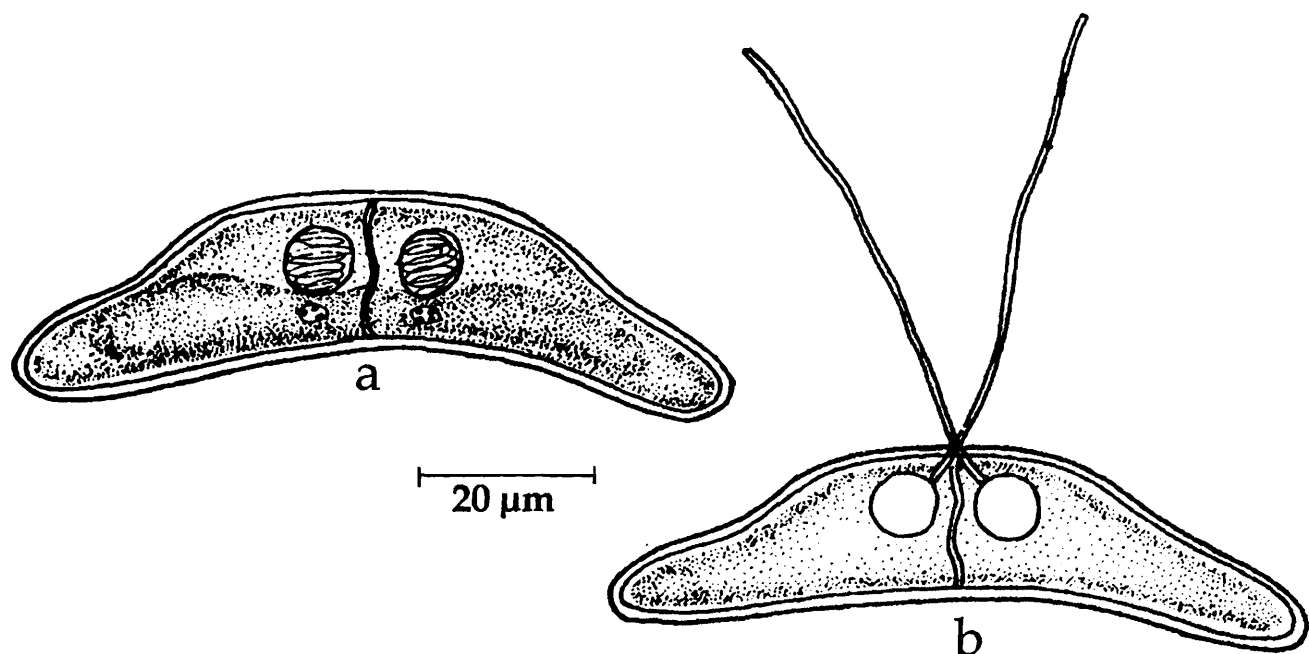


Fig. 71. *Ceratomyxa sagarsampadae* : a. Spore stained with Giemsa, b. Spore with extruded polar filament

Size : Spore sutural diameter 14.2-18.4 (16.2) μm , breadth 68.6-82.4 (74.2) μm ; polar capsule (spherical) 8.4-9.86 (8.52) μm in diameter; polar filament length 48.0-68.4 (59.76) μm .

Host : *Cynoglossus* sp; *site of infection* : gall bladder; *pathogenicity* : not apparent.

Distribution : India : Andhra Pradesh (Off Masulipatnam, Bay of Bengal, Lat. 15°58' N Long. 81°31'E, Krishna district).

70. *Ceratomyxa scatophagi* Chakravarty, 1943
(Fig. 72)

Diagnosis : Trophozoite irregular in shape measuring 50-120 μm x 40-85 μm ; spore crescent-shaped in lateral view; shell valves alike, cylindrical with round terminal extremities; sutural line indistinct; polar capsules equal, spherical.

Size : Spore, sutural diameter 4.2-7.2 μm , breadth 16-26 μm ; polar capsule 2.5-3.1 μm in diameter; polar filament length 30-50 μm .

Host : *Scatophagus argus* (Bloch); *site of infection* : gall bladder; *pathogenicity* : not apparent.

Distribution : India; West Bengal (exact locality not mentioned).

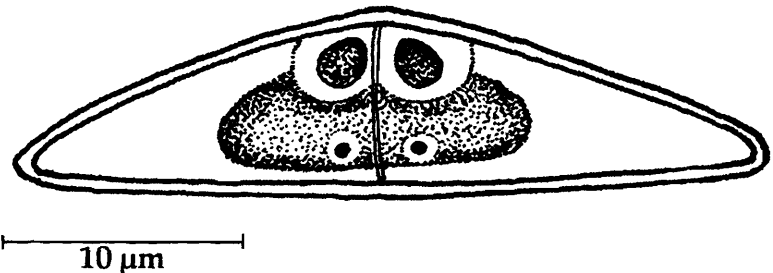


Fig. 72. *Ceratomyxa scatophagi* : a. Spore valvular view

71. *Ceratomyxa tenulosae* Sarkar and Pramanik, 1994b
(Fig. 73a-b)

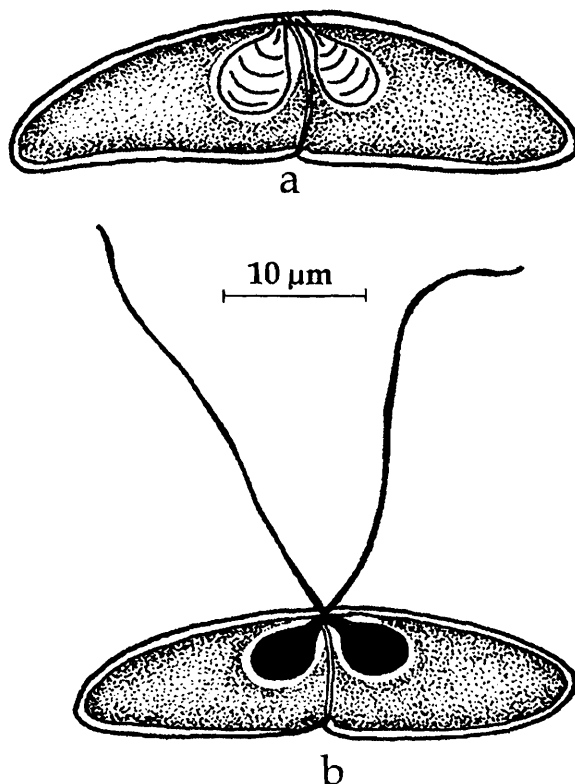


Fig. 73. *Ceratomyxa tenulosae* : a. Spore valvular view, b. Spore with extruded polar filament

Diagnosis : Spores elongated, anterior surface arched, posterior surface flat, straight with a constriction at the level of the suture; suture thin, bent; shell valves thin, smooth, symmetrical, extending laterally to form cones; polar capsules two, equal, pyriform; polar filaments forming 3-5 coils while inside the capsule; sporoplasm binucleate, finely granular, filling the extra capsular spore cavity; triad forms of the spores seen occasionally.

Size : Spore length 8.0-10.0 (9.2) μm , width 26.0-33.0 (31.0) μm ; polar capsule length 4.5-6.2 (5.6) μm , polar capsule width 4.0-5.5(4.7) μm ; polar filament length 28.0 μm .

Host : *Tenulosa toli* Palbs; *site of infection* : gall bladder; *pathogenicity* : not apparent.

Distribution : India : West Bengal (Hooghly estuary, Kakdwip).

72. *Ceratomyxa tartoori* Sarkar, 1986b
(Fig. 74a-b)

Diagnosis : Coelozoic; spore hemispherical in statural view with highly convex, round anterior surface and almost flat posterior surface, shell valves thin and smooth, each valve with an appendage or prolongation forming about 45° angle with the sutural axis; generally two lateral appendages, sometimes spores with 3-5 hollow appendages seen; appendages equal with pointed tips; suture thin, straight; polar capsules two, occasionally 3-4, spherical or nearly ovoidal with a very short neck; polar filament forming 3-4 coils while inside the capsule; sporoplasm granular, binucleate.

Size : Spore breadth 167.0-234.0 (212.0) μm , sutural diameter 14.0-19.0 (16.12) μm ; polar capsule (spherical) 6.0-7.0 μm in diameter; polar capsule (oval) length 5-7 (6.29) μm ; width 5-7 (5.5) μm ; polar filament length 20-28 μm .

Host : *Opisthopterus tartoor* Day; **site of infection** : gall baldder; **pathogenicity** : not apparent.

Distribution : India; West Bengal (Medinipur district).

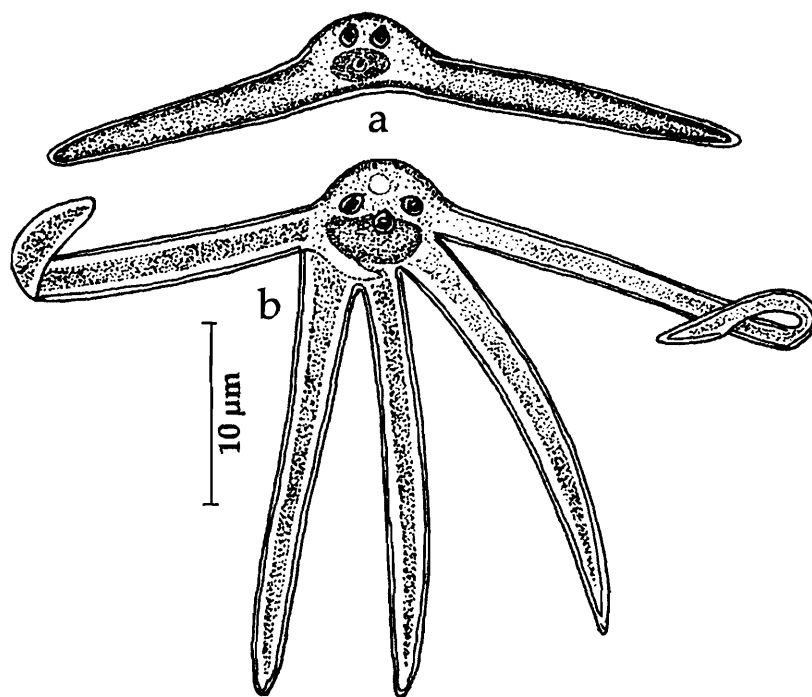


Fig. 74. *Ceratomyxa tartoori* : a. Spore with 2 polar capsules, b. Spore with 3 polar capsules

73. *Ceratomyxa thrissoclesi* Padma Dorothy, Kalavati and Vaidehi, 1998
(Fig. 75a-b)

Diagnosis : Coelozoic; pansporoblast disporous; spores transversely elongated, valves thick, smooth, drawn out laterally, ends pointed, sutural line straight, polar capsule oval, closely placed polar filament making 3-4 coils while inside the capsule, long and thick when extended; sporoplasm hyaline, binucleate, heart shaped.

Size : Spore breadth 81.7-98.7 (88.58) μm , sutural diameter 8.6-10.32 (9.53) μm ; polar capsule length 3.44-5.16 (4.57) μm , width 3.4-4.0 (3.58) μm ; polar filament length 30-45 (35.0) μm .

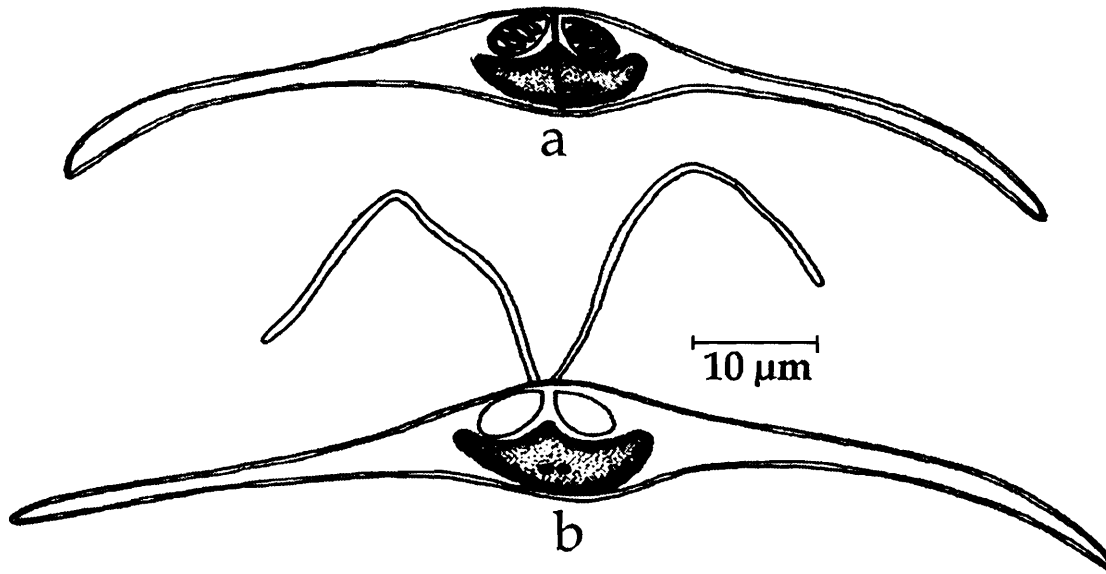


Fig. 75. *Ceratomyxa thrissoclesi* : a. Spore stained with Giemsa, b. Spore with extruded polar filament

Host : *Thrissocles mystasc*; *site of infection* : gall bladder; *pathogenicity* : not apparent.

Distribution : India : Andhra Pradesh (Off Visakhapatnam, Bay of Bengal, Visakhapatnam district).

Family SPHAEROSPORIDAE Davis, 1917

Diagnosis : As in the key.

Key to the genera

- 1. Spore spherical or subspherical..... 3
- 2. Spore elongated..... 4
- 3.1 Spore spherical or subspherical, valvular diameter not exceeding significantly the sutural diameter; sutural ridge often prominent; polar capsule subspherical or pyriform; two uninucleate sporoplasms; mono or disporous trophozoites.....
..... *Sphaerospora*
- 3.3 Spore subspherical enclosed in a membranous veil which in immature spores twisted in 2 cords around the spore; sutural ridge prominent, anteriorly; polar capsules pyriform; sporoplasm binucleate; trophozoite di or polysporous.....
..... *Palliatius*
- 4.1 Spore elongated with pointed anterior end, shell valves often ridged and extend posteriorly into a caudal appendage; polar capsule pyriform with or without an iodophilous vacuole; trophozoite di or polysporous..... *Myxobilatus*

Genus *Sphaerospora* Thelohan, 1892

Diagnosis : As in the key.

Key to the species

- 1(2). Spore 4-5 μm in diameter; shell valve with strong striations *S. mayi*
 2(1). Spore 4.8-5.0 μm x 4.71-4.82 μm ; shell valves smooth *S. corsulae*

74. *Sphaerospora mayi*, Moser, Kent and Dennis, 1989
 (Fig. 76a-c)

Diagnosis : Pansporoblast disporous; spores spherical or subspherical; valves with strong striations; sutural ridge straight, prominent, tapering to a fine point at the posterior end; polar capsule subspherical, parallel to sutural ridge, terminal; polar filament forming 5-6 coils while inside the capsule; intercapsular appendix prominent, deeply stained, rod-like; 2 uninucleate sporoplasms, one on either side of sutural ridge; developmental stages in blood include pseudoplasmodia with variable number of nuclei and sporoblasts.

Size : Spore diameter 4.0-5.0 (4.5) μm ; polar capsule length 2.0-2.58 (2.2), width 1.8-2.0 (1.9) μm ; polar filament length 18.0-26 (23.0) μm .

Host : *Mugil cephalus*; *site of infection* : intestinal epithelium, visceral peritoneum, gill epithelium and blood : *pathogenicity* : infected fish become soft and slimy; significant changes in serum proteins and blood glucose reported.

Distribution : India : Andhra Pradesh (Visakhapatnam harbour, Visakhapatnam district). *Elsewhere* : Heron island, Australia.

Remarks : Kalavati and Anuradha (1992) recorded this species in Indian host.

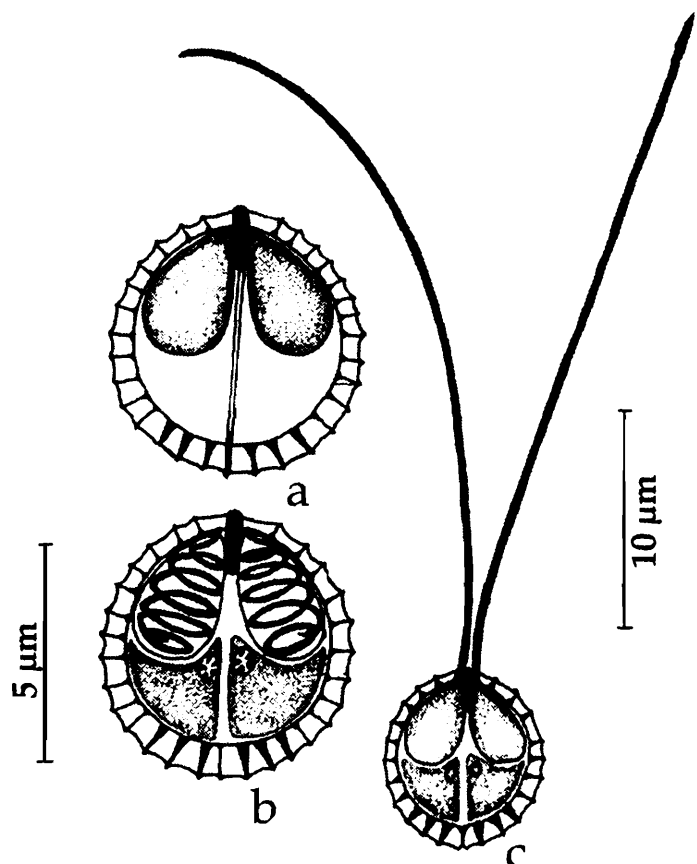


Fig. 76. *Sphaerospora mayi* : a. Fresh spore valvular view, b. Spore stained with Giemsa, c. Spore with extruded polar filament

75. *Sphaerospora corsulae* Sarkar and Ghosh, 1991b
(Fig. 77a-c)

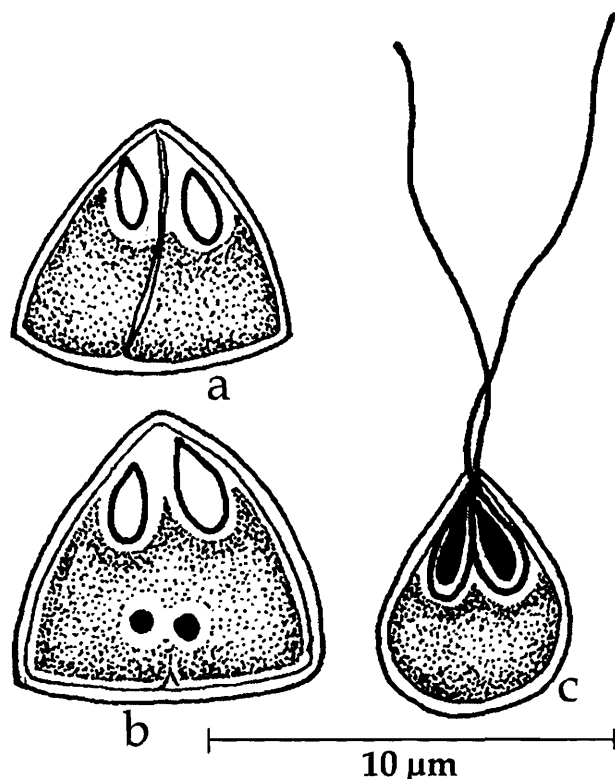


Fig. 77. *Sphaerospora corsulae* : a. Fresh spore valvular view, b. Spore stained with Giemsa, c. Spore with extruded polar filament

Diagnosis : Spores small, conoid in sutural view, ellipsoid to quadrilateral in apical view; shell valves thin, smooth with one longitudinal ridge parallel to suture, symmetrical without any appendages; sutural line thin; polar capsule pyriform to ovoidal, convergent and terminal.

Size : Spore length 4.8-5.0 (4.9) μm , width 4.71-4.82 (4.76) μm ; polar capsule length 1.69-1.78 (1.74) μm , width 1.1-1.22 (1.17) μm ; polar filament length 12.64 μm .

Host : *Rhinomugil corsula* (Ham.); **site of infection** : gall bladder; **pathogenicity** : bile becomes thick and jelly-like.

Distribution : India : West Bengal (Hooghly estuary)

Genus *Palliatius* Schulman, Koveleva and Dubina, 1979

Diagnosis : As in the key.

76. *Palliatius indicus* Padma Dorothy and Kalavati, 1998
(Fig. 78a-e)

Diagnosis : Development monosporous; spores oval, anterior end broad, posterior end bluntly tapering; a smooth membranous envelope arising at the anterior end and extending to the posterior end encircling the spore; a pair of broad triangular 'keel'-like appendages present along sutural ridge on either side of the spore enclosing the spore body like a parachute; valves thin, smooth, unequal; sutural ridge prominent slightly curved extending as small curved spine; polar capsules 2, pyriform, convergent, terminal, tip of the capsule deeply stained as a small plug-like structure; polar filament making 4-5 coils while inside the capsule; sporoplasm dumb-bell shaped, homogeneous, granular.

Size : Spore length 9.1-10.5 (9.84) μm , width 7.0-7.7 (7.02) μm ; polar capsule length 3.5-4.2 (4.1) μm , width 2.8-3.5 (3.05) μm ; polar filament length 14.4-22.5 (17.79) μm .

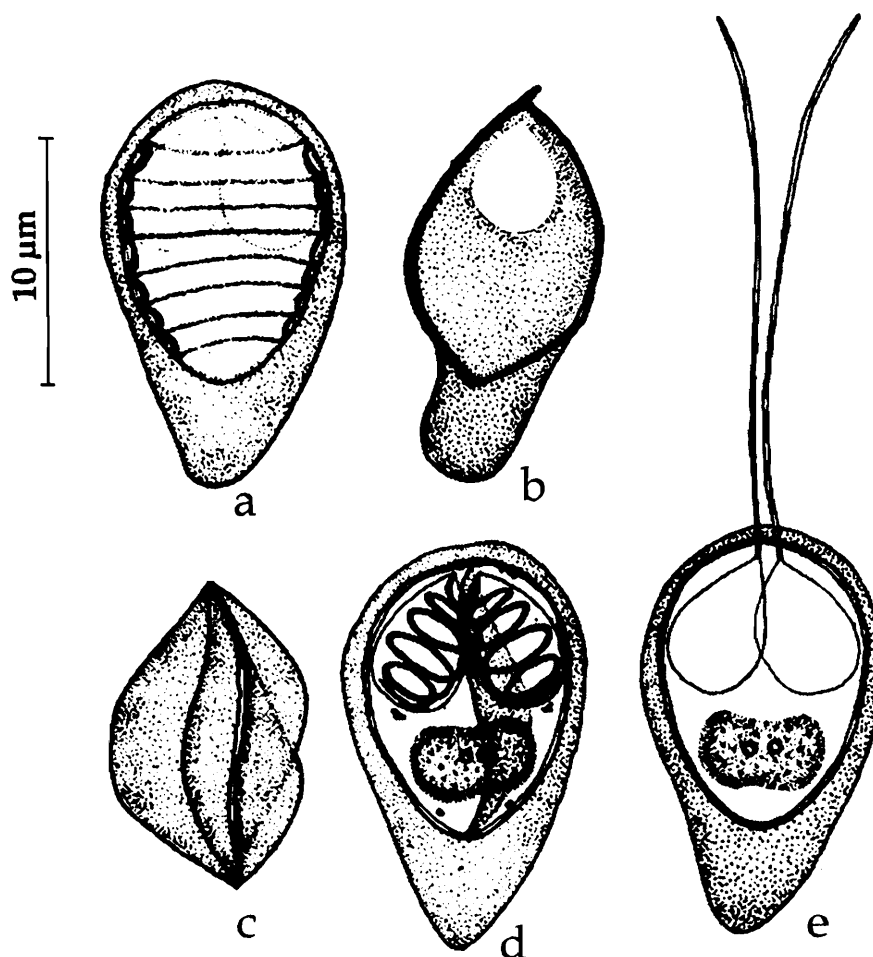


Fig. 78. *Palliatus indicus* : a. Developing spore showing twisted cords, b. Spore sutural view, c. Spore showing keels, d. Spore stained with Giemsa, e. Spore with extruded polar filament

Host : *Liza macrolepis*; *site of infection* : pancreas; *pathogenicity* : parasite induced reduction in Islets of Langerhans with consequent impairment of glucose metabolism. Infected fish showed weight loss and appeared morbid.

Distribution : India : Andhra Pradesh (Off Bheemunipatnam, Bay of Bengal, Visakhapatnam district).

Genus *Myxobilatus* Davis, 1917

Diagnosis : As in the key.

Key to the species

- 1. Spores oval 4
- 2. Spores lanceolate 5
- 3. Spores variable 6

- 4.1 Spores transparent, elongately oval, 8.4-9.8 μm x 4.2-5.6 μm ; polar capsules unequal *M. notopterus*
- 4.2 Spores elongate, oval, 11.2-14.4 μm x 4.8-3.2 μm in size..... *Myxobilatus* sp.
- 4.3 Spore oval with anterior knob, 5.0-7.5 μm x 3.3 -4.2 μm *M. anguillar*
- 5.1 Spores lanceolate, 8.1-10.3 μm x 4.8-6.3 μm , polar capsules pyriform
..... *M. odontamblyopusi*
- 5.2 Spores lanceolate or elliptical, 26.73-40.5 μm x 13.2-18.0 μm , polar capsules pyriform *M. fossilis*
- 6.1 Spores variable; occurring in 2 different types, 8.5-12.5 μm x 4.6-6.16 μm . in size
..... *M. mastacembeli*

77. *Myxobilatus anguillar* Basu and Haldar, 2003

(Fig. 79a-c)

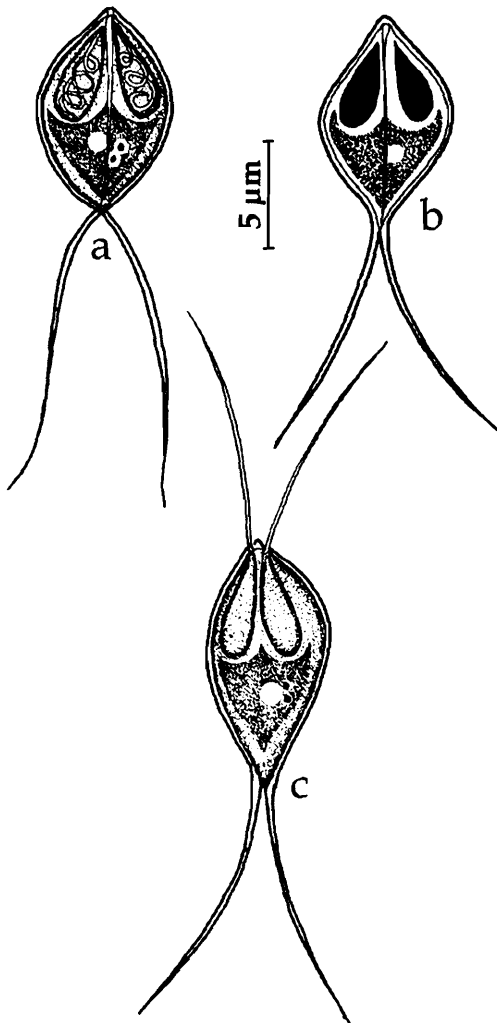

Fig. 79. *Myxobilatus anguillar* : a. Fresh spore valvular view, b. Spore stained with Giemsa, c. Spore with extruded polar filament

Diagnosis : Sporogonic plasmodia encased within the host cell appear like cysts; cysts creamy white, elongate, 0.6-0.8 mm x 0.4-0.5 mm; mature spores ovoid with one side flattened and the other strongly convex in sutural view; shell valves smooth symmetrical, without striations, extending into two long, equal, bifurcated caudal process; characteristic knob-like protrusion present at the anterior extremity between the polar capsules; sutural line straight; polar capsules equal, elongated, polar filament making 4-5 coils while inside the capsule; sporoplasm binucleate, triangular with the apex situated at the junction of the caudal process; iodophilous vacuole at the centre of sporoplasm.

Size : Spore body length 5.0-7.5 (6.2) μm , width 3.3-4.2 (3.7) μm ; caudal process length 4.2-9.1 (7.0) μm ; polar capsule length 1.7-3.3 (2.7) μm , width 0.8-1.7 (1.6) μm .

Host : *Taenioides anguillar*; **site of infection** : basal portion of gill filaments; **pathogenicity** : not reported.

Distribution : India : West Bengal (Canning, South 24-Parganas district)

78. *Myxobilatus fossilis* Susha and
Janardanan, 1994
(Fig. 80a-c)

Diagnosis : Coelozoic; development polysporous; spores lanceolate in sutural view, elliptical in valvular view; shell valves uniformly thick, symmetrical extending into long tapering caudal process; polar capsules 2, equal, pyriform; polar filament making 6-7 coils while inside the capsule; sporoplasm finely granular, binucleate occupying the space behind the polar capsules; iodophilous vacuole present.

Size : Spore length total 26.73–40.5 (32.39) μm ; spore body length 13.2–18.0 (17.84) μm , width 5.94–9.0 (6.52) μm ; polar capsule length 4.5–6.9 (6.27) μm , width 1.98–3.3 (2.84) μm ; polar filament length 21.0–45.0 (32.0) μm .

Host : *Heteropneustes fossilis*; **site of infection** : urinary bladder; **pathogenicity** : not apparent.

Distribution : India : Kerala (Irrigation canals Valapad, Thissur district).

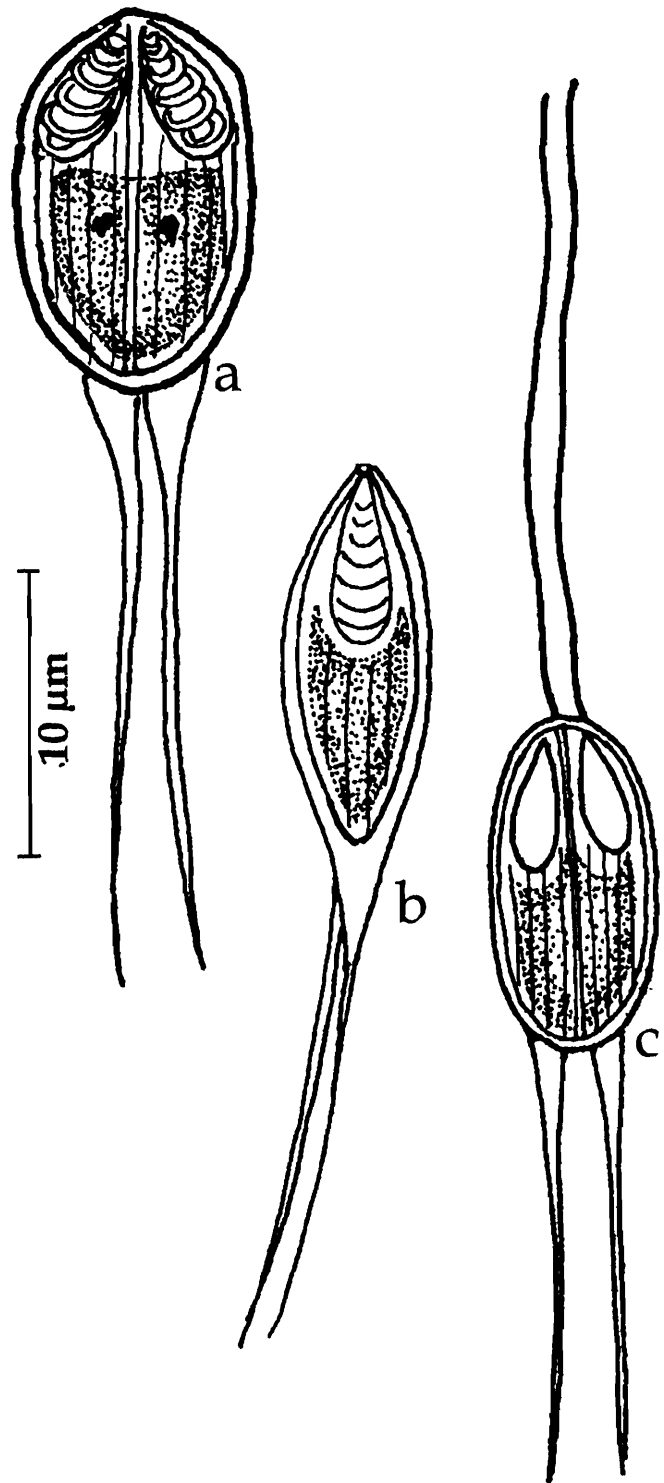


Fig. 80. *Myxobilatus fossilis* : a. Spore stained with Giemsa, b. Spore sutural view, c. Spore with extruded polar filament

79. *Myxobilatus mastacembeli* Qadri and Lalitha Kumari, 1965
(Fig. 81a-b)

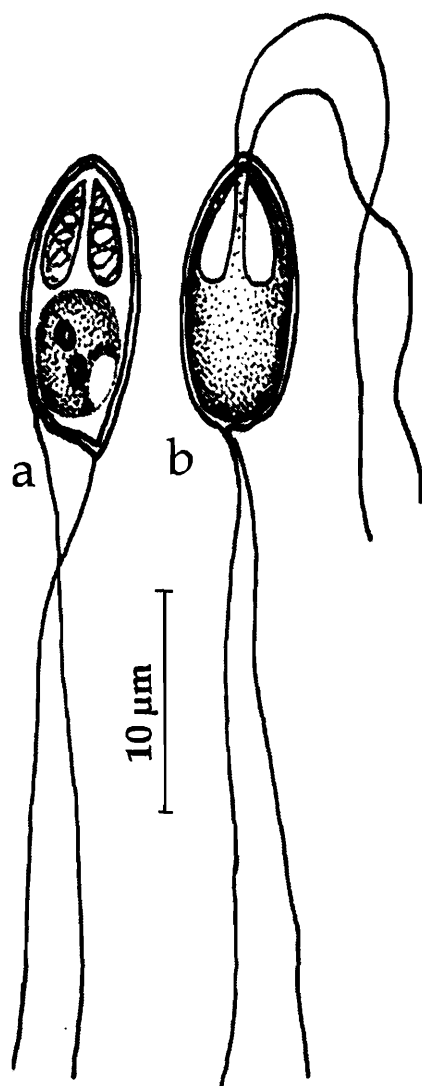


Fig. 81. *Myxobilatus mastacembeli* : a. Spore stained with Giemsa, c. Spore with extruded polar filament

Diagnosis : Trophozoites milky-white, spherical about 1 mm in diameter; development disporous; spores flat, 2 types; smaller spores pyriform, others elongated, anterior end blunt, narrow, posterior end round; shell valves thin, transparent; caudal process 2, long, filamentous; polar capsules 2, equal, terminal, pyriform; polar filaments tubular, equal; sporoplasm granular, occupying the space behind the polar capsules; iodophilous vacuole large, posterior.

Size : Spore length 8.5-12.5 (9.0) μm , width 4.6-6.16 (4.8) μm ; length of the caudal appendages 15.0 -28.0 (19.0) μm ; polar capsule length 3.1-3.9 (3.7) μm , width 1.5-1.9 (1.65) μm .

Host : *Mastacembelus armatus*; **site of infection** : intestine; **pathogenicity** : not reported.

Distribution : India : Andhra Pradesh (Local fish market, Hyderabad city).

80. *Myxobilatus notopterus* Kalavati and Vaidehi, 1996
(Fig. 82a-c)

Diagnosis : Coelozoic, development monosporous; spores transparent, elongately oval with slightly pointed anterior end; shell valves thin, symmetrical, smooth, refringent extending into long, thin bifurcated caudal process with pointed tips; sutural line straight, polar capsules unequal, terminal, pyriform with long neck adherent to the spore valve; intercapsular space lightly stained; polar filament making 3-4 coils while inside the capsule; sporoplasm binucleate, irregular, granular, located in the space behind the polar capsules; iodophilous vacuole absent.

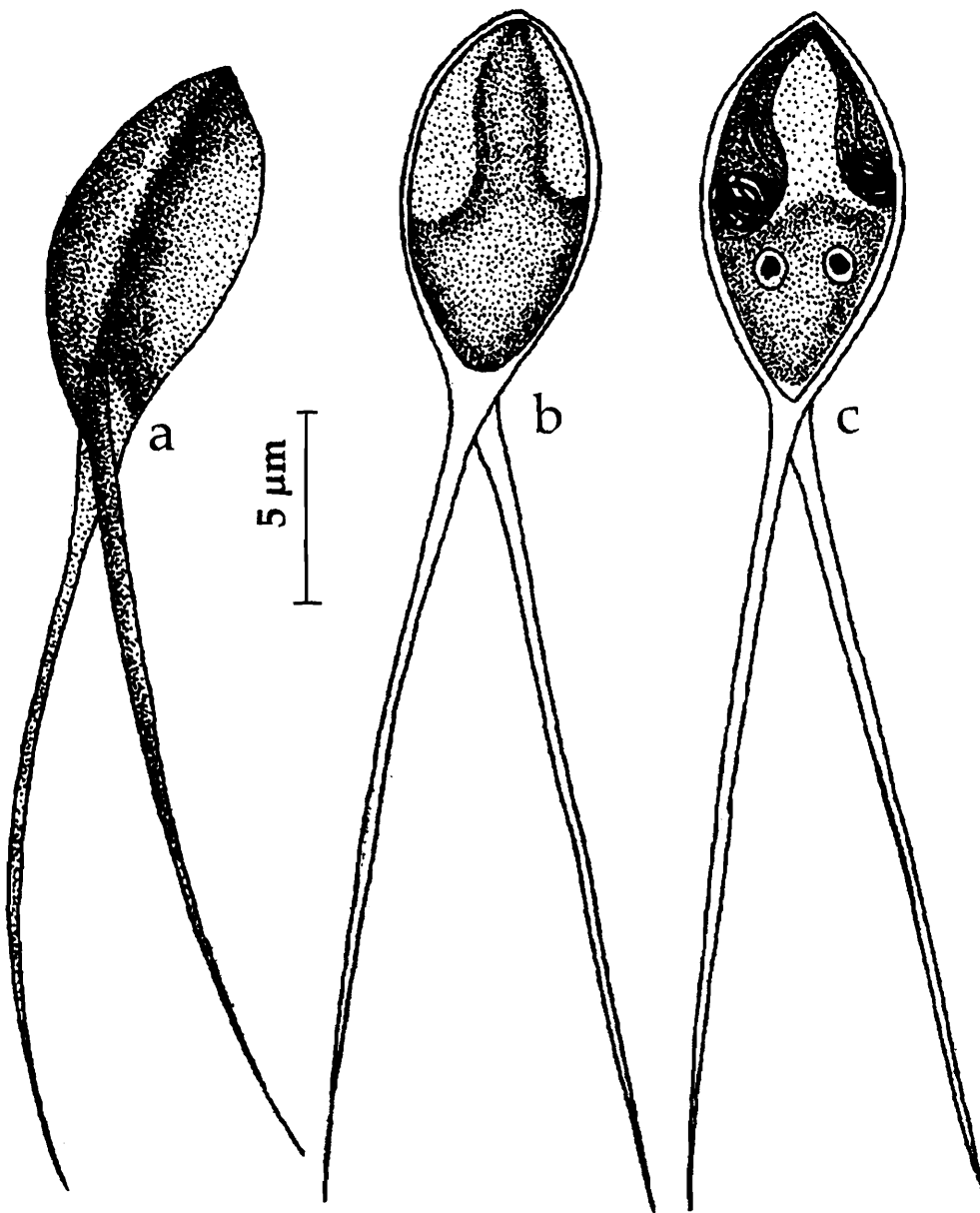


Fig. 82. *Myxobilatus notopterus* : a. Fresh spore sutural view, b. Spore valvular view, c. Spore stained with Giemsa

Size : Spore total length 30.8 – 39.2 (33.3) μm ; spore body length 8.4-9.8 (9.3) μm , width 4.2-5.6 (4.5) μm ; caudal process length 15-28 (19.0) μm ; polar capsule (long) length 5.6-7.0 (6.1) μm , width 1.5-2.5 (1.85) μm ; polar capsule (small) length 4.2-5.6 (4.7) μm ; polar filament length 22.4-29.5 (24.65) μm .

Host : *Notopterus notopterus*; *site of infection* : gall bladder; *pathogenicity* : not reported.

Distribution : India : Orissa (Chilka Lake).

81. *Myxobilatus odontamblyopusi* Basu and Haldar, 2004
(Fig. 83a-d)

Diagnosis : Cysts yellowish white, elongate, ellipsoidal 0.77-1.56 mm x 0.66-1.44 mm; spores histozoic, lanceolate in valvular view with pointed anterior and posterior ends and oval with one convex and the other concave sides in sutural view; shell valves moderately thick symmetrical, with fine striations; valves extending into long, equal, bifurcated caudal process with pointed tips; sutural line straight; polar capsules equal, pyriform; polar filament making 5-6 coils while inside the capsule; sporoplasm binucleate, irregular, granular, occupying the space behind the polar capsules; iodophilous vacuole absent.

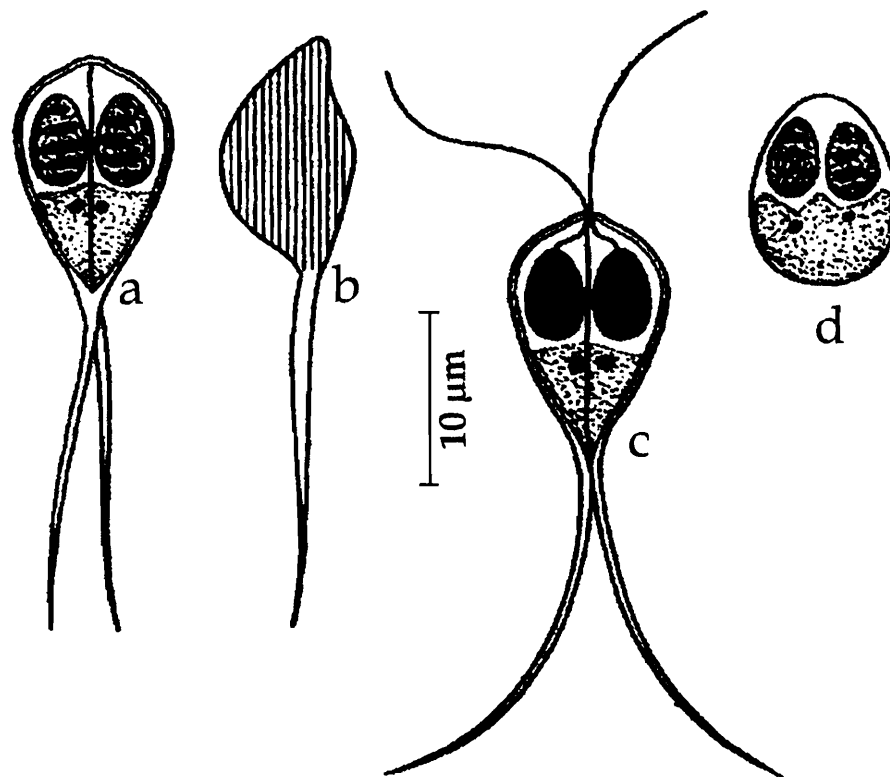


Fig. 83. *Myxobilatus odontamblyopusi* : a. Spore stained with Giemsa, b. Fresh spore valvular view, c. Spore with extruded polar filament, d. Developing spore

Size : Spore body length 8.1-10.3 (9.0) µm, width 4.8-6.3 (5.2) µm; caudal process length 17.9-24.9 (20.6) µm; polar capsule length 3.0-3.9 (3.4) µm, width 1.9-2.5 (2.1) µm.

Host : *Odontamblyopus rubicundus*; *site of infection* : gill filaments; *pathogenicity* : not reported.

Distribution : India : West Bengal (Canning, South 24 Parganas district).

6. *Myxobilatus* sp. Anuradha and Kalavati, 1987
(Fig. 84a-c)

Diagnosis : Trophozoites opaque, small, 750-950 µm; spores elongate, oval; shell valves smooth, thin; caudal process bifurcated at the posterior end; polar capsules unequal, pyriform, placed at different levels; iodophilous vacuole large, spherical, posterior; polar filament making 4 coils while inside the capsule; sporoplasm oval, binucleate.

Size : Spore body length 11.2-14.4 (13.08) µm, width 4.8-3.2 (4.03) µm; polar capsule (large) length 3.0-4.8 (3.4) µm, width 0.8-1.2 µm; polar capsule (small) length 2.4-4.0 µm, width 1.6 µm.

Host : *Clarias batrachus*; **site of infection** : palate; **pathogenicity** : not reported.

Distribution : India : Andhra Pradesh (Kakinada, Rajhamundry, East Godavari district).

Remarks : The specific determination of the species is awaited for want of more material as well as literature.

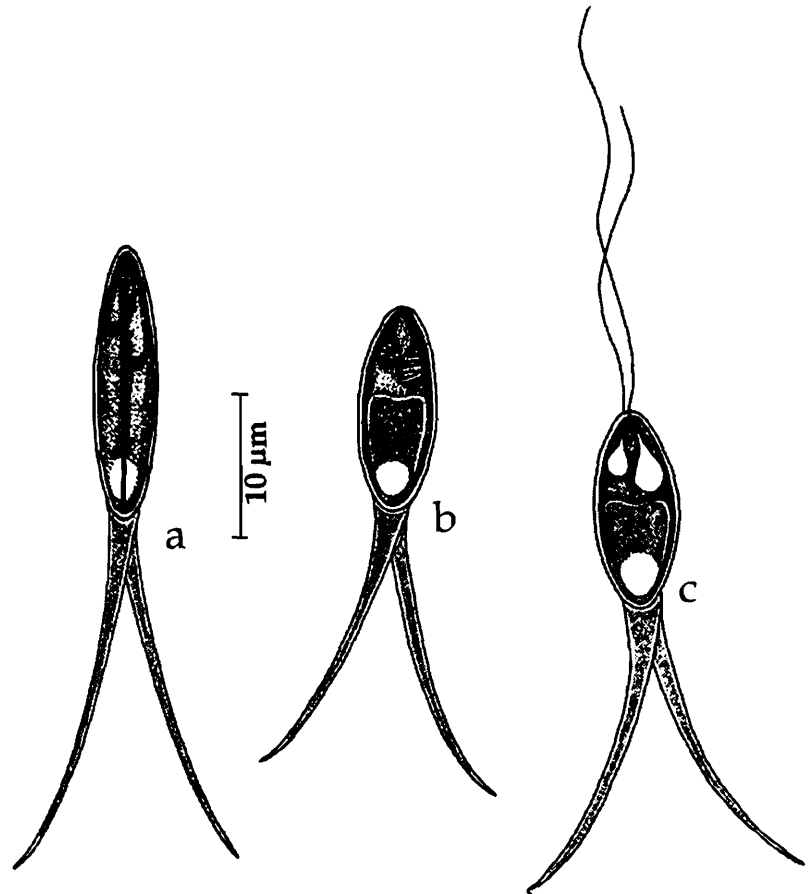


Fig. 84. *Myxobilatus* sp. : a. Spore sutural view, b. Spore stained with Giemsa, c. Spore with extruded polar filament

Family CHLOROMYXIDAE Thelohan, 1892
Genus *Chloromyxum* Mingazzini, 1890

Diagnosis : As in the key.

Key to the species

1. Spores spherical 4
2. Spore inverted, pyriform, 18.0-22.0 µm x 16.5-21.0 µm; polar capsule elongated or pyriform, unequal *C. mitchelli*
3. Spore ovoidal 5
- 4.1 Polar capsules unequal; spores 5.7-7.1 µm, valves with 8-10 longitudinal striations; polar capsule pyriform or flask shaped *C. hoarei*

- 4.2 Polar capsules equal
- 4.2.1 Spores 10.8-12.0 μm , polar capsules pyriform *C. tripathii*
- 4.2.2 Spore 8.24-10.3 μm in diameter; shell valve striated, polar capsule oval
..... *C. amphinoui*
- 4.2.3 Spore 9-10 μm in diameter, shell valve without any striations, polar capsule spherical; 2.7-3.6 μm in diameter *C. mrigalae*
- 4.2.4 Spore 7.2 μm in diameter, polar capsule spherical..... *Chloromyxum* sp.
- 5.1 Spore small, with truncated narrower end, 11-16.5 μm x 9-13 μm ; valves smooth; polar capsule ovoid to pyriform, equal *C. meglitschi*
- 5.2 Spore with rounded ends, 7-9 μm x 4-6 μm ; valves striated; polar capsule pyriform, equal *C. puntiusi*
- 5.3 Spore with rounded ends, 8.3-10.5 μm x 6.0-7.5 μm ; valves striated; polar capsule pyriform, unequal *C. heteropneustesi*

83. *Chloromyxum amphinoui* Ray, 1933

(Fig. 85a-c)

Diagnosis : Trophozoites oval or spherical in outline, measuring 14.4-35 μm x 16.5-40.0 μm ; spore almost spherical in front view, ovoidal in side view; shell valves alike and striated; sutural line fine; polar capsules equal, oval with attenuated anterior end; sporoplasm filling the entire extracapsular space.

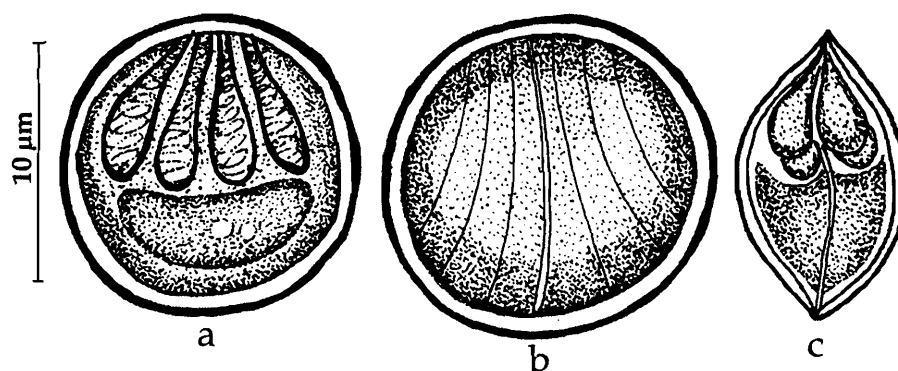


Fig. 85. *Chloromyxum amphinoui* : a. Fresh spore valvular view, b. Spore showing striations, c. Spore sutural view

Size : Spore breadth 8.24-10.3 μm ; polar capsule length 4.1-5.2 μm , width 3.1-4.0 μm ; polar filament length 35-40 μm .

Host : *Amphipnous cuchia* (Ham), *Heteropneustes fossilis* (Bloch) and *Amblypharyngodon mola* (Ham); **site of infection :** gall bladder; **pathogenicity :** not reported.

Distribution : India: West Bengal.

Remarks : Chakravarty and Basu (1948) reported this species from the gall bladder of *Amblypharyngodon mola*. The occurrence of this parasite in widely different hosts at the order level perhaps warrants reexamination of the material from the same hosts.

84. *Chloromyxum clariasum* Sarkar, 1994

(Fig. 86a-c)

Diagnosis : Trophozoite irregular, 14.0 μm x 9.0 μm , polysporous; spore small, oval to spherical with slightly narrower anterior end and broadly rounded posterior end; valves thick, smooth, symmetrical and slightly flattened, parallel to sutural axis; polar capsule 4, equal, pyriform, convergent; polar filament forming 5-7 horizontal coils while inside the capsule; sporoplasm large, hemispherical, binucleate filling the extracapsular spore cavity; iodophilous vacuole seen between the sporoplasmic nuclei.

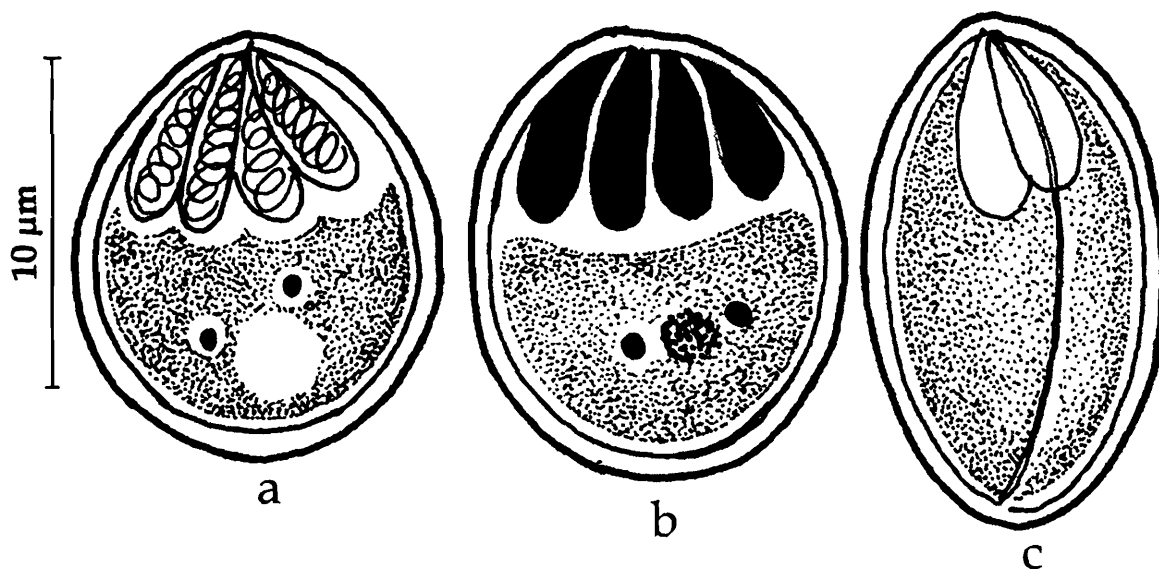


Fig. 86. *Chloromyxum clariasum* : a. Spore stained with Giemsa, b. Spore treated with iodine, c. Spore sutural view

Size : Spore length 7.0–11.0 (10.27) μm , width 8.0–9.0 (8.53) μm ; polar capsule length 4.5–5.0 (4.57) μm , width 1.5–2.0 (1.97) μm .

Host : *Clarius batrachus* L.; **site of infection** : gall bladder; **pathogenicity** : not apparent.

Distribution : India : West Bengal (Hugli district).

85. *Chloromyxum heteropneustes* Rajendran and Janardanan, 2005

(Fig. 87 a-d)

Diagnosis : Plasmodia variable in shape, 37.0–76.0 μm x 22.0–45.0 μm in size, with one to several branched or lobose pseudopodia; spores oval in valvular view, lenticular in sutural view and spherical in apical view; shell valves uniformly thick, equal,

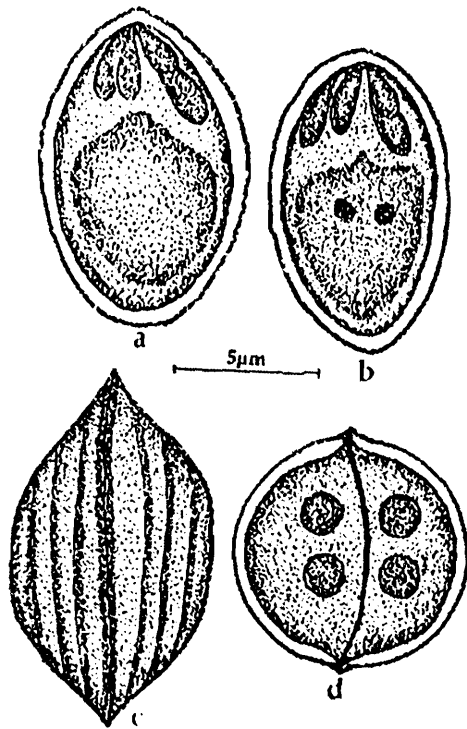


Fig. 87. *Chloromyxum heteropneustesi* : a. Spore valvular views, b. Spore stained with Giemsa, c. Spore sutural view striations, d. Spore capsular view

symmetrical with fine striations running parallel to sutural line; sutural ridge straight to slightly curved and raised; polar capsules 4, unequal pyriform, terminal; polar filament making 3-4 coils while inside the capsule; sporoplasm cup-shaped, binucleate, extending into the intercapsular space.

Size : Spore length 8.3-10.5 (9.4) μm ; width 6.0-7.5 (6.6) μm ; polar capsule length 2.3-3.0 (2.8) μm , width 1.5-1.9 (1.6) μm .

Host : *Heteropneustes fossilis*; *site of infection* : gall bladder; *pathogenicity* : increased viscosity and discolouration of bile.

Distribution : India : Kerala (Malappuram, Edappal).

86. *Chloromyxum hoarei* Lalitha Kumari, 1969

(Fig. 88 a-c)

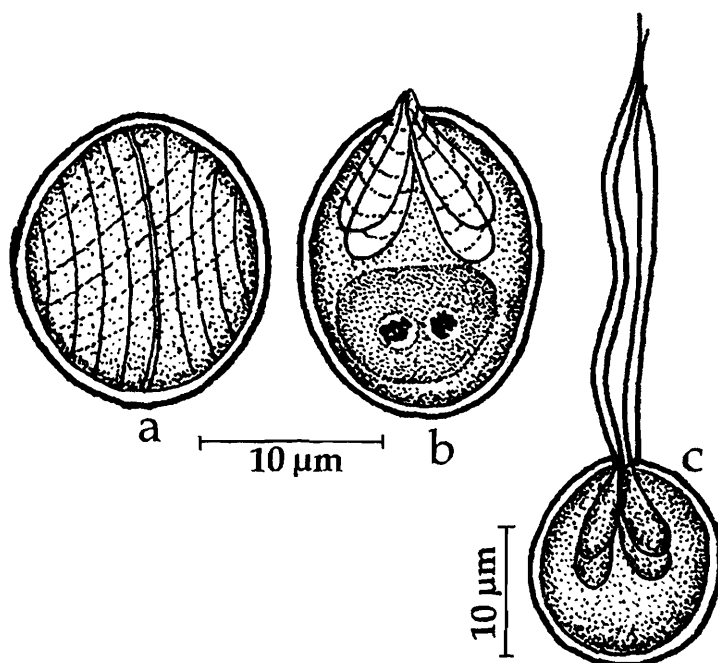


Fig. 88. *Chloromyxum hoarei* : a. Spore valvular view, b. Spore stained with Giemsa, c. Spore with extruded polar filament

Diagnosis : Spores spherical in valvular view and oval in sutural view; shell valves equal and uniform with 8-10 longitudinal striations; sutural ridge broad, thick projecting out of the spore valves and appearing like a knob; polar capsules 4, unequal, pyriform or flask-shaped, subterminal and one of the capsules often curved; polar filaments unequal, forming 4-5 coils within the capsule; sporoplasm granular and homogenous.

Size : Spore diameter 5.7-7.1 (6.4) μm ; polar capsule (large) length 2.5-3.5 (2.9) μm , width 1.4-2.1 (1.8) μm ; polar capsule (small) length 1.4-2.1 (1.8) μm , width 1.0-1.8 (1.4) μm ; polar filament length 35-40 μm .

Host : *Labeo nigripinnis*; *site of infection* : gall bladder; *pathogenicity* : not reported.

Distribution : India : Andhra Pradesh (Hyderabad and Warangal district).

87. *Chloromyxum meglitschi* Sarkar, 1982b
(Fig. 89 a-b)

Diagnosis : Trophozoite coelozoic, ellipsoidal, disporous; spore small, ovoidal with truncated narrower end; shell valve smooth; suture slightly curved; polar capsule 4, opening through small narrow duct, ovoid to pyriform, located towards the broader end of the spore; sporoplasm with uniformly dispersed fine granules.

Size : Spore length 7.0–8.5 (7.9) μm , width 6.0–8.0 (7.0) μm ; polar capsule length 2.0–3.5 (2.7) μm , width 2.0–2.5 (2.0) μm .

Host : *Ophicephalus punctatus* Bloch; *site of infection* : gall bladder; *pathogenicity* : not reported.

Distribution : India : West Bengal (North 24 – Parganas district).

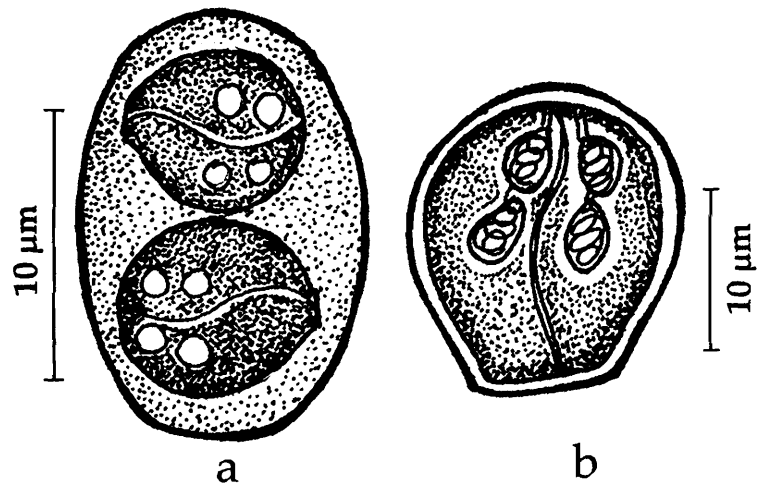


Fig. 89. *Chloromyxum meglitschi* : a. Disporous trophozoite, b. Spore

88. *Chloromyxum mitchelli* Kalavati and Narasimhamurti, 1984b
(Fig. 90 a-d)

Diagnosis : Spores inverted, pyriform, anterior end broad, posterior end bluntly pointed; shell valves equal, symmetrical with fine translucent striations; sutural ridge thin, straight; polar capsules 4, terminal, unequal; 2 large capsules, elongated, polar filament showed 8 coils while inside the capsule, long and fine when extended; smaller capsules 2, pyriform, polar filament forming 5 coils while inside the capsule; sporoplasm irregular in the posterior part of the spore.

Size : Spore length 18.0–22.0 (21.0) μm , width 16.5–21.0 (20.5) μm ; polar capsule (large) length 6.5–8.5 (8.0) μm , width 2.0–2.5 (2.2) μm ; polar capsule (small) length 4.5–5.5 (5.0) μm , width 1.0–2.0 (1.68) μm ; polar filament (long) length 75–80 (78.0) μm , polar filament (short) 45–55 (50.0) μm .

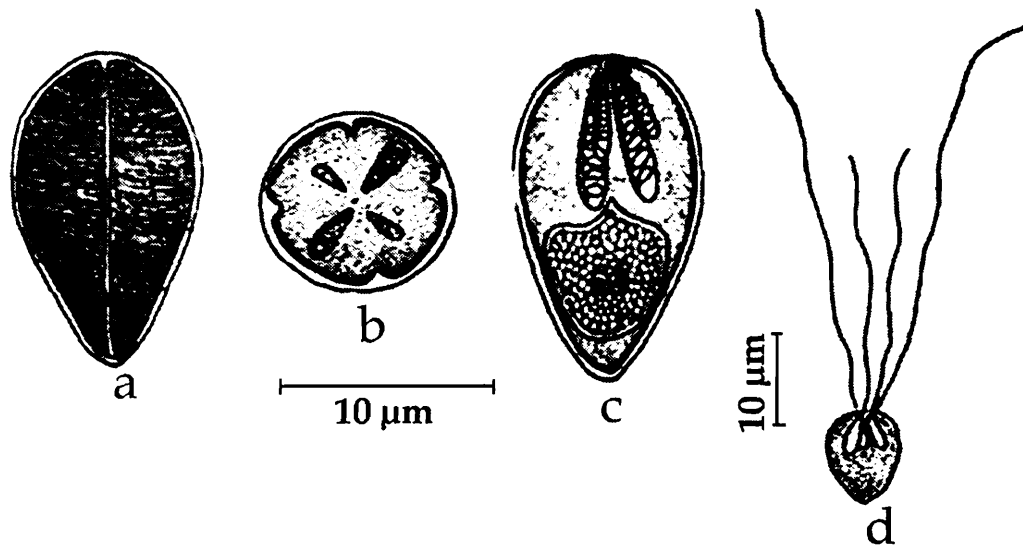


Fig. 90. *Chloromyxum mitchelli* : a. Spore surface view, b. Spore stained with Giemsa, c. Spore valvular view, d. Spore with extruded polar filament

Host : *Therapon jarbua*; *site of infection* : kidney; *pathogenicity* : not reported.

Distribution : India : Andhra Pradesh (Visakhapatnam district).

89. *Chloromyxum mrigalae* Tripathi, 1952
(Fig. 91 a-c)

Diagnosis : Trophozoite globular, 19.8-23 μm in diameter; spore spherical, with thin and smooth shell valves; sutural line distinct and slightly curved; polar capsules 4, equal, spherical; sporoplasm filling half of the extracapsular cavity.

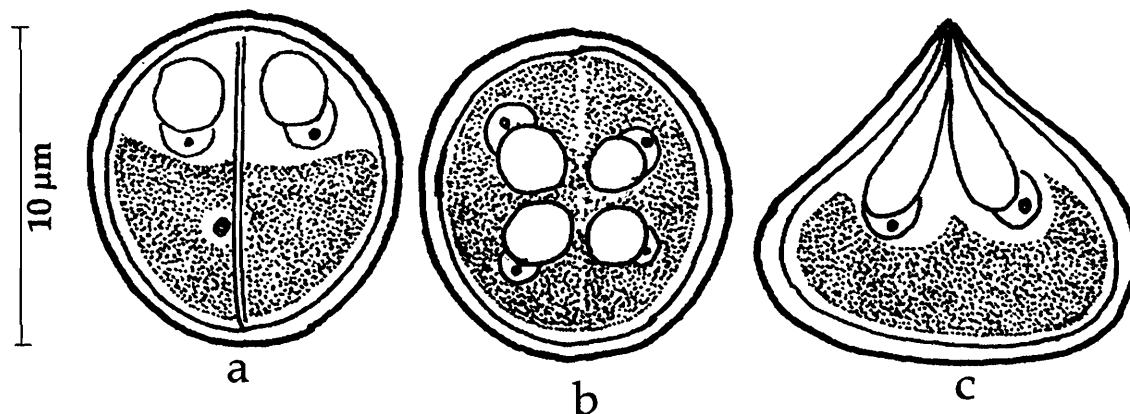


Fig. 91. *Chloromyxum mrigalae* : a. Spore surface view, b. apical view, c. lateral view

Size : Spore diameter 7-10 μm ; polar capsule 2.7 - 3.6 μm in diameter.

Host : *Cirrhinus reba* (Ham.) and *C. mrigala* (Ham); *site of infection* : gall bladder; *pathogenicity* : not reported.

Distribution : India : West Bengal (North 24 Parganas district).

90. *Chloromyxum puntiusi* Rajendran and Janardanan, 2005
(Fig. 92 a-e)

Diagnosis : Plasmodia variable, spherical or oval or irregular in shape, 25.0-42.0 μm x 22.0-36.0 μm in size, with fine filaments along the margin; spores oval in valvular view, lenticular in sutural view and spherical in apical view; shell valves uniformly thick, equal, symmetrical with fine striations that run parallel to sutural line, sutural ridge slightly curved; polar capsules 4, equal, pyriform, terminal; polar filament inside the capsule not visible; sporoplasm cup-shaped, binucleate, filling the entire spore cavity.

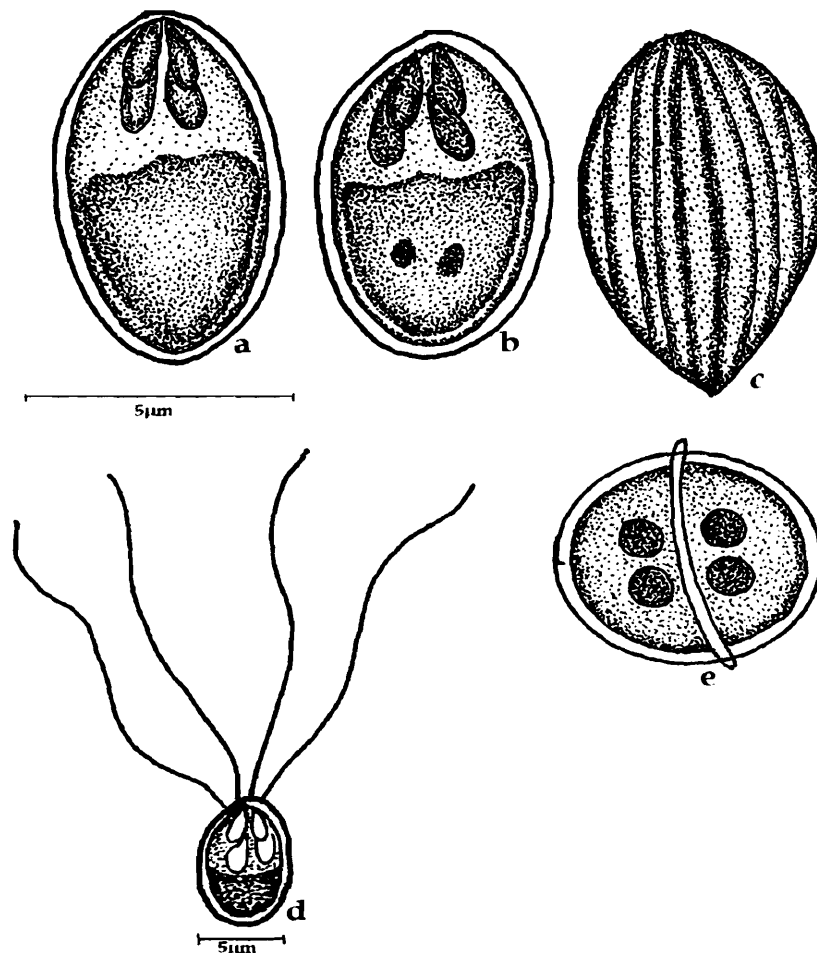


Fig. 92. *Chloromyxum puntiusi* : a. Fresh spore valvular view, b. Spore stained with Giemsa, c. Spore sutural view showing striations, d. Spore with extruded polar filament, e. spore capsular view

Size : Spore length 7.0-9.0 (8.0) μm ; width 4.0-6.0 (5.0) μm ; polar capsule length 3.0-3.8 (3.1) μm 1.1-1.5 (1.4) μm ; polar filament length 30-34 (33.0) μm .

Host : *Puntius amphibious*; **site of infection** : gall bladder; **pathogenicity** : increased viscosity of bile.

Distribution : India : Kerala (Ramanattukara, Calicut district).

91. *Chloromyxum tripathii* Kalavati and Narasimhamurti, 1984b
(Fig. 93 a-c)

Diagnosis : Pansporoblasts disporous; spore spherical; shell valves equal, smooth with 3-4 parietal folds at the capsular end; sutural ridge straight, prominent; polar capsules 4, pyriform, terminal; polar filament forming 5-6 coils while inside the capsule; sporoplasm hat-shaped, located beneath the polar capsules extending into intercapsular region; no iodophilous vacuole.

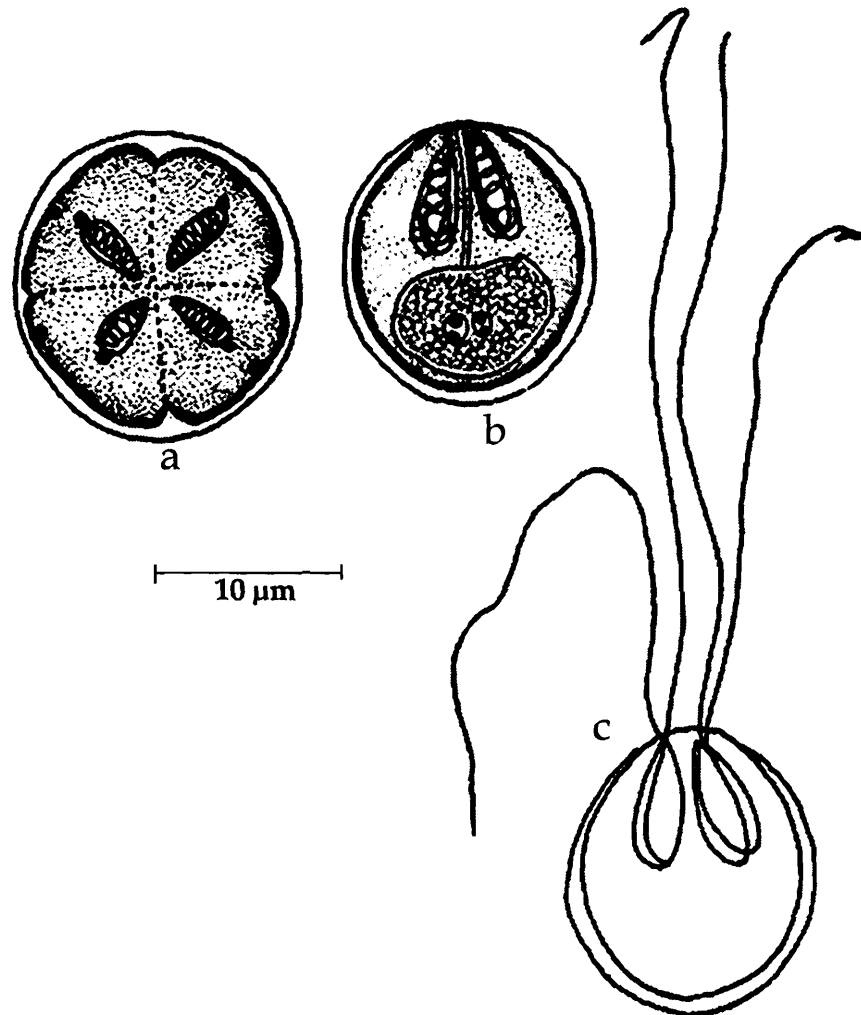


Fig. 93. *Chloromyxum tripathii* : a. Spore stained with Giemsa apical view, b. Spore lateral view, c. Spore with extruded filaments

Size : Spore diameter 10.8-12.0 (11.2) μm ; polar capsule length 4.2-5.0 (4.8) μm , width 2.1-2.6 (2.4) μm ; polar filament length 23-34 (32.0) μm .

Host : *Therapon jarbua*; *site of infection* : gall bladder; *pathogenicity* : hypertrophy and hardening of the gall bladder, fraying of the bladder epithelium and leucocyte accumulation induced by the parasite.

Distribution : India : Andhra Pradesh (Elamanchili and Visakhapatnam, Visakhapatnam district; Srikakulam, Srikakulam district).

92. *Chloromyxum* sp. Tripathi, 1952

Diagnosis : Spore spherical, shell valves smooth; sutural line slightly raised; polar capsules equal, spherical.

Size : Spore 7.2 μm in diameter; polar capsule 2.7 μm in diameter

Host : *Xenentodon cancila* (Ham.); **site of infection** : gall bladder; **pathogenicity** : not recorded.

Distribution : India : West Bengal (North 24-Parganas district).

Remarks : Tripathi (1952) reported this unnamed species from the gall bladder of the aforesaid host from Belgharia fish farm and his observations are limited to fresh spores. The description is insufficient to establish its species identity.

Family PARVICAPSULIDAE Schulman, 1953

Diagnosis : As in the key.

Key to the genera

1. Spores asymmetrical, thin walled, elongated roughly in sutural plane with unequal valves; sutural line curved; 2 to 4 conspicuously small polar capsules at the apex *Parvicapsula*
2. Spores asymmetrical, elongated with unequal valves; sutural line curved or sinuous; 4 small polar capsules in cross-like arrangement at the apex *Neoparvicapsula*

Genus *Parvicapsula* Schulman, 1953

Diagnosis : As in the key.

93. *Parvicapsula hoffmanni* Padma Dorothy and Kalavati, 1993a
(Fig. 94 a-d)

Diagnosis : Cysts small, opaque white, oval, 125-156 μm x 107-130 μm ; spore broadly oval, anterior end flat, posterior narrow; valves thin, smooth, unequal and curved; large valve convex dorsally and concave ventrally, extending into a blunt lappet-like projection posteriorly; smaller valve located at the concavity of larger valve; sutural line thin, curved, 2 polar capsules, small, pyriform, convergent, located at right angles to each other; polar filament making 4-5 coils while inside the capsule, sporoplasm hyaline, homogenous, 'comma'-shaped.

Size : Spore length 8.5-10.32 (9.4) μm , width 5.6-6.46 (5.89) μm ; polar capsule length 3.0-3.8 (3.46) μm ; polar filament length 13.7-18.9 (15.65) μm .

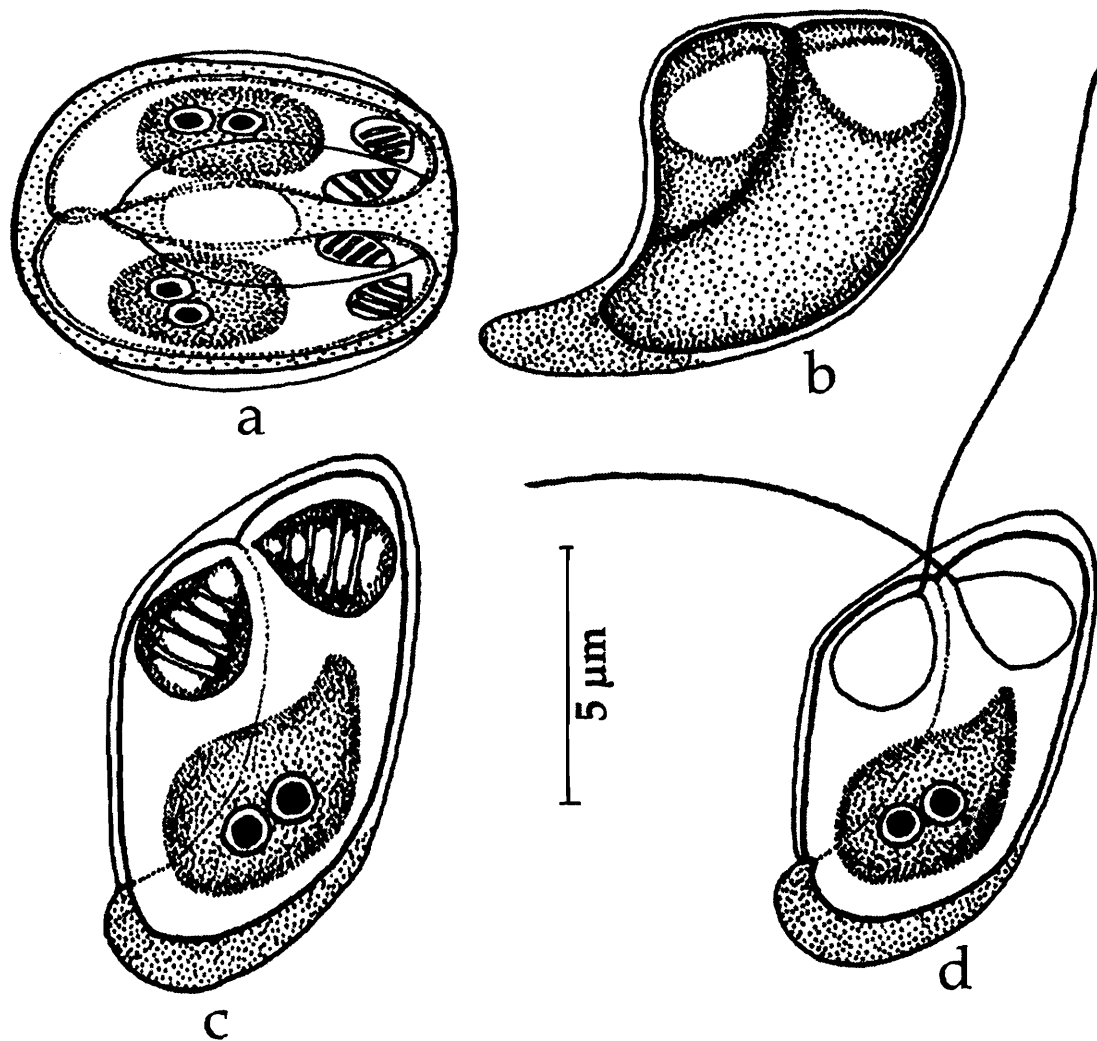


Fig 94. *Parvicapsula hoffmanni* : a. Disporous trophozoite, b. Fresh spore valvular view, c. Spore stained with Giemsa, d. Spore with extruded filaments.

Host : *Liza macrolepis*; *site of infection* : intestine; *pathogenicity* : not reported.

Distribution : India : Andhra Pradesh (Visakhapatnam harbour).

Genus *Neoparvicapsula* Gavaeskaya, Kovaleva and Schulman, 1982

Diagnosis : As in the key.

94. *Neoparvicapsula monolata* Sarkar, 1999b
(Fig. 95a-b)

Diagnosis : Spores elongated, asymmetrical, narrow and round anteriorly, broader, sac-like and round; anterior sphere with small symmetrically arranged 3-4 polar

capsules; suture slightly oblique, very thin; shell valves thin, conical extension on one of the valves seen; sporoplasm granular, homogenous, with a spherical vacuole; no mucous envelop.

Size : Spore length 12.5-16.0 (14.25) μm , width 7.0-10.0 (8.4) μm ; polar capsule length 1.0-2.5 (1.9) μm , width 0.5 -1.2 (0.8) μm .

Host : *Microspinosa cuja* (Ham); *site of infection* : urinary bladder; *pathogenicity* : nephrosis and obstruction of ureter.

Distribution : India : West Bengal (24 Parganas district).

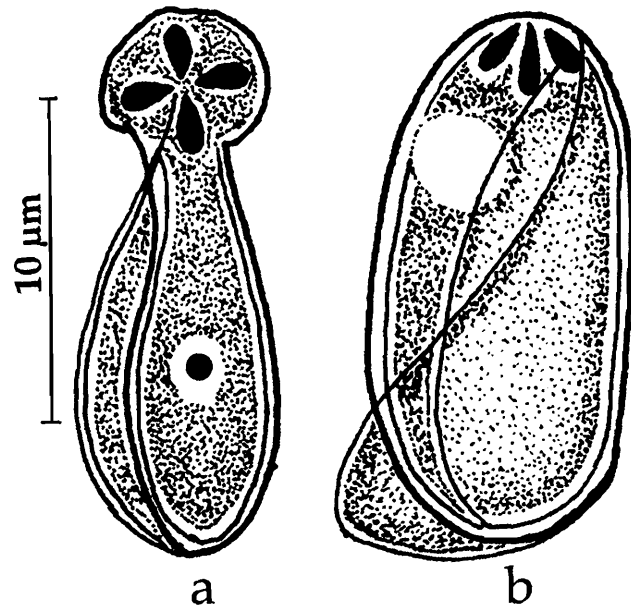


Fig 95. *Neoparvicapsula monolata* : a & b. Spore in different views

Family AUERBACHIDAE Evadakimova, 1973

Diagnosis : As in the key.

Genus *Auerbachia* Meglitsch, 1968

Diagnosis : As in the key.

Key to the species

1. Spores broadly oval, spatula-shaped with a beak-like apex; valves equal; polar capsule pyriform..... *A. chakravartyi*
2. Spores club-shaped; valves unequal; polar capsule elongated*A. chorinemusi*

95. *Auerbachia chakravartyi* Narasimhamurti, Kalavati,
Anuradha, Padma Dorothy, 1990
(Fig. 96 a-b)

Diagnosis : Spores broadly oval, spatula-shaped with a beak-like apex; anterior end pointed, posterior end drawn out into a short, blunt caudal prolongation; valves smooth, thin also covering the caudal prolongation; polar capsule single, pyriform, generally shifted to a side; capsular foramina at the tip of the beak-like extension; polar filament

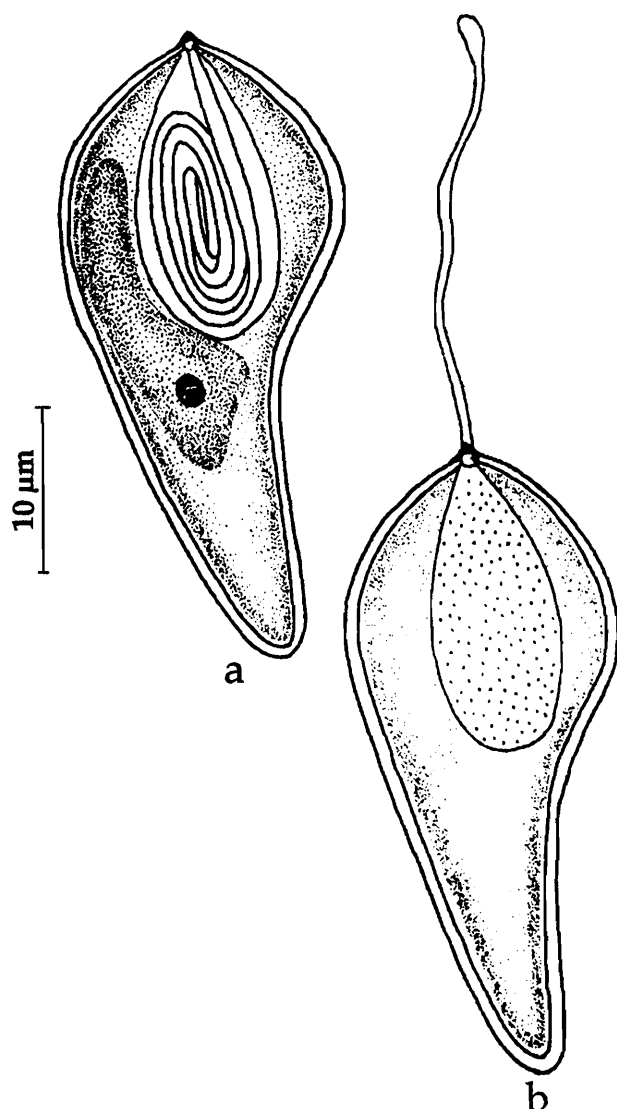


Fig 96. *Auerbachia chakravartyi* : a. Spore stained with Giemsa, b. Spore with extruded polar filament

showing 2 or 3 longitudinal coils while inside the capsule; short and club-shaped when extended; sporoplasm binucleate, posterolateral to the polar capsule, rarely extending into caudal process; sporoplasm uninucleate; iodophilous vacuole absent.

Size : Spore length (total) 14.0-21.0 (17.3) µm; spore body length 8.4-12.6 (10.22) µm, width 7.0-9.8 (7.92) µm; polar capsule length 5.6-9.8 (8.31) µm, width 2.44-4.16 (3.82) µm; polar filament length 18.6-22.8 (20.82) µm.

Host : *Megalaspis cordyla*;
site of infection : gall bladder;
pathogenicity : not reported.

Distribution : India : Andhra Pradesh (Off Kalingapatnam, Bay of Bengal, Srikakulam district)

96. *Auerbachia chorinemusi* Padma Dorothy, Kalavati and Vaidehi, 1998
(Fig. 97 a-c)

Diagnosis : Spores club-shaped; anterior end broadly oval, posterior end narrowly curved into a short, blunt caudal prolongation; valves unequal, smooth, thin also covering the caudal prolongation; polar capsule single, elongated, median and oblique in position; capsular foramina subterminal; polar filament forming 2 or 3 longitudinal coils while inside the capsule; sporoplasm binucleate, homogeneous, filling the entire spore cavity including caudal prolongation; polar filament long, flat ribbon-like with a globular tip.

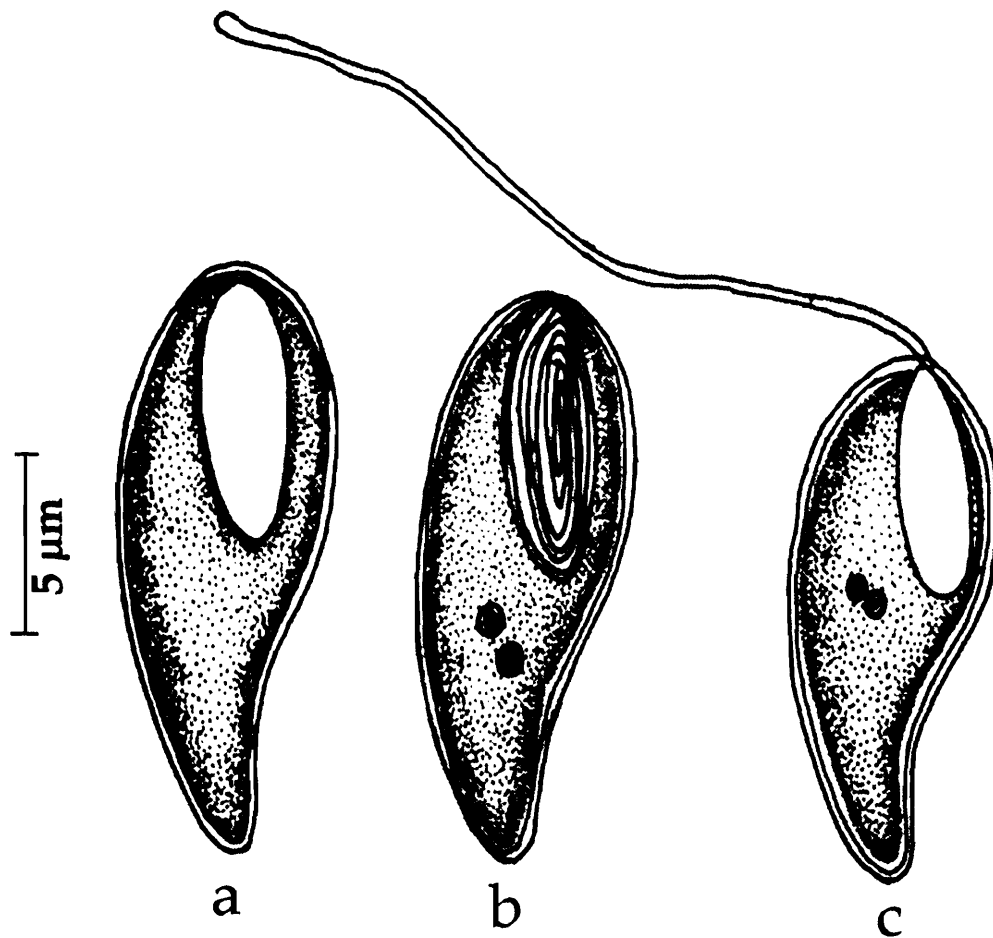


Fig. 97. *Auerbachia chorinemusi* : a. Fresh spore valvular view, b. Spore stained with Giemsa, c. Spore with extruded polar filament

Size : Spore length 15.48-18.0 (16.2) μm , width 6.0-9.46 (7.19) μm ; polar capsule length 7.74-9.46 (8.64) μm , width 3.44-5.16 (3.82) μm .

Host : *Chorinemus* sp; **site of infection :** gall bladder; **pathogenicity :** not reported.

Distribution : India : Andhra Pradesh (Bay of Bengal, off Visakhapatnam, Visakhapatnam district).

Family NEOTHELOHANELLIDAE Sarkar and Misra, 1996

Diagnosis : As in the key.

Remarks : Lom and Dykova 1992 synonymised the two genera *Neothelohanellus* Das and Haldar, 1986 (Family Myxobolidae) and *Lomosporous* Gupta and Khera 1988a, retaining the older name *Neothelohanellus* and abolishing the genus *Lomosporous*. Subsequently Sarkar and Misra 1996 reviewed the status of these two genera and restored both the genera *Neothelohanellus* Das and Haldar, 1986 and *Lomosporous*

Gupta and Khera 1988 as valid and created a new family Neothelohanellidae in the suborder Varisporiina to accommodate the two genera. We propose to follow the same classification for this family.

Key to the genera

1. Spores globular, equal, symmetrical, polar capsule located at an angle to the long axis, opening on the lateral side *Neothelohanellus*
2. Spores oval to ellipsoidal, single polar capsule placed perpendicular to the long axis of the spore opening on the lateral side *Lomosporous*

Genus *Neothelohanellus* Das and Haldar, 1986

Diagnosis : As in the key.

97. *Neothelohanellus catlae* Das and Haldar, 1986 (Fig. 98 a-c)

Diagnosis : Cyst small, round, creamish, 100-160 μm in diameter, polysporous; spores round to ellipsoid; shell valves two, symmetrical, uniformly thick, meeting along the longitudinal sutural line; polar capsule single, pyriform, located angularly to the longitudinal axis; polar filaments forming 8-9 coils while inside, thread-like when extruded; sporoplasm crescentic, binucleate; iodophilous vacuole round.

Size : Spore length 8.2-8.8 (8.5) μm , width 7.7 μm ; polar capsule length 4.4 μm , width 3.3 μm ; polar filament length 77.0-90.2 (82.8) μm .

Host : *Catla catla* (Ham.); *site of infection* : kidney; *pathogenicity* : not apparent.

Distribution : India : West Bengal (Nadia district).




Fig. 98. *Neothelohanellus catlae* : a. Fresh spore valvular view, b. Spore stained with Giemsa, c. Spore with extruded polar filament

Genus *Lomosporous* Gupta and Khera, 1988

Diagnosis : As in the key.

Key to the species

1. Spore oblongate to ellipsoidal, 11-12.1 μm x 7.1-8.2 μm ; polar capsule pyriform *L. krishnagarensis*
2. Spore egg-shaped, 10.0-11.0 μm x 6.0-6.5 μm , polar capsule spherical *L. indicus*

98. *Lomosporous krishnagarensis* (Das and Haldar, 1986) emend. Sarkar and Misra, 1996
(Syn. *Neothelohanellus krishnagarensis* Das and Haldar, 1986)

(Fig. 99 a-c)

Diagnosis : Cyst oblongate, creamy-white, 300-380 μm x 240-280 μm ; spore oblongate to ellipsoidal; shell valves symmetrical, uniformly thick and meeting along the longitudinal sutural line; polar capsule single, pyriform, located perpendicular to the longitudinal axis of the spore; polar filaments forming 5-6 coils while inside the capsule; sporoplasm hemispherical, binucleate; iodophilous vacuole spherical.

Size : Spore length 11.0-12.1 (11.2) μm , width 7.1- 8.2 (7.7) μm ; polar capsule length 5.5 μm , width 4.4 μm ; polar filament length 22.0-42.9 (32.3) μm .

Host : *Labeo calbasu* (Ham.); *site of infection* : fatty matrix of brain; *pathogenicity* : not apparent.

Distribution : India : West Bengal (Nadia district).

Remarks : Sarkar and Misra 1996 while erecting a new family Neothelohanellidae revalidated the two genera *Neothelohanellus* Das and Haldar, 1986 and *Lomosporous* Gupta and Khera 1988 independently. However, while retaining the type species *N. catlae* in the genus *Neothelohanellus*, Sarkar and Misra (op. cit) transferred *Neothelohanellus krishnagarensis* to the genus *Lomosporous*.

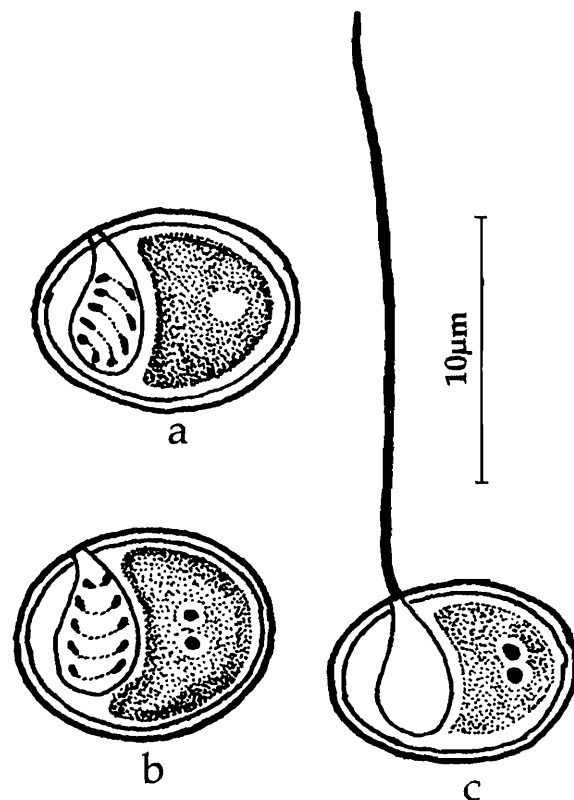


Fig. 99. *Lomosporous krishnagarensis* : a. Fresh spore valvular view, b. Spore stained with Giemsa, c. Spore with extruded polar filament

99. *Lomosporous indicus* Gupta and Khera, 1988a
(Fig. 100 a-b)

Diagnosis : Cyst spherical, milky-white, 0.190 – 0.323 mm x 0.190 – 0.285 mm in size; spore egg shaped; shell valves symmetrical; sutural line straight; polar capsule single, spherical, located at the anterior end at right angles to the long axis of the spore, opening laterally close to the anterior end; extruded polar filaments very thick; sporoplasm uni- or binucleate, occupying the entire extracapsular space; iodophilous vacuole small, spherical.

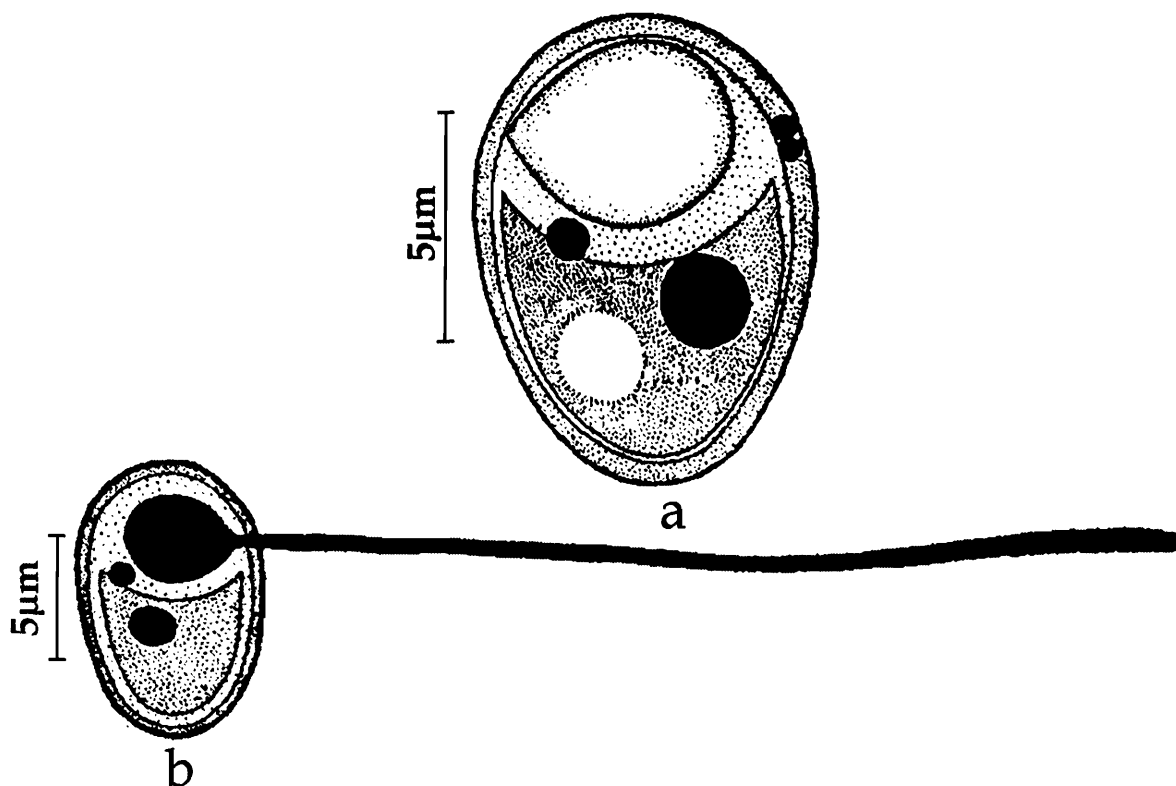


Fig. 100. *Lomosporous indicus* : a. Fresh spore valvular view, b. Spore stained with Giemsa, c. Spore with extruded polar filament

Size : Spore length 10.0-11.0 (10.5) μm , width 6.0-6.5 (6.25) μm ; polar capsule length 4.0-4.5 (4.15) μm , width 4.0-4.5 (4.15) μm ; polar filament length 31.0-44.0 μm .

Host : *Labeo calbasu* (Ham.); *site of infection* : gills and operculum; *pathogenicity* : not apparent.

Distribution : India : Punjab (Harike, Ropar).

Remarks : As mentioned earlier Sarkar and Misra (1996) reestablished the genus *Lomosporous* Gupta and Khera (1988) and retained the name *Lomosporous indicus* as the type species.

Suborder PLATYSPORINA Kudo, 1919, emend. Lom and Noble, 1984

Family MYXOBOLIDAE Thelohan, 1892

Diagnosis : Spore flattened parallel to the straight sutural line forming an elevated ridge drawn out into long projections; one of the polar capsules sometimes smaller; most species have an 'iodinophilous vacuole'; as a rule forming large histozoic trophozoites (cysts) with numerous spores

Remarks : Lom and Noble (1984) reduced the genus *Myxosoma* Thelohan, 1892 and synonymised it with genus *Myxobolus* Butschli, 1882. Accordingly they suppressed the family Myxosomatidae.

Key to the genera

1. Spores without any caudal projections 3
2. Spore with caudal appendages or projections 4
- 3.1 Spores ellipsoid, oval or rounded in valvular view and biconvex in sutural view; shell valves smooth; sutural line straight; two mostly pyriform polar capsules, sometimes one missing; sporoplasm binucleate often with iodophilous vacuole; histozoic; trophozoite large, polysporous with pansporoblast formation Genus *Myxobolus*
- 3.2 Spores pyriform, tear-shaped or ellipsoid in valvular view; tear-shaped or pyriform in sutural view; shell valves smooth; single pyriform, tear-shaped, sub-spherical polar capsule; binucleate sporoplasm mostly with spherical polysaccharide inclusion; trophozoites large, polysporous with pansporoblast formation Genus *Thelohanellus*
- 4.1 Spores rounded or ellipsoid or spindle-shaped in valvular view, biconvex in sutural view; both the valves continue as caudal projections, which sometimes opposed; shell valves smooth; 2 elongated polar capsules; sporoplasm binucleate with spherical polysaccharide inclusion; histozoic; trophozoites large, polysporous with pansporoblast formation Genus *Henneguya*
- 4.2 Spores spindle-shaped in valvular view; flattened spindle in sutural view; two fine equal prolongations both at anterior and posterior ends; polar capsules spherical, tandem in position at a distance from the anterior end; sporoplasm with polysaccharide reserves in the form of a spherical inclusion Genus *Neohenneguya*
5. Spores with single or bifurcated caudal appendage 6
- 6.1 Spore with single caudal appendage, not as a continuation of shell valves; caudal appendage adherent to spore; polar capsules 2, pyriform; histozoic Genus *Unicauda*

- 6.2 Spores flattened, pyriform, caudal appendage independent, bifurcated and fitted to the posterior end of the spore; single, elongated polar capsule; sporoplasm binucleate with spherical polysaccharidal inclusion; trophozoites large, polysporous; histozoic Genus *Phlogospora*

Genus *Myxobolus* Butschli, 1882
(Syn. *Myxosoma* Thelohan, 1892)

Diagnosis : As in the key.

Key to the Species

1. Polar capsule equal 4
2. Polar capsules unequal 5
3. Polar capsules either equal or unequal
 - 3.1 Spores pyriform; valves thick; polar capsules pyriform, subterminal; when equal occupying half the length of the spore; inhabiting *Catla-Rohu* hybrid
..... *M. manoramae*
 - 3.2 Spores elongated or pyriform; valves symmetrical, thin; polar capsules pyriform, when equal, occupying 2/3 the length of the spore; inhabiting *Catla - Rohu* hybrid *M. rocatlae*
 - 3.3 Spores ovoidal or tear-shaped; valves symmetrical, smooth; polar capsules ovoid to pyriform with long neck; inhabiting *Catla-Rohu* hybrid. *M. shantipuri*
 - 3.4 Valves thick, smooth; polar capsules pyriform; intercapsular ridge small, triangular; spore 8.0–10.0 μm x 7.0–9.0 μm *M. vanivilasae*
 - 3.5 Spore variable in shape and size; valves symmetrical, smooth; polar capsules spherical to ovoidal *M. multivaderis*
- 4.1 Spore spherical
 - 4.1.1 Valves with wavy parallel striations, symmetrical, double-walled, inner thick and outer thin; 3 parietal folds on either side; polar capsules oval; spore 8.0-11.0 (9.0) μm in diameter; 2 iodophilous vacuoles *M. bivacuolatus*
 - 4.1.2 Valves symmetrical; polar capsules equal, pyriform; spore 6.1 – 7.1 (6.6) μm x 5.7-6.5 (6.2) μm *M. calcariferum*
 - 4.1.3 Valves moderately thick and smooth; polar capsules pyriform; spore 10.5–11.5 (10.7) μm x 9.0–10.0 (9.4) μm *M. edellae*

- 4.1.4 Valves thick with several triangular markings; polar capsules pyriform; spore 7.21-8.24 μm in diameter *M. mrigalae*
- 4.1.5 Valves smooth; polar capsules pyriform, terminal; spore 4.8-5.2 (5.1) μm in diameter with 2 mucous protuberances *M. mugcephalus*
- 4.1.6 Valves smooth; polar capsules pyriform, convergent; spore 6.0-7.3 (6.74) μm in diameter *M. sphaeralis*
- 4.1.7 Valves thick; polar capsules circular; spore 9.66 μm x 8.05 μm *M. rewensis*
- 4.2 Spore sub-spherical
- 4.2.1 Valves comparatively thick, equal; polar capsules pyriform with their ends drawn into a short narrow tube; spore 11.3-12.4 μm x 10.3 μm *M. clarii*
- 4.2.2 Valves smooth, with 2-3 triangular folds; polar capsule, pyriform; spore 10.5-14 μm x 8.2-11.5 μm *M. eeli*
- 4.2.3 Valves smooth with 6-9 triangular markings in the posterior margin; spore 10.0-12.0 μm x 9.0-11.0 μm *M. cartilaginis*
- 4.3 Spore pyriform
- 4.3.1 Valves thin, smooth; polar capsules pyriform, equal, convergent; spore 8.8-11.2 (10.59) μm x 4.8-6.72 (6.28) μm *M. bhadurius*
- 4.3.2 Valves thin; polar capsule pyriform; spore 14.5-16.5 μm x 6.18 μm .. *M. catlae*
- 4.3.3 Single valve, thick; polar capsules circular with a distinct neck, convergent; a thread-like structure connecting 2 equal polar capsules; spore 9-10 μm x 8-8.5 μm *M. crucifilus*
- 4.3.4 Valves uniformly thick, polar capsules equal, pyriform, with a thickened notch in between; spore 13.0-21.1 (17.04) μm x 4.9-8.1 (6.48) μm *M. cuttacki*
- 4.3.5 Valves equal with 4-6 ridges at the posterior end; polar capsules pyriform, sub-terminal with small inter-capsular space; spore 9.3-11.5 (10.1) μm x 5.0-8.0 (5.9) μm *M. hyderabadense*
- 4.3.6 Valves thin, equal; polar capsules pyriform; spore 16.32-19.04 (17.58) μm x 10.88-13.6 (11.1) μm *M. karnatakae*
- 4.3.7 Valves thin, smooth, polar capsules elongated, tubular; spore 12.0-17.5 (14.37) μm x 2.5-5.0 (4.23) μm *M. maruliensis*
- 4.3.8 Valves symmetrical; smooth, polar capsules pear-shaped; spore 10.0-11.0 (10.8) μm x 7.5-9.5 (8.6) μm *M. rigida*

- 4.3.9 Valves thin, smooth; polar capsules pyriform, arranged parallel to each other; spore 14.0-17.0 (15.55) μm x 8.7-9.85 (9.35) μm *M. trichogasteri*
- 4.4 Spore ellipsoid
- 4.4.1 Valves smooth, symmetrical; polar capsules 2, equal, broadly pyriform with short neck; inter capsular appendix sub-terminal, triangular; spore 9.8 – 11.06 (10.74) μm x 7.92- 9.84 (8.69) μm *M. anili*
- 4.4.2 Valves thick; polar capsules pyriform, equal with moderately long tubular neck, placed in a pericapsular space; spore 12.8-15.2 (13.89) μm x 7.5 -9.6 (8.53) μm *M. attui*
- 4.4.3 Valves thick, smooth; polar capsules narrow, elongated, banana-shaped, parallel to each other occupying more than half the spore cavity; spore 13.0-15.00 (14.13) μm x 6.5-8.0 (7.75) μm *M. magurii*
- 4.5 Spore oval
- 4.5.1 Valves smooth; polar capsules flask-shaped with tilted neck region, subterminal; inter capsular ridge absent; spore 8.6-10.7 (9.8) μm x 6.4-7.9 (7.1) μm
..... *M. ampullaceus*
- 4.5.2 Valves smooth; polar capsules small, pyriform; inter capsular ridge absent; spore 10.0-11.0 (10.6) μm x 8.0-9.0 (8.7) μm *M. bankimi*
- 4.5.3 Valves thick; polar capsules pyriform; inter capsular ridge small; spore 12.6-13.5 μm x 9.0 μm *M. barbi*
- 4.5.4 Valve thick, smooth; sutural ridge broad prominent with four thickenings; polar capsules pyriform; inter capsular ridge present; spore 9.6-11.2 μm x 7.2-8.8 μm *M. batae*
- 4.5.5 Valve smooth; polar capsule equal, oval; inter capsular ridge absent; spore 8.56-9.36 μm x 6.42-6.80 μm *M. bengalensis*
- 4.5.6 Valves thick; polar capsules pyriform equal, rarely slightly unequal; inter capsular ridge present; spore 8.0-11.0 (9.8) μm x 7.0 -8.0 (7.6) μm
..... *M. crumucae*
- 4.5.7 Valves uniformly thick except at the anterior end between the capsular foramen; polar capsules pyriform; distinct inter capsular notch present; spore 11.4-19.5 (14.1) μm x 4.9-8.1 (6.4) μm *M. dasgupti*
- 4.5.8 Valves relatively thick and smooth; polar capsules pyriform; distinct inter capsular appendix present; spore 9.0-11.0 (10.3) μm x 8.0-10.0 (9.4) μm
.....*M. dermatis*

- 4.5.9 Valves smooth with short wing-like out growths at the posterior end; polar capsules generally 2, rarely 3 equal, pyriform; spore 10.2–14.5 (12.2) μm x 8.5–11.9 (10.5) μm *M. etroplici*
- 4.5.10 Valves considerably elevated; polar capsules pear-shaped, parallel; spore 9.0–12.0 (10.28) μm x 6.2–8.5 (7.44) μm x 5.0–6.0 (5.20) μm *M. fossilii*
- 4.5.11 Valves thick, smooth; polar capsules pyriform; spore 11.0–14.0 (12.6) μm x 9.0–11.0 (9.6) μm *M. indirae*
- 4.5.12 Valves symmetrical with 5 widely spaced diagonal striations extending between lateral walls; polar capsules pyriform; intercapsular ridge absent; spore 5.2–6.9 (6.28) μm x 4.3–6.9 (5.26) μm *M. macrolepi*
- 4.5.13 Valves thick, smooth; polar capsules pyriform; inter capsular ridge spine-like between the polar capsules; spore 8.0–9.5 (8.8) μm x 6.0–7.5 (6.96) μm *M. meglitschus*
- 4.5.14 Valves moderately thick, smooth; polar capsules broadly pyriform with a very distinct anterior long neck; inter capsular appendix short and sharply pointed; spore 8.5–9.5 (9.0) μm x 7.0–8.5 (7.4) μm *M. molae*
- 4.5.15 Valves uniformly thick; polar capsules equal, pyriform; inter capsular ridge absent; spore 8.1–16.3 μm x 4.0–7.3 μm *M. mugilii*
- 4.5.16 Valves thin; polar capsules sub-terminal, pear-shaped; spore 12.5–13.5 (12.8) μm x 8.6–9.5 (9.0) μm *M. narasii*
- 4.5.17 Valves thick, with short, blunt posterior extension; polar capsules pyriform; spore 11.5–14.3 (12.7) μm x 8.3–10.5(9.5) μm *M. noblei*
- 4.5.18 Valves smooth, polar capsules pyriform, opening independently; inter capsular ridge absent; spore 6.0–12.0 μm x 6.0–9.0 μm *M. nodularis*
- 4.5.19 Valves smooth; polar capsules pear-shaped; spore 9.0–9.5 (9.1) μm x 8.0–8.5 (8.1) μm *M. parsi*
- 4.5.20 Valves thin, smooth; polar capsules equal, slightly pyriform; spore 6.0–7.0 (6.3) μm x 4.5–6.0 (4.8) μm *M. parvus*
- 4.5.21 Valves equal, with markings on posterior margin; polar capsules oval with prominent ducts; spore 6.3–7.9 (7.2) μm x 4.3–6.4 (5.4) μm *M. potaili*
- 4.5.22 Valves thick with a triangular notch at the anterior end; polar capsules pear-shaped, opening independently separated by notch; spore 9.9–12.1(10.6) μm x 8.8–9.9 (9.0) μm *M. rohita*

- 4.5.23 Valves smooth, symmetrical; polar capsules ovoidal, equal and convergent; spore 8.0-9.0 (8.8) μm x 7.0-8.0 (7.4) μm *M. shetti*
- 4.5.24 Valves striated; polar capsules pyriform, sub-terminal; spore 10.6-13.6 (11.5) μm x 9.6-11.2 (10.5) μm *M. spinocurvatura*
- 4.5.25 Valves smooth; polar capsules oval, opening independently; spore 9.8-10.2 (10.1) μm x 12.0-13.5 (13.0) μm *M. tripathii*
- 4.5.26 Valves moderately thick, smooth; polar capsules spherical, convergent; spore 9.0-9.5 μm x 7.2 μm *M. yogindrai*
- 4.5.27 Valves thick, smooth; polar capsules oval or pyriform, convergent; spore 6.9-8.6 (7.74) μm x 5.6-6.5 (6.02) μm *Myxobolus* sp.
- 4.6 Spore pear shaped
- 4.6.1 Valves smooth, refractile, double layered, inner thick and outer thin; polar capsules unequal and dissimilar; large capsule pyriform, subterminal; smaller polar capsule rudimentary, terminal, non-functional; spore 11.2-12.4 (11.8) μm x 6.8-7.2 (7.0) μm *M. esomi*
- 4.6.2 Valves thick, smooth, no parietal folds; polar capsules pyriform; spore 8.0-9.7 (8.4) μm x 5.1-6.1 (5.4) μm *M. chinsurahensis*
- 4.6.3 Valves smooth, equal; polar capsules pear-shaped with long neck parallel to each other; a characteristic deeply stained dot seen at the site of capsular foramina; spore 4.6-5.2 (4.9) μm x 9.0-9.5 (9.3) μm *M. lizae*
- 4.7 Spore cylindrobiconical
- 4.7.1 Valves striated with 6-8 longitudinal striations; polar capsules equal, pyriform, with a very short neck at the conical end of the spore; spore 12.8-16.32 (14.37) μm x 4.48-6.4 (4.91) μm x thickness 3.2-3.52 (3.41) μm *M. cylindricus*
- 4.8 Spore egg-shaped
- 4.8.1 Narrow anteriorly with a small protruberance in valvular view; valves smooth, symmetrical; polar capsules pyriform, equal, convergent; spore 9.0-10.0 (9.75) μm x 7.0-8.0 (7.15) μm *M. venkateshi*
- 4.9 Spore variable in shape
- 4.9.1 Spores oval to circular; valves smooth; inter capsular ridge indistinct; spore 7.4-9.7 μm x 7.0-10.0 μm *M. cerebralis*

5. 1 Spore pyriform

- 5.1.1 Valves thick, symmetrical; polar capsules pyriform; spore 12-14 μm x 6-75 μm *M. aligarhensis*
- 5.1.2 Valves equal with 4-6 ridges at the posterior end; polar capsules pyriform, sub terminal; one of the capsules often curved; spore 12.1-15.7 (13.5) μm x 5.7-8.6 (6.4) μm *M. andhrae*
- 5.1.3 Valves moderately smooth; polar capsules pyriform, unequal; inter capsular ridge in the form of a thickening; spore 8.0-11.0 (9.5) μm x 7.0-8.0 (7.14) μm
..... *M. bhadrensis*
- 5.1.4 Valves smooth, thick; parietal folds absent; polar capsules dissimilar; spore 11.6-12.7 (12.1) μm x 6.4-8.1 (7.1) μm*M. buccoroofus*
- 5.1.5 Valves smooth, thin; polar capsule pyriform, unequal; spore 20.0-21.8 (20.4) μm x 15.7-17.1 (16.3) μm *M. catmrigalae*
- 5.1.6 Valves thin, smooth; polar capsules unequal, convergent; large capsule pyriform, subterminal; smaller capsule pyriform with a small neck, deeply stained terminal, non-functional; spore 7.2- 8.0 (7.77) μm x 5.6-6.6 (6.2) μm *M. chilkenis*
- 5.1.7 Valves uniformly thick; polar capsules pyriform; spore 8.3-14.9 (10.6) μm x 4.1-8.4 (5.49) μm *M. coeli*
- 5.1.8 Valves thin anteriorly, thick at the posterior end; polar capsules 2-3 in number, pyriform opening independently; spore 12.4 -15.0 (13.7) μm x 6.4 -8.6 (7.3) μm*M. indiae*
- 5.1.9 Valves thin, smooth; polar capsules pyriform; inter capsular ridge absent; spore 8.7-23.5 μm x 5.1-10.1 μm *M. mathuri*
- 5.1.10 Valves thin anteriorly and thick posteriorly; 2-5 parietal folds in the posterior region; polar capsules unequal; larger capsule pyriform, smaller capsule tear-shaped; spore 10.8-11.3 (10.8) μm x 7.6-8.1 (7.9) μm *M. mrigalhitae*
- 5.1.11 Valves thin; polar capsules pyriform; spore 12.23-13.96 (13.18) μm x 8.73-10.47 (9.39) μm *M. mystusius*
- 5.1.12 Valves unequal, smooth; polar capsules unequal; larger polar capsule wide, elongated, pyriform with rounded posterior and nipple-like anterior end; smaller polar capsule oval or tear-shaped; spore 12.4-13.97 (13.13) μm x 7.45- 9.18 (8.04) μm *M. ophthalmasculata*

- 5.1.13 Valves symmetrical, thick; inter capsular appendix present, polar capsules pyriform, spore 13.0–19.5 (15.71) μm x 4.9–8.1 (6.8) μm *M. orissae*
- 5.1.14 Spores bent to one side; valves uniformly thick with 8–10 parietal folds; polar capsules, pyriform with prominent neck; inter capsular ridge absent; spore 12.4–15.0 (13.5) μm x 7.1–10.0 (8.6) μm *M. osmaniae*
- 5.1.15 Valves symmetrical, uniform; polar capsules unequal elongated, pyriform, sub terminal; spore 8.0–11.4 (9.6) μm x 6.5–7.9 (7.0) μm *M. pinnaurati*
- 5.1.16 Valves small asymmetrical, with two striations, one on either side of the sutural line and 3–4 parietal folds; polar capsules elongated, pyriform with short neck; intercapsular ridge prominent; spore length 9.3–10.7 (10.0) μm x 8.6–10.0 (9.4) μm *M. psilorhynchi*
- 5.1.17 Valves thick, with a thickened notch at the anterior end; polar capsules unequal, pyriform; inter-capsular ridge absent; spore 11.4–17.9 (14.0) μm x 4.0–8.1 (5.3) μm *M. scatophagi*
- 5.1.18 Valves thick; polar capsules unequal, pyriform with blunt anterior end; spore size variable in different organs *M. variformis*
- 5.2 Spore oval
- 5.2.1 Valves moderately thick; polar capsules pyriform; spore 12.4–15.0 μm x 8.2–10.0 μm *M. calbasui*
- 5.2.2 Valves thick; sutural ridge plain; intercapsular ridge present; polar capsules oval with bluntly tapering anterior end; spore 8.0–9.0(8.6) μm x 6.0–7.0(6.8) μm ...
..... *M. carnaticus*
- 5.2.3 Valves symmetrical, uniform; inner wall forming a triangular thickening; polar capsule pyriform; spore 12.1–14.3 (12.3) μm x 7.7–10.5 μm
..... *M. chakravartyi*
- 5.2.4 Valves smooth, equal; polar capsules elongate, pear-shaped; spore 14.5–18.0 (17.2) μm x 6.0–6.5 (6.3) μm *M. channi*
- 5.2.5 Valves thin, smooth; polar capsules unequal, one narrow and the other broad, pyriform, terminal; inter-capsular appendix present; spore 6.0–7.6 (7.2) μm x 5.16–5.84 (5.6) μm *M. episcuammalis*
- 5.2.6 Valves considerably elevated; polar capsules pyriform, convergent; spore 11.2–17.3 (13.7) μm x 8.1–12.2 (9.5) μm *M. filamentosus*
- 5.2.7 Valves striated with 6–8 striations on each valve; polar capsules pyriform, convergent; spore 8.0–10.5 (8.73) μm x 4.8–6.5 (5.03) μm *M. gangulii*

- 5.2.8 Valves thin, smooth with 6 sutural marks; polar capsules markedly unequal, pyriform; spore 9.5-10.5 (9.7) μm x 6.0-7.5 (6.6) μm *M. goensis*
- 5.2.9 Valves symmetrical; intercapsular ridge triangular; polar capsules oval with a small distinct neck; spore 9.0-10.0 (9.31) μm x 7.0-8.5 (7.95) μm
..... *M. haldari*
- 5.2.10 Valves smooth; polar capsules pyriform, convergent; spore 9.0-11.0 (10.5) μm x 5.0 – 8.0 (6.25) μm *M. hosadurgensis*
- 5.2.11 Valves moderately thick, smooth; polar capsules unequal and divergent; longer one pyriform, smaller one more or less spherical; spore 9.5-10.8 μm x 7.5-8.2 μm *M. indicum*
- 5.2.12 Valves thin, transparent, with 6–8 parietal markings on posterior margin; polar capsules unequal, one very small, pyriform; spore 7.1–9.6 (8.4) μm x 5.0–6.4 (6.0) μm *M. koli*
- 5.2.13 Valves symmetrical; inter-capsular ridge triangular; polar capsules pyriform; spore 9.0–11.0 (10.0) μm x 8.0–9.0 (8.4) μm *M. lalithae*
- 5.2.14 Valves smooth; inner wall of the valves showed a triangular projection at the anterior end; polar capsules pear-shaped; spore 10.8–11.7 (11.2) μm x 8.3–10.0 (9.2) μm *M. magauddi*
- 5.2.15 Valves symmetrical; inter capsular ridge absent; polar capsules pyriform; spore 6.0–9.0 (7.72) μm x 6.0–7.0 (6.2) μm *M. saranae*
- 5.2.16 Valves smooth, symmetrical and moderately thick; polar capsule unequal, convergent, oval; spore 6.4-7.0 μm x 4.5-5.0 μm *M. saranaei*
- 5.2.17 Valves thin in the anterior half, thick posteriorly, polar capsules large, ovoid, slightly unequal with small ducts; inter-capsular ridge prominent; spore 11.4-12.9 (12.21) μm x 8.6-10.0 (9.04) μm *M. seshadri*
- 5.2.18 Valves thick, smooth, symmetrical; polar capsules oval, convergent; spore 6.4-26.6 (14.9) μm x 5.9-10.1 (7.7) μm *M. sophorae*
- 5.2.19 Valves moderately smooth, symmetrical; polar capsules ovoidal, unequal, convergent; smaller capsule pyriform, larger one ovoidal; inter-capsular process large, triangular; spore 13.0-15.0 (13.8) μm x 8.0–10.0 (9.2) μm
..... *M. vedavatiensis*
- 5.3 Spore cylindrobiconical
- 5.3.1 Valves smooth, refractile, double layered; polar capsules unequal and dissimilar; large capsule pyriform, subterminal; spore 11.52–13.96 (12.7) μm x 9.77–10.47 (9.2) μm *M. mahendrae*

100. *Myxobolus aligarhensis* Bhatt and Siddiqui, 1964
 (Syn. *Myxobolus ophicephali* Bhatt and Siddiqui, 1964;
Myxobolus punctatus Ray Chaudhuri and Chakravarty, 1970)
 (Fig. 101 a-c)

Diagnosis : Cyst rounded, milky-white, 0.190-0.628 mm 0.192-0.533 mm; spore pyriform, gradually tapering, anterior end bluntly pointed, posterior end rounded; valves thick, symmetrical; sutural line and sutural ridge straight; polar capsules two, pyriform, unequal (excepting those parasitic in heart muscle, Mukherjee and Haldar, 1981); polar filament thread-like, unequal in length; sporoplasm filling the extracapsular cavity; iodophilous vacuole present.

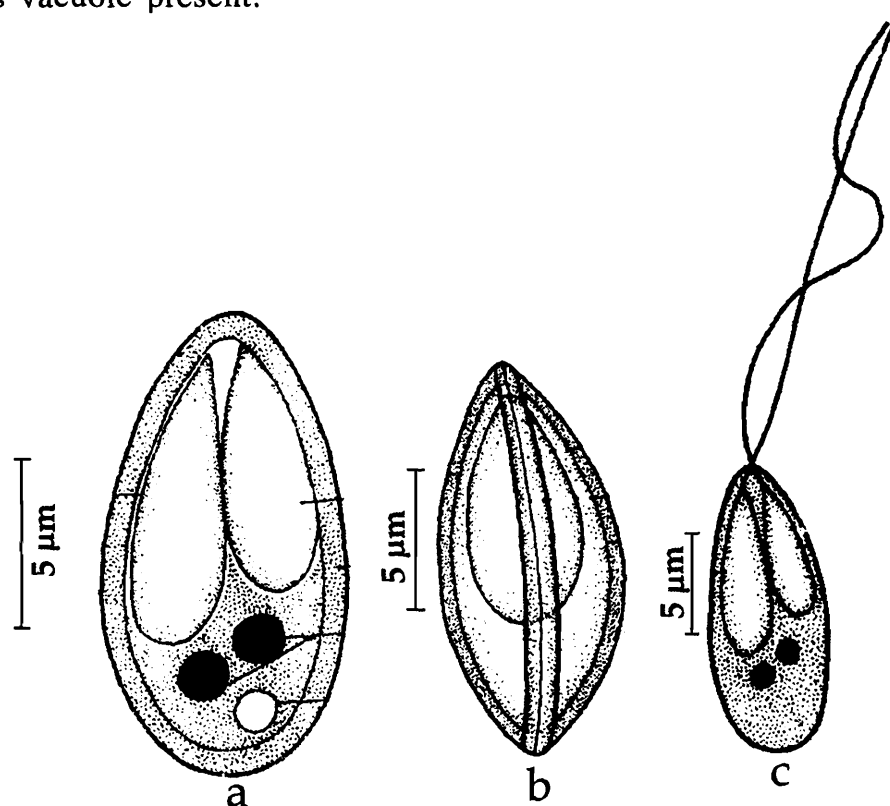


Fig. 101. *Myxobolus aligarhensis* : a. Fresh spore valvular view, b. Spore stained with Giemsa, c. Spore with extruded polar filament

Size : Spore length 12-14 μm , width 6-7.5 μm ; polar capsule (large) length 6.5-8 μm , width 2-2.5 μm ; polar capsule (small) length 6-7 μm , width 2.5 μm ; polar filament length (long) 38.45 μm , (short) 32 μm .

Host : *Channa* (= *Ophicephalus*) *punctatus* Bloch; **site of infection** : accessory respiratory membrane, pharyngeal epithelium and fins; **pathogenicity** : not recorded.

Distribution : India; West Bengal (Calcutta, Nadia and North 24-Parganas districts), Punjab and Uttar Pradesh.

Remarks : Bhatt and Siddiqui (1964) described 2 species, namely, *Myxobolus aligarhensis* and *M. ophicephali* from *Ophicephalus punctatus*. Ray Chaudhuri and

Chakravarty (1970) described another species, *Myxobolus punctatus* from the same host. Later on, Mukherjee and Haldar (1981a) observed this species *M. punctatus* from different organs of *Ophicephalus punctatus* collected from fish ponds around Kalyani University Campus, Nadia, West Bengal and reported morphological variability in spore dimensions. Gupta and Khera (1988b) while reviewing the genus *Myxobolus* treated both *Myxobolus punctatus* Ray Choudhuri and Chakravarty, 1970, and *M. ophicephali* Bhatt and Siddiqui, 1964 as synonyms of *M. aligarhensis* since all the three species has spores of comparable size and the species is known to exhibit variability in spore morphometrics and are recorded from the same host. The present authors agree with this proposition and retain the name *M. aligharensis* abolishing *M. punctatus* and *M. ophicephali* as junior synonyms.

101. *Myxobolus ampullaceus* Lalitha Kumari, 1969
(Fig. 102 a-c)

Diagnosis : Trophozoites whitish, small; spores oval with slightly compressed sides; anterior end narrower than the posterior; shell valves thin, symmetrical, uniformly thick with markings on posterior margin; polar capsules 2, equal, flask-shaped with tilted neck region, subterminal; intercapsular ridge absent; polar filaments forming 5-6 tight coils while inside the capsule, tubular when extended; sporoplasm granular, homogenous, located behind the polar capsule; iodophilous vacuole large, oval or spherical.

Size : Spore length 8.6–10.7 (9.8) μm , width 6.4–7.9 (7.1) μm ; polar capsule length 5–6.4 (5.8) μm , width 2.5–2.9 (2.8) μm .

Host : *Barbus kolus*; **site of infection** : dorsal and ventral fins; **pathogenicity** : not recorded.

Distribution : India : Andhra Pradesh (Local market in Hyderabad).

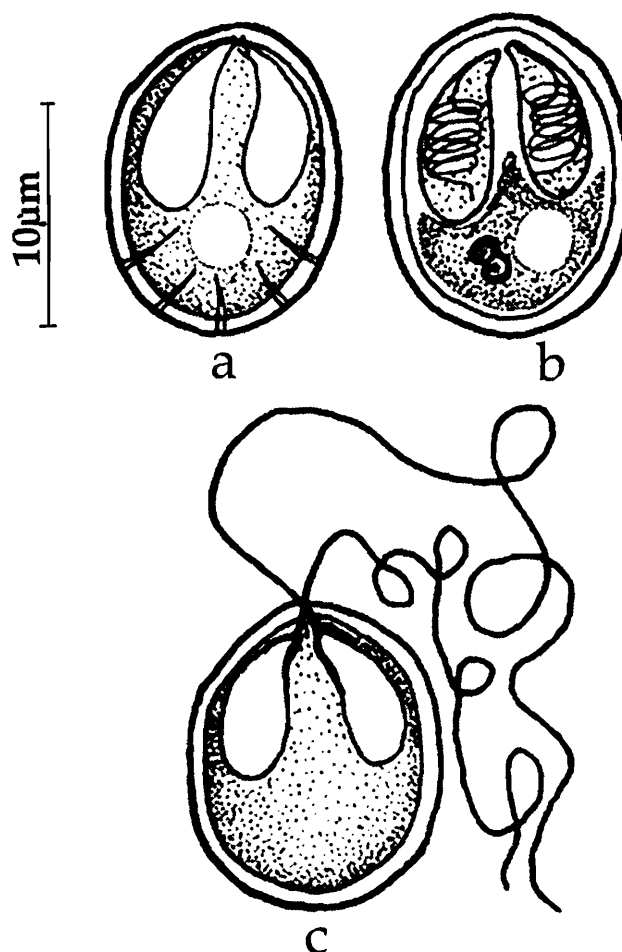


Fig. 102. *Myxobolus ampullaceus* : a. Fresh spore valvular view, b. Spore stained with Giemsa, c. Spore with extruded polar filament

102. *Myxobolus andhrae* (Lalitha Kumari, 1969) emend. Gupta and Khera, 1988b
(Syn. *Myxosoma andhrae* Lalitha Kumari, 1969)
(Fig.103 a-c)

Diagnosis : Trophozoites about 1.0 mm in diameter; pansporoblast disporous; spores pyriform or ellipsoidal; anterior end narrow, blunt, posterior end rounded with 3-6 parietal folds, sometimes drawn out into an appendage; shell valves equal with 4-6 ridges at the posterior end; sutural ridge broad at the posterior region, narrows down anteriorly; sutural line median and straight; polar capsules 2, unequal, pyriform, subterminal and one of the capsules often curved; polar filaments equal, forming 9 coils

within the capsule; sporoplasm granular, homogenous extending into inter capsular space up to anterior pole; iodophilous vacuole absent.

Size : Spore length 12.1-15.7 (13.5) μm , width 5.7-8.6 (6.4) μm ; polar capsule (large) length 8.6-10.0 (9.0) μm , width 1.4- 2.1 (1.7) μm ; polar capsule (small) length 7.1-9.3 (8.3) μm , width 1.4-2.1 (1.7) μm ;

Host : *Channa* (= *Ophicephalus*) *punctatus*; **site of infection :** surface wall of the intestine; **pathogenicity :** not recorded.

Distribution : India : Andhra Pradesh : (Hyderabad city).

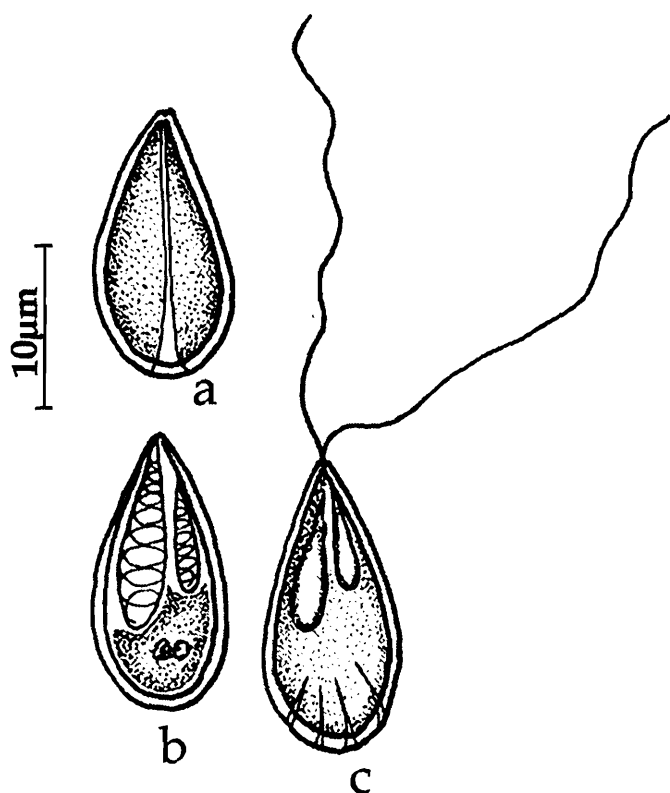


Fig. 103. *Myxobolus andhrae* : a. Fresh spore valvular view, b. Spore stained with Giemsa, c. Spore with extruded polar filament

103. *Myxobolus anili* Sarkar, 1989
(Fig. 104 a-c)

Diagnosis : Trophozoites oval, cream-coloured, 560-615 μm x 206-288 μm ; spores broadly ellipsoidal in valvular view, characteristically angular and lenticular in sutural view; anterior end slightly acuminate; shell valves smooth, symmetrical; sutural ridge broad, thick; polar capsules 2, equal, broadly pyriform with short neck, convergent; intracapsular appendix subterminal, triangular; polar filaments forming 4-5 coils while inside the capsule; sporoplasm binucleate, filling the extracapsular spore cavity, iodophilous vacuole absent.

Size : Spore length 9.8–11.06 (10.74) μm ; width 7.92–9.84 (8.69) μm ; polar capsule length 4.74–5.05 (4.82) μm ; width 2.48–3.16 (3.05) μm ; polar filament length 20.0 μm .

Host : *Rhinomugil corsula* (Hamilton), *Liza macrolepis*; **site of infection** : mesentery associated with duodenum, intestinal villi; **pathogenicity** : not recorded.

Distribution : India : West Bengal (North 24 – Parganas district); Andhra Pradesh : (Bheemunipatnam, Visakhapatnam district).

Remarks : In the species encountered by Padma Dorothy and Kalavati (1992) in *L. macrolepis*, the spores are considerably smaller in size (spore length 8.6–10.3 (9.55) μm ; width 6.9–8.6 (7.83) μm ; polar capsule length 2.58–3.44 (3.33) μm ; width 1.7–2.6 (2.52) μm). Keeping in view the morphological variabilities exhibited by *Myxobolus* species, Padma Dorothy and Kalavati preferred to identify the species as *M. anili*.

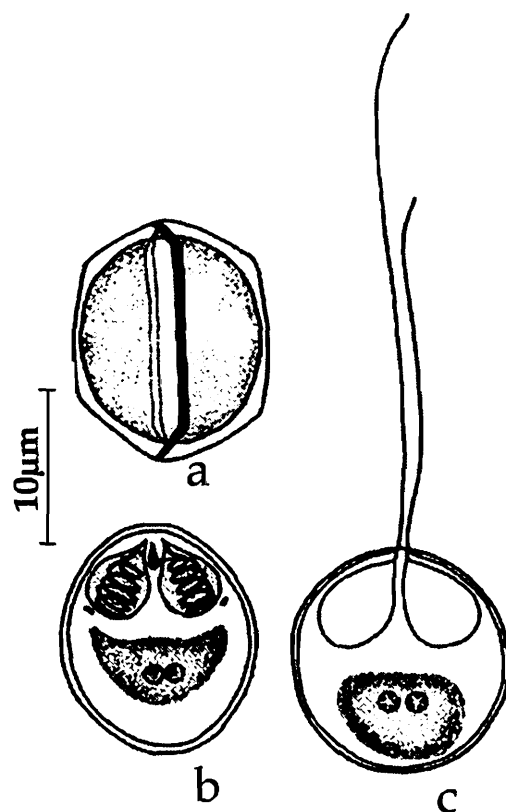


Fig. 104. *Myxobolus anili* : a. Fresh spore valvular view, b. Spore stained with Giemsa, c. Spore with extruded polar filament

104. *Myxobolus attui* Sarkar, 1985a
(Fig.105 a-c)

Diagnosis : Spore ellipsoidal or oval in valvular view, lenticular to fusiform in sutural view; anterior end slightly compressed; shell valves thick; sutural line thick, slightly

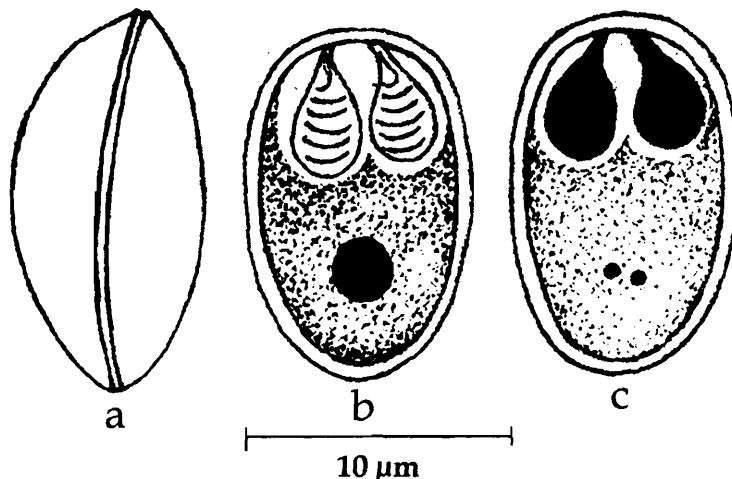


Fig. 105. *Myxobolus attui* : a. Fresh spore valvular view, b. Spore treated with iodine, c. Spore stained with Giemsa

curved; polar capsules pyriform, placed in a pericapsular space, equal with moderately long tubular neck; polar filament making 6-7 coils while inside the capsule; sporoplasm finely granular, binucleate, filling most of the extracapsular cavity; iodophilous vacuole spherical.

Size : Spore length 12.8-15.2 (13.89) μm , width 7.5-9.6 (8.53) μm ; polar capsule length 4.8-7.2 (5.92) μm , width 2.4-4.0 (3.0) μm ;

Host : *Wallago attu* (Bleeker); *site of infection* : gut; *pathogenicity* : not apparent

Distribution : India : West Bengal (east bank of Padma River).

105. *Myxobolus bankimi* Sarkar, 1999b
(Fig.106 a-d)

Diagnosis : Spores oval in valvular view, lenticular in sutural view; shell valves symmetrical, thick and smooth; sutural line broad, straight; polar capsules small, equal, pyriform, widely placed; polar filament making 4-6 coils while inside the capsule; no intercapsular ridge or spine; sporoplasm binucleate; small iodophilous vacuole present; no mucous envelop.

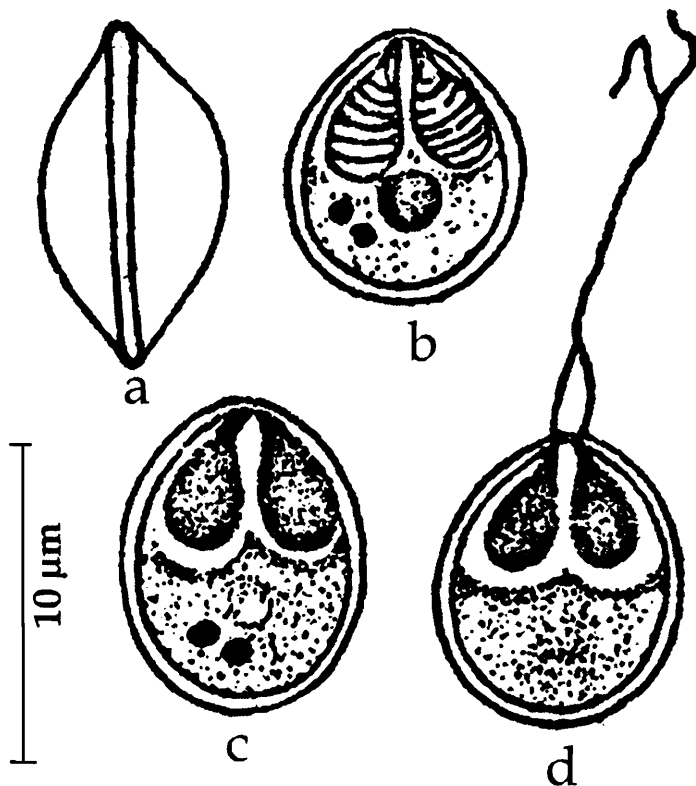


Fig. 106. *Myxobolus bankimi* : a. Fresh spore sutural view, b. Spore treated with iodine, c. Spore stained with Giemsa, d. Spore with extruded polar filament

Size : Spore length 10.0-11.0 (10.6) μm , width 8.0-9.0 (8.7) μm ; polar capsule length 3.5-4.5 (3.97) μm , width 2.5-3.0 (2.72) μm .

Host : *Sicamugil cascasia* (Ham); *site of infection* : inner wall of gall bladder; *pathogenicity* : not apparent.

Distribution : India : West Bengal (24 Parganas District).

106. *Myxobolus barbi* Tripathi, 1952
(Fig.107 a-b)

Diagnosis : Spore perfectly oval in front view, lenticular in side and anterior view; shell valves thick; sutural ridge prominent, sutural line indistinct; polar capsules pyriform, equal and convergent; small intracapsular ridge present; capsulogenous nuclei small, located at the posterior end of the capsule; sporoplasm filling most of the extracapsular cavity; iodophilous vacuole round.

Size : Spore length 12.6-13.5 μm , width 9.0 μm ; polar capsule length 3.6-4.5 μm , width 2.7 μm .

Host : *Barbus ticto* (Ham.); **site of infection :** skin; **pathogenicity :** not apparent.

Distribution : India : West Bengal (North 24 – Parganas district).

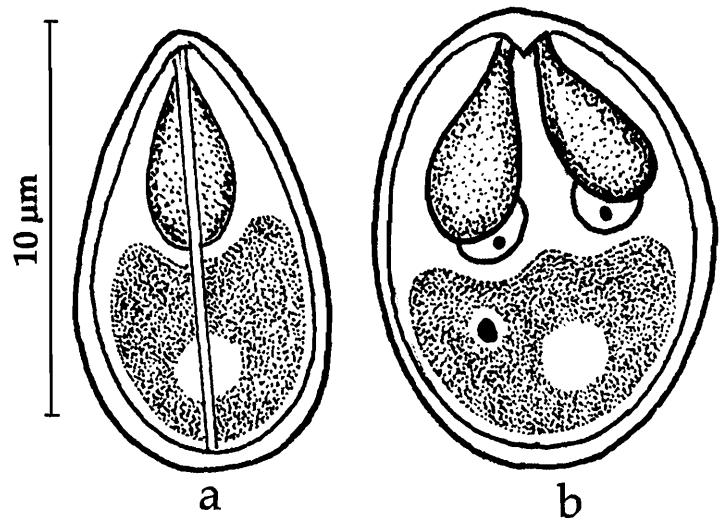


Fig. 107. *Myxobolus barbi* : a. Fresh spore sutural view, b. Spore valvular view

107. *Myxobolus batae* Karamchandani, 1970
(Fig.108 a-b)

Diagnosis : Cyst spherical to cylindrical, milky white, 1.5 mm in size; spores oval in valvular view and lenticular in lateral view; shell valves thick, smooth, symmetrical; sutural ridge broad prominent with four thickenings; polar capsules pyriform, equal, convergent; intercapsular ridge present; sporoplasm uninucleate; iodophilous vacuole occupying the posterior part.

Size : Spore length 9.6-11.2 μm , width 7.2-8.8 μm , thickness 4.8 μm ; polar capsule length 4.0-4.8 μm , width 1.6 μm .

Host : *Labeo bata* (Hamilton); **site of infection :** gill filaments; **pathogenicity :** not apparent.

Distribution : India; Orissa (Cuttack).

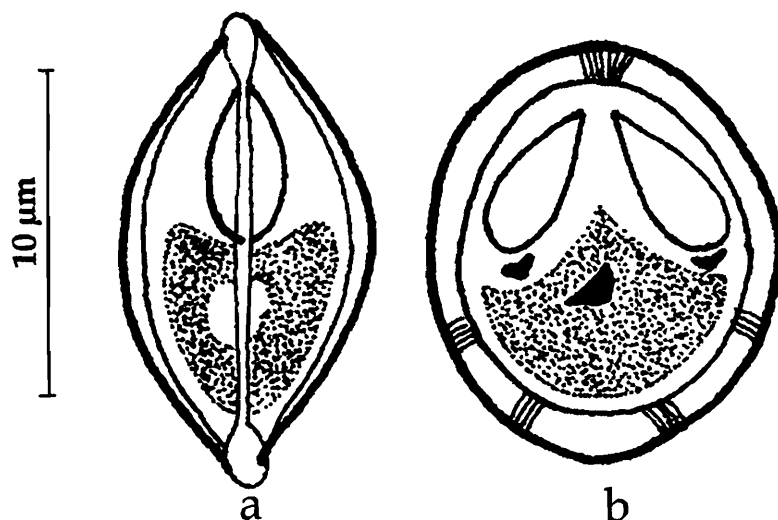
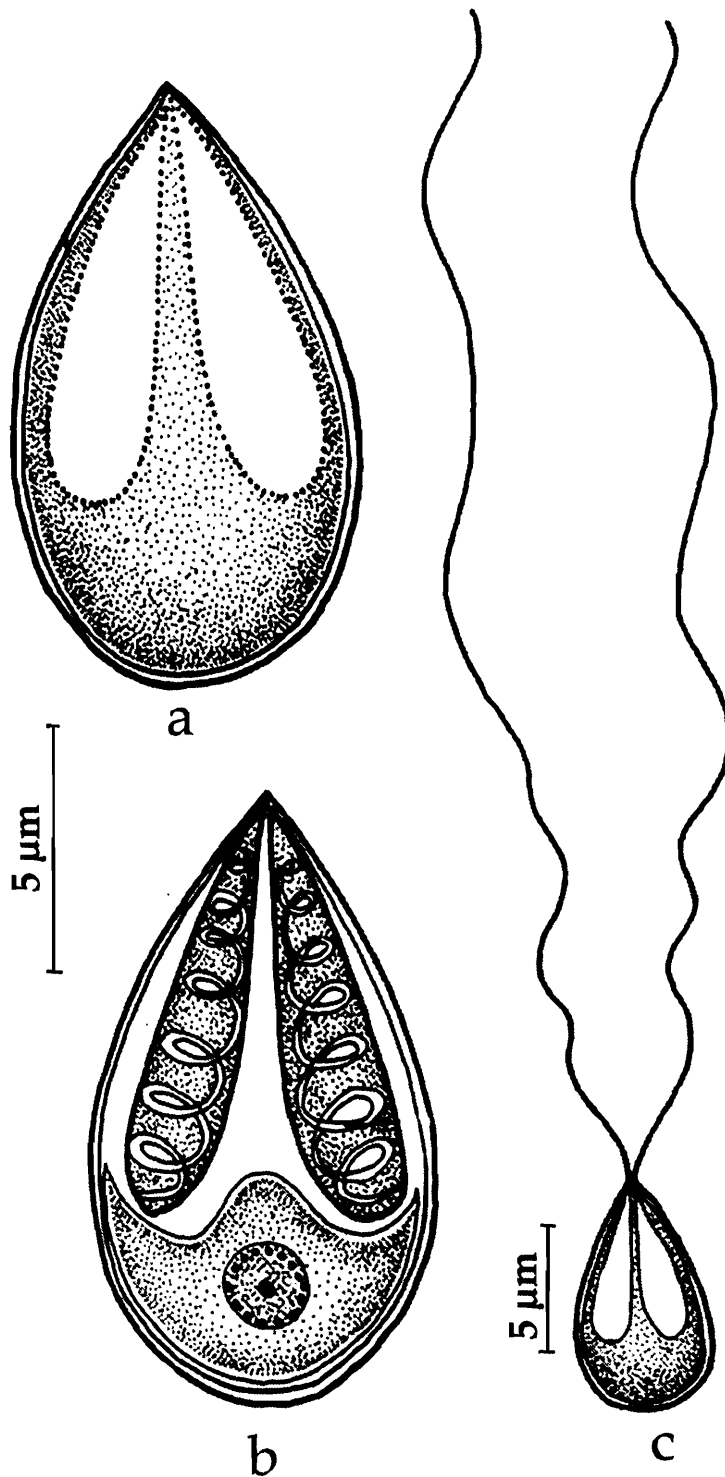


Fig. 108. *Myxobolus batae* : a. Fresh spore sutural view, b. Spore valvular view

108. *Myxobolus bengalensis* Chakravarty and Basu, 1948
(Fig. 109 a-c)



Diagnosis : Trophozoites oval, 2-4.1 mm in diameter; spore more or less oval in front view spindle - shaped in side view; anterior end bluntly pointed with a small knob, posterior end rounded; shell valve smooth; sutural ridge prominent; sutural line indistinct; polar capsule equal, oval; polar filament long; iodophilous vacuole spherical.

Size : Spore length 8.56-9.36 μm , width 6.42-6.80 μm ; polar capsule length 4.28-5.40 μm , width 2.5 μm x 3.2 μm ; polar filament length 50-125 μm .

Host : *Catla catla* (Ham); **site of infection** : gills; **pathogenicity** : not apparent.

Distribution : India : West Bengal (North 24-Parganas district), Andhra Pradesh (Tanks near Chilakaluripeta, Guntur district).

Fig. 109. *Myxobolus bengalensis* : a. Fresh spore valvular view, b. Spore stained with Giemsa, c. Spore with extruded polar filament

109. *Myxobolus bhadrensis* Seenappa and Manohar, 1981
(Fig. 110)

Diagnosis : Spore elongately oval in valvular view, lenticular in sutural view; shell valves moderately smooth; sutural ridge not clear; polar capsules pyriform, unequal, convergent; inter capsular ridge in the form of a thickening; sporoplasm coarse, uninucleate, filling the extracapsular cavity; iodophilous vacuole present.

Size : Spore length 8.0-11.0 (9.5) μm , width 7.0-8.0 (7.14) μm ; polar capsule (large) length 3.0-4.0 (3.5) μm , width 2.0-3.0 (2.2) μm ; polar capsule (small) length 2.0-4.0 (2.5) μm , width 1.0- 2.0 (1.75) μm .

Host : *Labeo rohita* (Ham.); **site of infection :** muscle; **pathogenicity :** not apparent.

Distribution : India : Karnataka (Fish seed ponds at Bhadra).

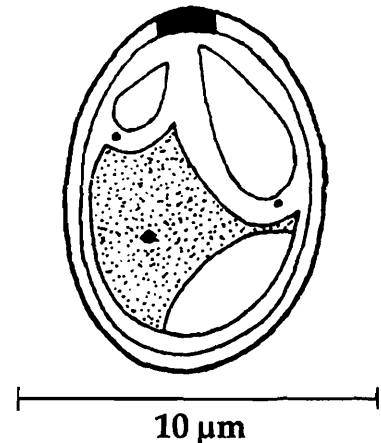


Fig. 110. *Myxobolus bhadrensis*
: a. Spore valvular view

110. *Myxobolus bhadurius* (Sarkar, 1985a) emend. Gupta and Khera, 1988b
(Syn. *Myxosoma bhaduria* Sarkar, 1985a)
(Fig. 111 a-c)

Diagnosis : Spore pyriform in valvular view, lenticular in sutural view; anterior end broadly pointed, posterior end round; shell valves thin, smooth; sutural line thin; polar capsules pyriform, equal, convergent; polar filament making 5-6 coils while inside the capsule; sporoplasm coarse, binucleate, filling the extracapsular cavity; iodophilous vacuole absent.

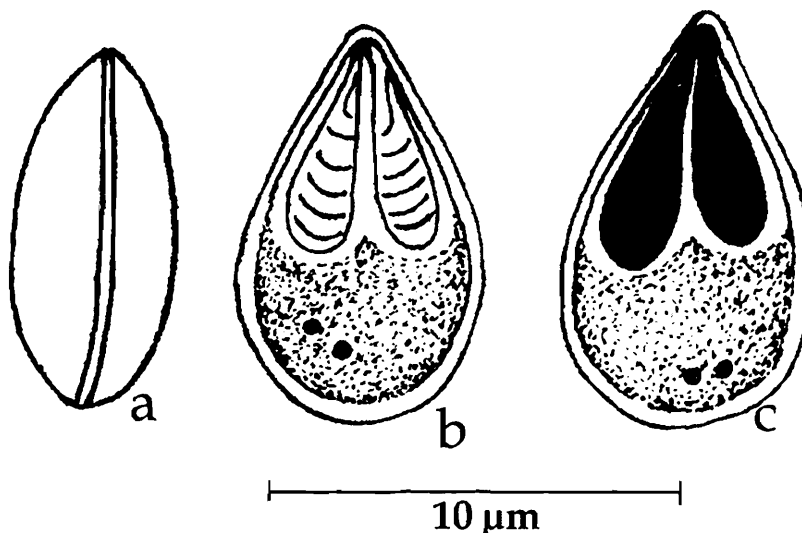


Fig. 111. *Myxobolus bhadurius* : a. Fresh spore valvular view, b. Spore stained with Giemsa, c. Spore treated with iodine

Size : Spore length 8.8-11.2 (10.59) μm , width 4.8-6.72 (6.28) μm ; polar capsule length 4.0-6.4 (5.31) μm , width 2.4-3.2 (2.78) μm ;

Host : *Wallago attu* (Bleeker); *site of infection* : gall bladder; *pathogenicity* : not apparent.

Distribution : India : West Bengal (east bank of Padma River).

Remarks : Gupta and Khera (1988b) while changing the species of *Myxosoma* described earlier to the genus *Myxobolus*, emended this species as *Myxobolus bhadhuria*. Landsberg and Lom 1991 further changed it to *Myxobolus bhadhurius* since the specific name is incorrect.

111. *Myxobolus bivacuolatus* Narasimhamurti and Kalavati, 1986
(Fig. 112 a-d)

Diagnosis : 'Cysts'/ trophozoites amber coloured, translucent, oval, 4.0-6.0 mm x 2.0-3.0 mm; spores spherical; shell valves with wavy parallel striations, symmetrical, double walled; inner wall thick, outer thin; sutural ridge wavy with 3 parietal folds on either side; polar capsules oval, equal, open independently; polar filament making 6-7 coils while inside the capsule, thick and broad when extended; sporoplasm bowl-shaped, homogenous; iodophilous vacuoles 2 in number, 1.8-2.0 μm in diameter seen on either side of sporoplasm.

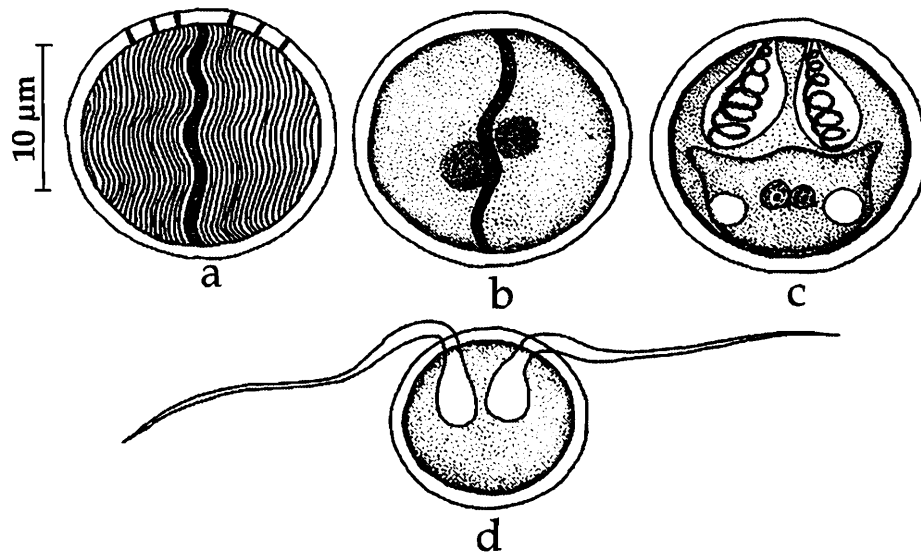


Fig. 112. *Myxobolus bivacuolatus* : a. Spore surface view, b. Spore sutural view, c. Spore stained with Giemsa, d. Spore with extruded polar filament

Size : Spore 8.0-11.0 (9.0) μm in diameter; polar capsule length 3.0-4.5 (4.2), width 2.6-4.0 (3.0) μm ; polar filament length 18-24 (22.5) μm

Host : *Clarius batrachus*; *site of infection* : intestinal wall; *pathogenicity* : not apparent.

Distribution : India : Andhra Pradesh (Eluru, West Godavari district).

112. *Myxobolus buccoroofus* Basu and Haldar, 2004
(Fig. 113 a-c)

Diagnosis : 'Cyst' minute; spores pyriform, anterior end narrow, bent side-wise; shell valves smooth, thick; parietal folds absent; sutural ridge indistinct; polar capsules unequal, dissimilar in shape; larger capsule opening anteriorly and the polar filament forming 6-8 coils inside the capsule; smaller capsule opening laterally and the filament making 4-5 coils inside the capsule; mucous envelop thick; sporoplasm binucleate filling the entire extracapsular spore cavity; iodophilous vacuole large.

Size : Spore length 11.6–12.7 (12.1) μm , width 6.4–8.1 (7.1) μm ; polar capsule (large) length 4.5–5 (4.9) μm , width 2.7–3.0 (2.9) μm ; polar capsule (small) length 2.0–2.9 (2.5) μm , width 1.3–1.7 (1.5) μm .

Host : *Labeo bata* (Hamilton); **site of infection :** roof of buccal cavity; **pathogenicity :** not apparent.

Distribution : India : West Bengal (Hooghly river).

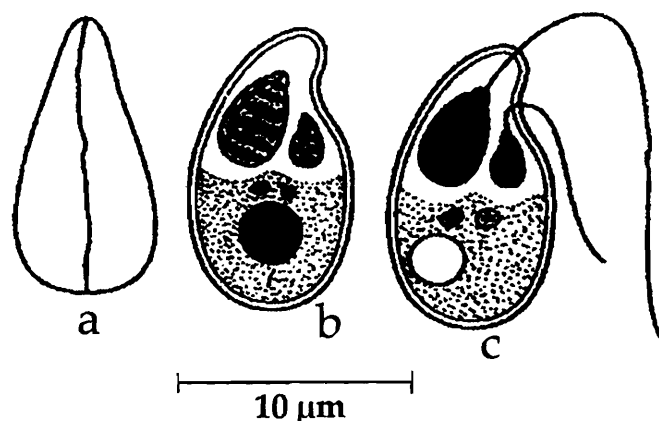


Fig. 113. *Myxobolus buccoroofus* : a. Fresh spore valvular view, b. Spore stained with Giemsa, c. Spore with extruded polar filament

113. *Myxobolus calbasui* Chakravarty, 1939
(Fig. 114 a-c)

Diagnosis : Cyst almost spherical, 300-350 μm in diameter; young trophozoites spherical or slightly oval, 30 μm in diameter; spore roughly oval in front view, lenticular

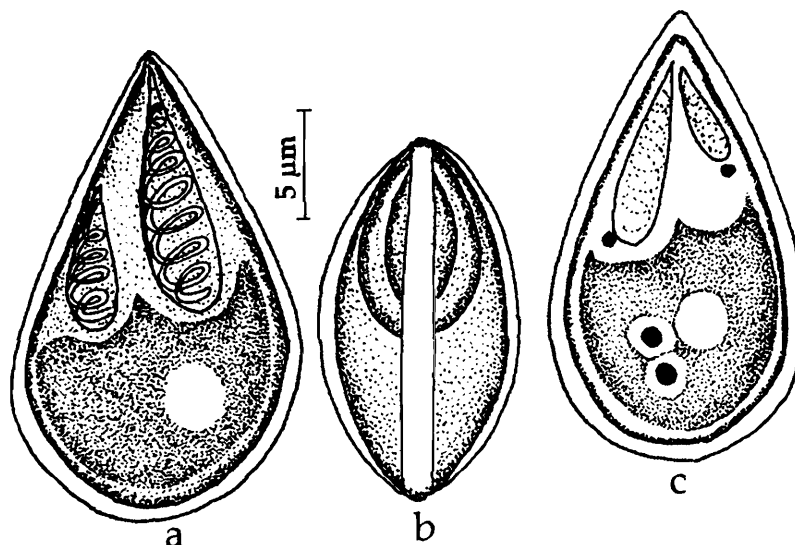


Fig. 114. *Myxobolus calbasui* : a. Fresh spore valvular view, b. Fresh spore sutural view, c. Spore stained with Giemsa

in lateral view; anterior extremity pointed, posterior end rounded; shell valves moderately thick, symmetrical; sutural ridge distinct; polar capsules pyriform, unequal; polar filament well marked inside the capsule in fresh spores, unequal in size when extruded; sporoplasm granular, binucleate, single, spherical; iodophilous vacuole present.

Size : Spore length 12.4–15.0 μm , width 8.2–10.0 μm ; polar capsule (large) length 6.18 μm , width 4.12 μm ; polar capsule (small) length 4.12 μm , width 3.09 μm ; polar filament (long) length 125 μm , polar filament (short) length 60 μm .

Host : *Labeo calbasu* (Ham.), *L. rohita* (Ham) and *Cirrhina mrigala* (Ham); *site of infection* : gall bladder; *pathogenicity* : not apparent.

Distribution : India : West Bengal (Calcutta district).

Remarks : Ray (1933) reported this species from liver of *Cirrhina mrigala* (Ham.).

114. *Myxobolus calcariferum* Basu and Haldar, 2003a
(Fig. 115 a-c)

Diagnosis : Spore spherical, yellowish in colour in fresh condition; shell valves symmetrical; sutural ridge median; polar capsules equal, pyriform; polar filament making 4-5 loose spiral coils inside each capsule; sporoplasm granular, binucleate, extending into inter capsular space; iodophilous vacuole absent.

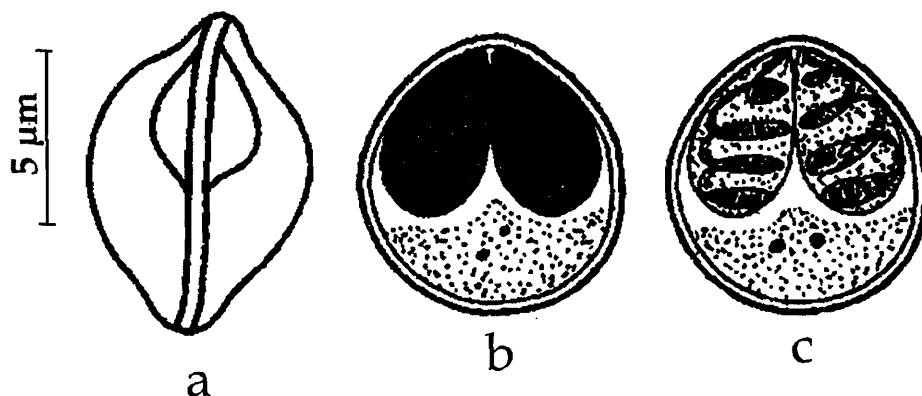


Fig. 115. *Myxobolus calcariferum* : a. Fresh spore sutural view, b. Spore treated with iodine, c. Spore stained with Giemsa

Size : Spore length 6.1–7.1 (6.6) μm , width 5.7–6.5 (6.2) μm ; polar capsule length 3.8–4.5 (4.2) μm , width 2.0–2.7 (2.3) μm .

Host : *Lates calcarifer*; *site of Infection* : gill filaments; *pathogenicity* : not apparent

Distribution : India, West Bengal (Naihati, North 24 Parganas district).

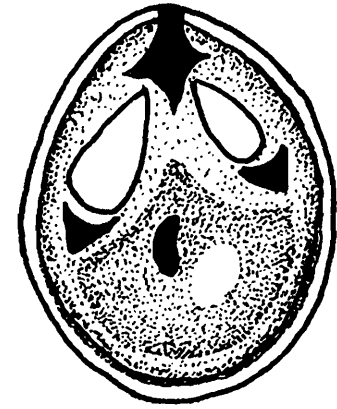
115. *Myxobolus carnaticus* Seenappa and Manohar, 1980a
(Fig. 116)

Diagnosis : Spore oval in valvular view and lenticular in sutural view; shell valves thick; sutural ridge plain and intercapsular ridge present; polar capsules oval with bluntly tapering anterior end, unequal; sporoplasm uninucleate filling the entire spore cavity; iodophilous vacuole present.

Size : Spore length 8.0–9.0 (8.6) μm , width 6.0–7.0 (6.8) μm , thickness 5.0–6.0 (5.3) μm ; polar capsule (large) length 3.5–4.0 (3.8) μm , width 2.0 μm ; polar capsule (small) length 2.0–3.0 (2.1) μm , width 1.0–2.0 (1.5) μm .

Host : *Cirrhina mrigala*; **site of infection :** gills (branchiales); **pathogenicity :** not apparent

Distribution : India : Karnataka (Tungabhadra dam canal).



10 μm
Fig. 116. *Myxobolus carnaticus* :
Spore valvular view

116. *Myxobolus cartilaginis* Hoffman, Putz and Dunbar, 1965
(Fig. 117 a-d)

Diagnosis : Spore subspherical in valvular view, broadly lenticular in sutural view; shell valves symmetrical with 6–9 indistinct triangular markings at the posterior margin; sutural ridge narrow; intercapsular ridge triangular; polar capsules broadly pyriform,

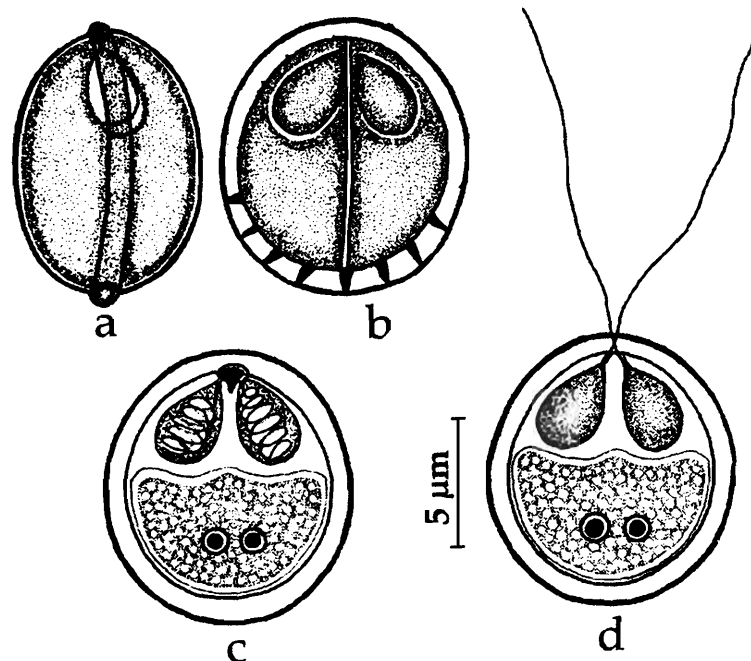


Fig. 117. *Myxobolus cartilaginis* : a. Fresh spore sutural view, b. Spore valvular view, c. Spore stained with Giemsa, d. Spore with extruded polar filament

equal with very short convergent ducts; polar filament forming 5–7 coils while inside the capsule; sporoplasm large, granular, filling the entire spore cavity; iodophilous vacuole absent.

Size : Spore length 10.0–12.0 (10.8) μm , width 9.0–11.0 (9.5) μm , thickness 6.0–7.0 (6.1) μm ; polar capsule length 5.0–6.0 (5.3) μm , width 3.0–4.0 (3.1) μm .

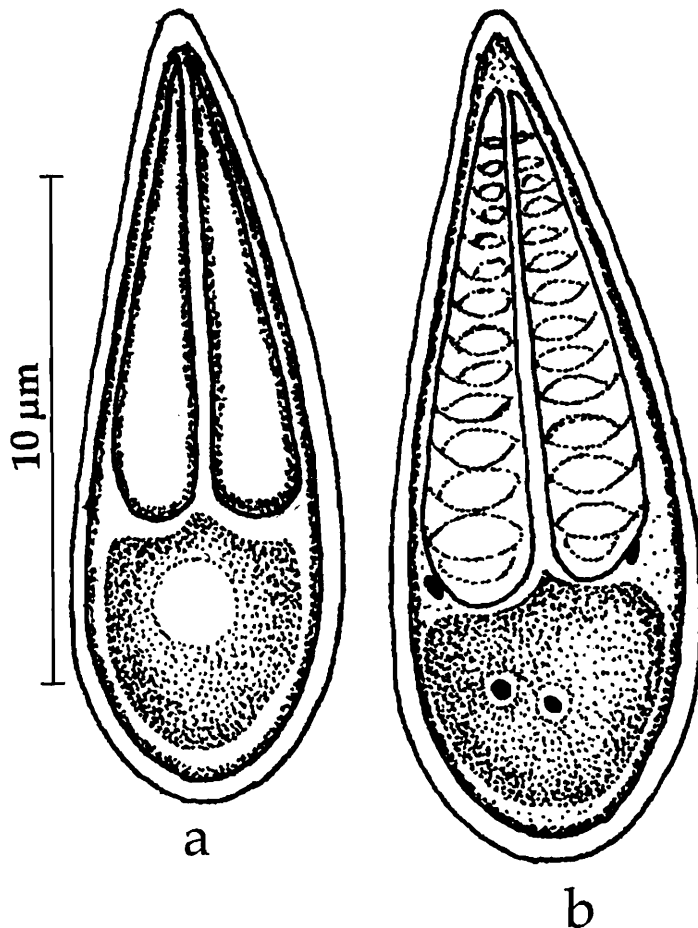
Host : *Lepomis macrochirus*, *Micropterus salmoides*; *site of infection* : gills- cartilage of the branchial arches and base of finrays ; *pathogenicity* : liquefaction of the cartilage.

Distribution : India : Haryana (Sonapat); *elsewhere* : United States.

Remarks : Ram *et al.* (1984) reported the occurrence of this species in major carps, minor carps and murels in Haryana, India.

117. *Myxobolus catlae* Chakravarty, 1943

(Fig. 118 a-c)



Diagnosis : Cyst opaque white, spherical or oval, 45–150 μm in largest diameter; spore elongately pyriform in front view, spindle-shaped in lateral view; anterior end sharply pointed, posterior end round; shell valves thin; sutural ridge and line indistinct; polar capsule elongated pyriform, equal; polar filament short.

Size : Spore length 14.5–16.5 μm , width 6.18 μm ; polar capsule length 10.3–12.36 μm , width 2.06–3.01 μm ; polar filament length 10 μm .

Host : *Catla catla* (Ham.), *Labeo rohita* (Ham.) and *Cirrhinus mrigala* (Ham.); *site of infection* : gills; *pathogenicity* : not apparent.

Distribution : India : West Bengal (Calcutta district).

Fig. 118. *Myxobolus catlae* : a. Fresh spore valvular view, b. Spore stained with Giemsa

118. *Myxobolus catmrigalae* Basu and Haldar, 2004
(Fig. 119 a-d)

Diagnosis : 'Cyst' creamy white, spherical or oval; spore elongately pyriform or large tear-shaped in valvular view, lenticular in sutural view; anterior end pointed, posterior end broadly rounded; shell valves smooth, thin; sutural line thin, straight; polar capsule pyriform, unequal; polar filament making 20-25 coils while inside the larger capsule; 20-23 coils in smaller capsule; sporoplasm granular, binucleate, homogenous and filling the entire spore cavity; iodophilous vacuole absent; no mucous envelope.

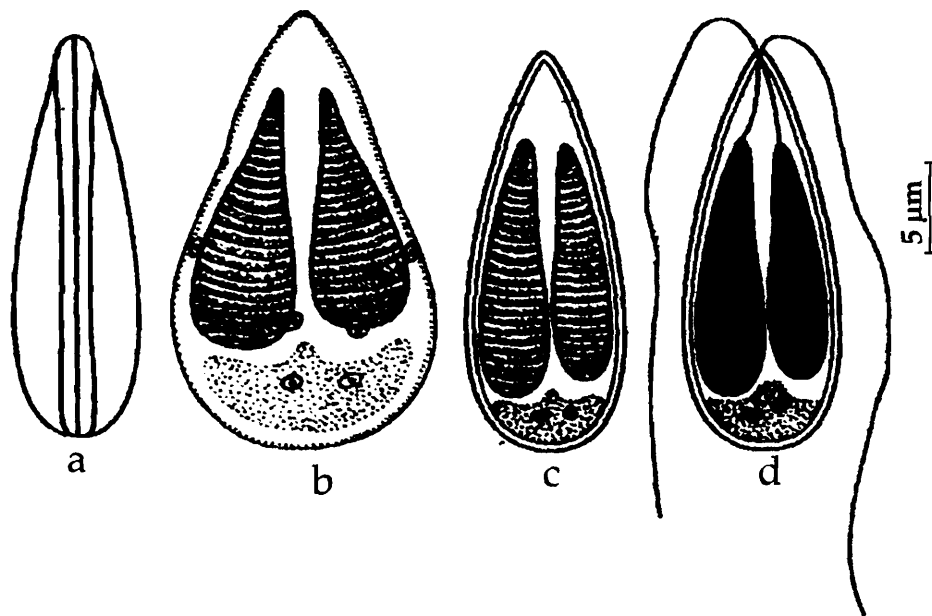


Fig. 119. *Myxobolus catmrigalae* : a. Fresh spore sutural view, b & c. Spore stained with Giemsa, d. Spore with extruded polar filament

Size : Spore length 20.0-21.8 (20.4) μm , width 15.7-17.1 (16.3) μm ; polar capsule (large) length 11.6-12.4 (11.9) μm , width 2.2-2.7 (2.3) μm ; polar capsule (small) length 10.7-11.3 (11.0) μm , width 2.2-2.5 (2.3) μm .

Host : *Catla-Mrigala* hybrid carp; **site of infection :** gill lamellae; **pathogenicity :** not apparent.

Distribution : India, West Bengal (Kalna, Burdwan district).

119. *Myxobolus cerebralis* Hofer 1903
(Fig. 120 a-b)

Diagnosis : Spore extremely variable broadly oval to circular in valvular view, broadly lenticular in sutural view; shell valves symmetrical, smooth; sutural ridge narrow; intercapsular ridge insignificant; polar capsules oval, equal; sporoplasm large, granular, filling the entire spore cavity; mucous envelope present at the posterior region.

Size : Spore length 7.4–9.7 μm , width 7.0–10.0 μm , thickness 6.2–7.4 μm ; polar capsule length 4.2–6.0 μm , width 3.0–3.5 μm .

Host : In several species of *Salmo*, *Onchorhynchus*, *Salvelinus*, *Thymallus thymullus*, *Clupea herengus*; **site of infection :** cartilage of head and vertebral column. **pathogenicity :** agent of whirling disease; enzymatic lysis and liquefaction of the cartilage; chondriocytes are phagocytosed by plasmodia.

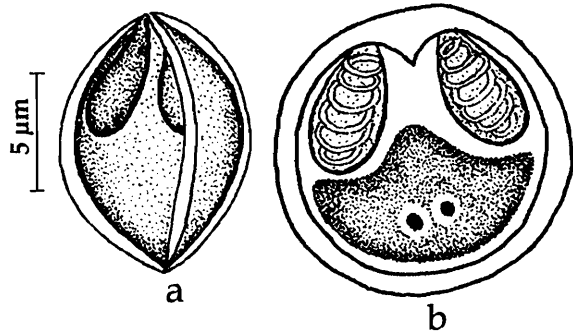


Fig. 120. *Myxobolus cerebralis* : a. Fresh spore sutural view, b. Spore stained with Giemsa

Distribution : India : Haryana (Sonepat);
Elsewhere : United States.

Remarks : Ram *et al.* (1984) reported the occurrence of this species in major carps, minor carps and murels in India.

120. *Myxobolus chakravartyi* Haldar, Das and Sharma, 1983

(Fig. 121 a-d)

Diagnosis : Cyst creamy-white, oblongate to rounded, 390–440 μm x 220–280 μm ; spore ovoidal; anterior end flat in between the two openings of the polar capsules, posterior end broadly rounded; shell valve symmetrical, uniform; inner wall forming a triangular thickening at the anterior end; sutural ridge prominent; polar capsule unequal, pyriform; polar filament forming 8–9 coils in the larger capsule, 6–7 coils while inside the smaller capsule; sporoplasm hemispherical, binucleate.

Size : Spore length 12.1–14.3 (12.3) μm , width 7.7–10.5 μm ; polar capsule (large) length 5.5–6.6 μm , width 3.3–5 μm ; polar capsule (small) length 4.4–5.0 μm , width 2.2–4.4 μm ; polar filament length 37.4–40.5 μm .

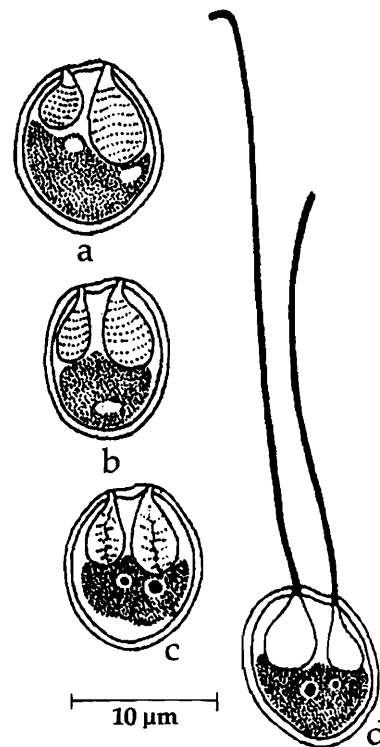


Fig. 121. *Myxobolus chakravartyi* : a & b. Fresh spores, c. Spore stained with Giemsa, d. Spore with extruded polar filament

Host : *Catla catla* (Ham.); *site of infection* : internal eye musculature; *pathogenicity* : not apparent.

Distribution : India : West Bengal (Krishnanagar, Nadia district).

121. *Myxobolus channai* (Kalavati, Sandeep and Narasimhamurti, 1981)
emend. Gupta and Khera, 1988
(Syn. *Myxosoma channai* Kalavati *et al.*, 1981)
(Fig. 122 a-c)

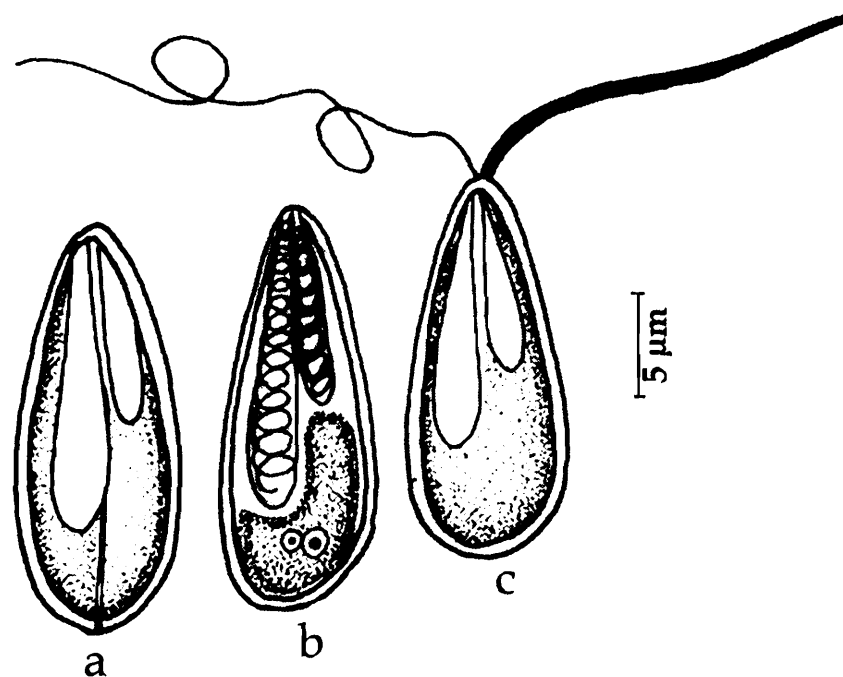


Fig. 122. *Myxobolus channai* : a. Fresh spore valvular view, b. Spore stained with Giemsa, c. Spore with extruded polar filament

Diagnosis : Trophozoites spherical or oval. 0.8-1.2 mm in size; spores elongated, oval; anterior end bluntly pointed, posterior rounded; shell valves smooth, equal; sutural ridge prominent, median; polar capsules 2, elongate, pear-shaped, unequal; polar filament in large capsule, thin, making 8 coils while inside the capsule; sporoplasm triangular, binucleate, below the capsules; iodophilous vacuole not seen.

Size : Spore length 14.5-18.0 (17.2) μm , width 6.0-6.5 (6.3) μm ; polar capsule (large) length 9.0-10.8 (10.2) μm , width 2.8-3.2 (3.0) μm ; polar capsule (small) length 7.2-8.8 (7.5) μm , width 2.8-3.2 (3.0) μm ; polar filament length 20-28 (26.5) μm .

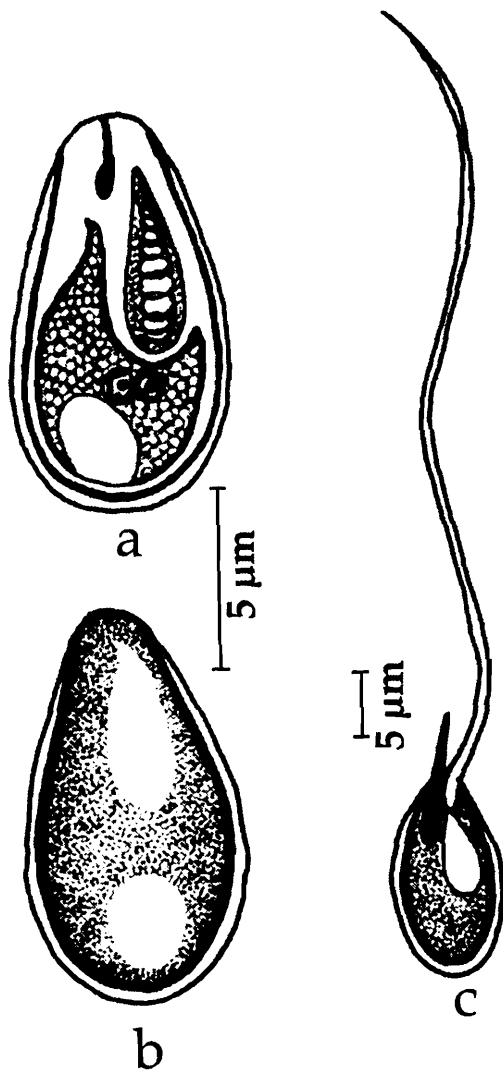
Host : *Channa punctatus*; *site of infection* : fins, body muscles, kidney and liver; *pathogenicity* : not apparent.

Distribution : India : Andhra Pradesh (Srungavarapukota, Elamanchili, Visakhapatnam, Visakhapatnam district).

122. *Myxobolus chilkensis* n. comb.(Syn. *Rudicapsula chilkensis* Kalavati, Venkataeswara Rao and Vaidehi, 1992)

(Fig. 123 a-c)

Diagnosis : Trophozoites spherical or oval, 0.5-0.8 mm in size, disporous; spore spherical to pyriform; anterior end bluntly pointed, posterior end rounded; shell valves thin, smooth; sutural ridge thin, straight; polar capsules unequal, convergent on either side of the sutural ridge; large capsule pyriform, subterminal, polar filament making 6-8 coils while inside the capsule; smaller polar capsule pyriform with a small neck, deeply stained, terminal, non-functional; no polar filament seen; only a small deeply stained rod-like structure seen inside; sporoplasm dumb-bell-shaped, binucleate occupying the entire extracapsular space; iodophilous vacuole present; polar filament long thin, tubular in large capsule; small deeply stained spine-like extension in rudimentary capsule.



Size : Spore length 7.2-8.0 (7.77) μm , width 5.6-6.6 (6.2) μm ; polar capsule (large) length 3.2-4.8 (4.2) μm , width 1.8-2.2 (1.98) μm ; polar capsule (small) length 1.0-1.2 (1.08) μm ; polar filament length 36.0-45.0 (41.25) μm .

Host : *Labeo rohita*; **site of infection :** gall bladder; **pathogenicity :** not apparent.

Distribution : India : Orissa (Chilka Lake).

Remarks : Landsberg and Lom (1991) and Lom and Dykova (1991) while revising the species of *Myxobolus*, abolished the genus *Rudicapsula* as a junior synonym and transferred the type species *Rudicapsula esomi* to the genus *Myxobolus* as *M. esomi*. Kalavati *et al.* (1991) described the second species of *Rudicapsula*, *R. chilkensis* simultaneously and it was not referred to by Landsberg and Lom (1991). However, in view of the abolition of genus *Rudicapsula* earlier and the species conforming with genus *Myxobolus*, we propose to change *R. chilkensis* also to genus *Myxobolus* as *Myxobolus chilkensis* n. comb.

Fig. 123. *Myxobolus chilkensis* : a. Fresh spore valvular view, b. Spore stained with Giemsa, c. Spore with extruded polar filament

123. *Myxobolus chinsurahensis* Basu and Haldar, 2003a
(Fig. 124 a-d)

Diagnosis : Spores histozoic, creamy white or yellow, tear-shaped with rounded posterior and bluntly pointed anterior ends in valvular view and lenticular in sutural view; shell valves thick, smooth; no parietal folds; sutural ridge prominent, median; polar capsules pyriform, equal; polar filament making 5-6 coils while inside the capsule; sporoplasm granular, binucleate, filling the extra capsular space; no mucuous envelop.

Size : Spore length 8.0-9.7 (8.4) μm , width 5.1-6.1 (5.4) μm ; polar capsule length 3.9 – 6.6 (4.4) μm , width 1.8-2.5 (2.1) μm ; polar filament length 20-28 (26.5) μm .

Host : *Anabas testudineus* (Bloch); **site of infection :** scales; **pathogenicity :** not apparent.

Distribution : India : West Bengal (Chinsurah, Hugli district).

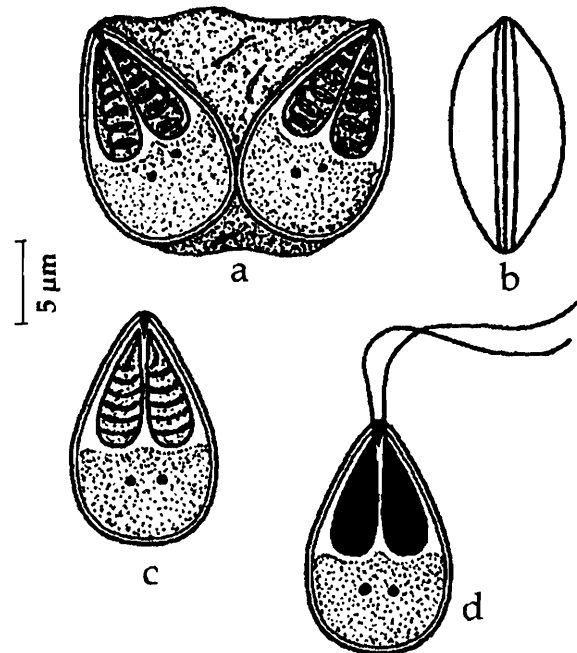


Fig. 124. *Myxobolus chinsurahensis* : a. Disporous trophozoite, b. Fresh spore sutural view, c. Spore stained with Giemsa, d. Spore with extruded polar filament

124. *Myxobolus clarii* Chakravarty, 1943
(Fig. 125 a-c)

Diagnosis : Cysts broadly oval, opaque white, measuring 775–780 μm x 604-877 μm ; spore subspherical in front view, lenticular in lateral view; shell valves comparatively thick, equal; sutural ridge distinct; polar capsules equal, pyriform with

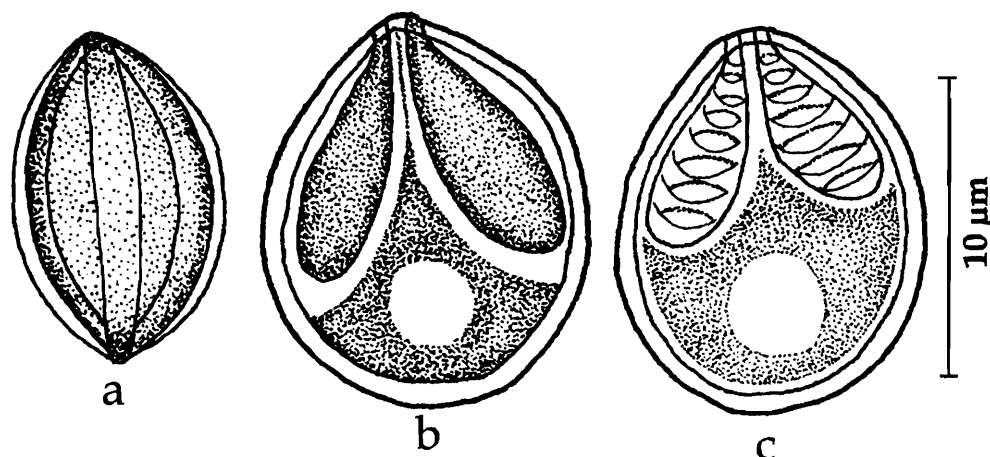


Fig. 125. *Myxobolus clarii* : a. Fresh spore sutural view, b. Fresh spore valvular view, c. Spore stained with Giemsa

their ends drawn into a short narrow tube; polar filament long; iodophilous vacuole single, spherical, 3 μm in diameter.

Size : Spore length 11.3-12.4 μm , width 10.3 μm ; polar capsule length 6.8 μm , width 3.09 μm ; polar filament length 50.0 μm .

Host : *Clarias batrachus* (Linn.); *site of infection* : gall bladder, liver, testes, ovary and fat bodies; *pathogenicity* : not apparent.

Distribution : India : West Bengal (Calcutta district).

125. *Myxobolus coeli* Haldar, Samal and Mukhopadhyay, 1996
(Fig. 126 a-c)

Diagnosis : Spore pyriform, pointed anteriorly, rounded posteriorly; shell valves symmetrical, uniformly thick; sutural line not distinct; polar capsules unequal, pyriform; sporoplasm cup-shaped, binucleate; iodophilous vacuole present.

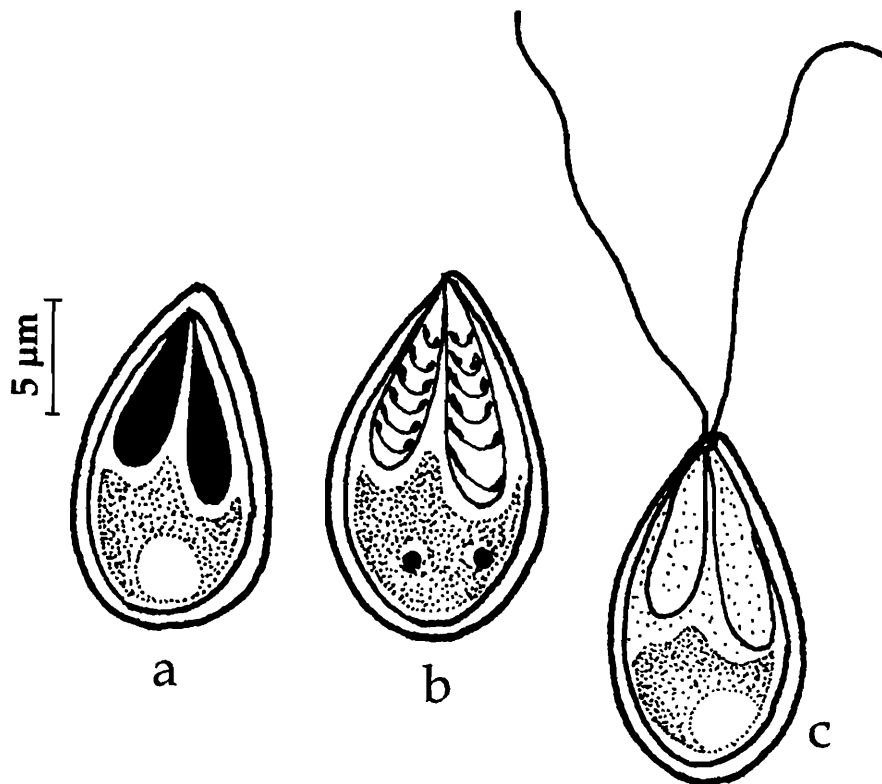


Fig. 126. *Myxobolus coeli* : a. Spore treated with iodine, b. Spore stained with Giemsa, c. Spore with extruded polar filament

Size : Spore length 8.3-14.9 (10.6) μm , width 4.1-8.4 (5.49) μm ; polar capsule (large) length 4.1-9.1 (5.76) μm , width 1.7-3.3 (2.85) μm ; polar capsule (small) length 1.7-6.6 (4.2) μm , width 1.7-4.1 μm .

Host : *Chanos chanos*; *site of infection* : gall bladder; *pathogenicity* : not apparent.

Distribution : India : Orissa (Chilka Lake).

126. *Myxobolus crucifilus* (Qadri, 1962) emend. Landsberg and Lom, 1991
(Syn. *Gyrospora crucifilus* Qadri, 1962a)
(Fig. 127 a-b)

Diagnosis : Spore pyriform; anterior end broad, posterior end narrow, bluntly curved; shell valve thick, symmetrical, single valve; sutural line not seen; polar capsules 2, circular with a distinct neck, convergent; a thread-like structure connecting 2 equal polar capsules; polar filaments thick, terminating into a fine undulating process, crossing each other when extended; sporoplasm hyaline, filling the entire spore cavity.

Size : Spore length 9-10 μm , width 8-8.5 μm ; polar capsule length 4.0-4.5 μm ; polar filament length 42-43 μm .

Host : *Labeo fimbriatus*; **site of infection** : gills; **pathogenicity** : not apparent.

Distribution : India : Andhra Pradesh (Fisheries Dept. sales depot, Hyderabad city).

Remarks : Landsberg and Lom (1991) abolished the genus *Gyrospora* Qadri, 1962 as a junior synonym of genus *Myxobolus*, Butschli, 1882.

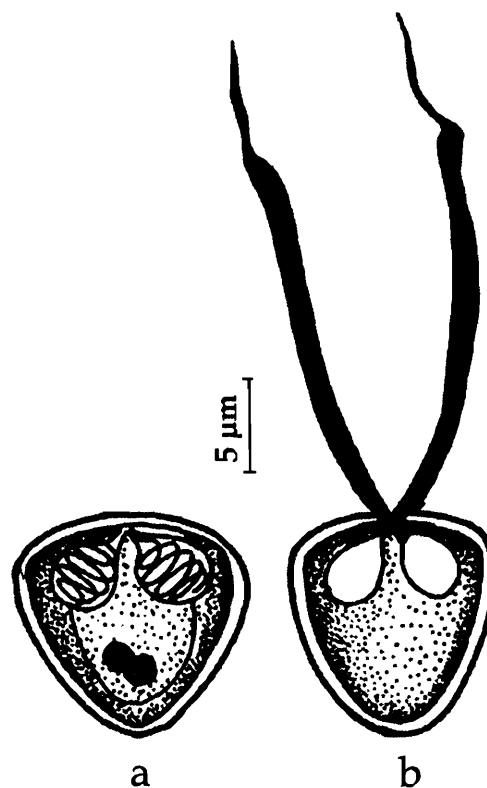


Fig. 127. *Myxobolus crucifilus* :
a. Spore stained with Giemsa, b. Spore with extruded polar filament

127. *Myxobolus curmucae* Seenappa and Manohar, 1980a
(Fig. 128 a-b)

Diagnosis : Spores oval in valvular view, lenticular in sutural view; shell valves thick; sutural ridge without thickenings; intercapsular ridge present; polar capsules pyriform equal, rarely slightly unequal; sporoplasm uninucleate filling the spore cavity; iodophilous vacuole present.

Size : Spore length 8.0-11.0 (9.8) μm , width 7.0-8.0 (7.6) μm , thickness 5.0-6.0 (5.3) μm ; polar capsule (large) length 4.5-

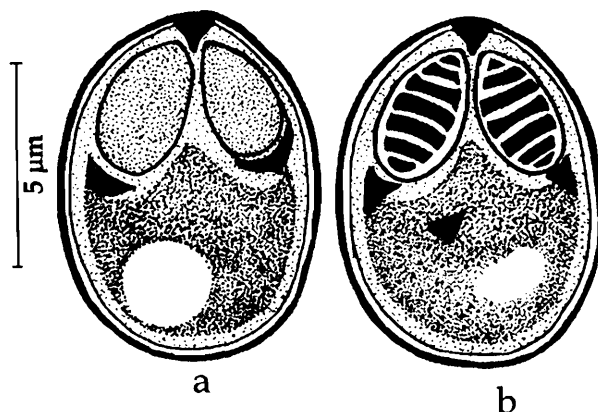


Fig. 128. *Myxobolus curmucae* : a. Fresh spore valvular view, b. Spore stained with Giemsa

5.0 (4.9), width 2.0-3.0 (2.5) μm ; polar capsule (small) length 3.0-4.0 (3.9) μm , width 2.0-3.0 (2.4) μm .

Host : *Puntius curmuca*; *site of infection* : below the scales; *pathogenicity* : not apparent.

Distribution : India : Karnataka (Nethravathi river, Bantwal).

128. *Myxobolus cuttacki* Haldar, Samal and Mukhopadhyay, 1996

(Fig. 129 a-b)

Diagnosis : Spore pyriform; anterior end elongated and pointed having a thickened notch between the two polar capsules; shell valves uniformly thick; polar capsules equal, pyriform; polar filament forming 5-8 coils while inside the capsule, sporoplasm granulated, binucleate; iodophilous vacuole present.

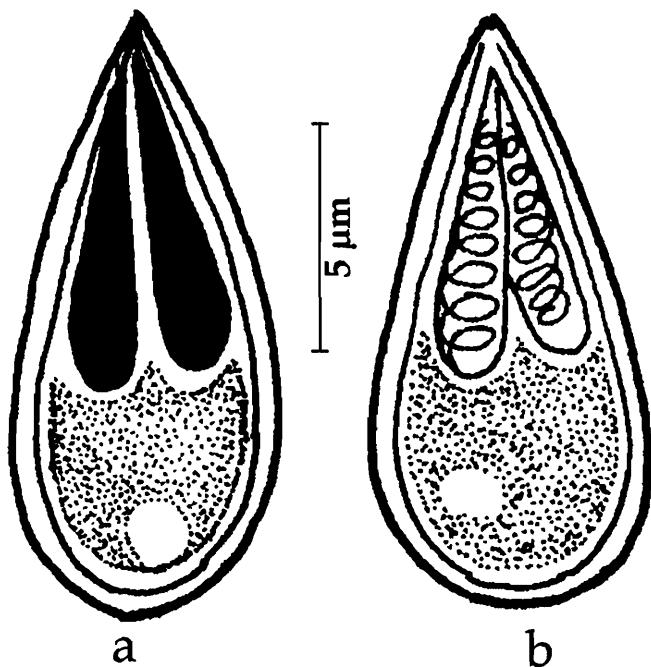


Fig. 129. *Myxobolus cuttacki* : a. Spore treated with iodine, b. Spore valvular view

Size : Spore length 13.0-21.1 (17.04) μm , width 4.9-8.1 (6.48) μm ; polar capsule length 6.5-13.0 (8.64) μm , width 1.6-4.0 (2.8) μm .

Host : *Cyprinus carpio*; *site of infection* : branchial filaments; *pathogenicity* : not apparent.

Distribution : India : Orissa (Cuttack, killa court fish farm)

129. *Myxobolus cylindricus* (Sarkar, Mazumdar and Pramanik, 1985) emend. Landsberg and Lom, 1991

(Syn. *Myxosoma cylindricus* Sarkar *et al.*, 1985)

(Fig. 130 a-d)

Diagnosis : Spore cylindroconical in valvular view, lenticular in sutural view; shell valves striated with 6-8 longitudinal striations on each valve; sutural line straight; polar capsules equal, pyriform, with a very short neck at the conical end of the spore;

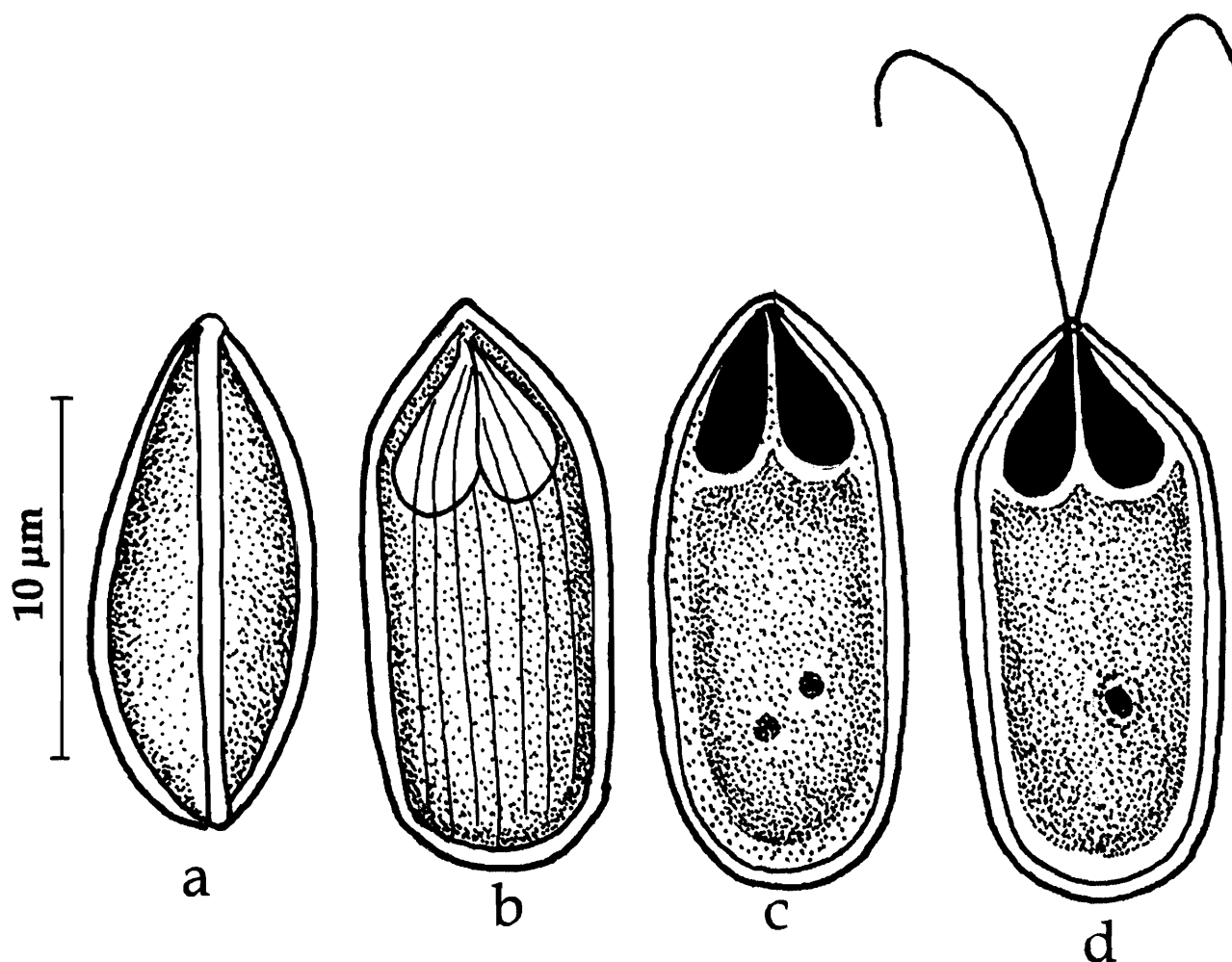


Fig. 130. *Myxobolus cylindricus* : a. Fresh spore sutural view, b. Spore surface view, c. Spore stained with Giemsa, d. Spore with extruded polar filament

sporoplasm granulated, binucleate; iodophilous vacuole absent; polar filament short and thread-like; unusual spores with a single polar capsule also reported.

Size : Spore length 12.8– 16.32 (14.37) μm , width 4.48–6.4 (4.91) μm , thickness 3.2–3.52 (3.41) μm ; polar capsule length 4.0–5.2 (4.48) μm , width 1.12–2.24 (1.68) μm ; polar filament length 8.0–16.0 (11.04) μm .

Host : *Channa gachua*; *site of infection* : kidney; *pathogenicity* : not apparent.

Distribution : India : West Bengal (Sagarpara Mushirabad district).

Remarks : Gupta and Khera (1988) while transferring this species to genus *Myxobolus* wrongly named it as *Myxobolus cylindrica*. Landsberg and Lom (1991) further emended the species as *Myxobolus cylindricus*.

130. *Myxobolus dasgupti* Haldar, Samal and Mukhopadhyay, 1996
(Fig. 131 a-c)

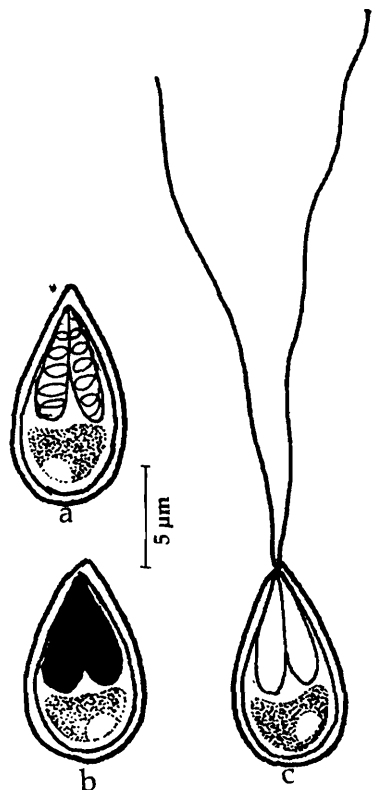


Fig. 131. *Myxobolus dasgupti* : a. Fresh spore, b. Spore treated with iodine, c. Spore stained with Giemsa

Diagnosis : Spore oval; anterior end tapering, posterior end broad, rounded; shell valves symmetrical, uniformly thick except at the anterior end between the capsular foramen; sutural line distinct; distinct inter-capsular notch present; polar capsules equal, pyriform; polar filament coils prominent inside the capsule (number not mentioned); sporoplasm hemispherical, binucleate; iodophilous vacuole spherical or oblongate.

Size : Spore length 11.4–19.5 (14.1) μm , width 4.9–8.1 (6.4) μm ; polar capsule length 7.3–11.4 (9.11) μm , width 1.6–4.0 (2.6) μm ; polar filament length 58.7–133.7 (79.9) μm .

Host : *Mugil tade* (Forskal); **site of infection** : body muscles and gills; **pathogenicity** : not apparent.

Distribution : India : Orissa (Chilka Lake).

131. *Myxobolus dermatis* (Haldar, Mukherji and Kundu 1981) emend. Gupta and Khera, 1988
(Syn. *Myxosoma dermatis* Haldar, Mukherji and Kundu 1981)
(Fig. 132 a-c)

Diagnosis : Cysts creamy white, 0.5–1.0 mm; spores oval or elongate or circular in valvular view, lenticular in sutural view; shell valves symmetrical, relatively thick, smooth; sutural line not seen; distinct intercapsular appendix present; polar capsules equal, pyriform; polar filament making 6 loose irregular coils while inside the capsule; sporoplasm crescentic, binucleate; iodophilous vacuole absent.

Size : Spore length 9.0–11.0 (10.3) μm , width 8.0–10.0 (9.4) μm ; polar capsule length 4.0–5.0 (4.4) μm , width 2.0–3.0 (2.2) μm ; polar filament length 10.0–25.0 (20.7) μm .

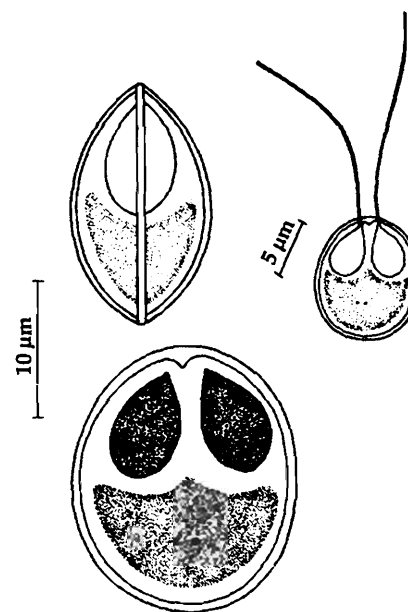


Fig. 132. *Myxobolus dermatis* : a. Fresh spore sutural view, b. Spore valvular view, c. Spore with extruded polar filament

Host : *Labeo rohita* (Ham); *site of infection* : scales; *pathogenicity* : not apparent.

Distribution : India : West Bengal (Ranaghat, Nadia district), Kerala (Poonthura backwaters).

Remarks : Krishnakumar (2000) recorded this species from Kerala infecting *Mugil cephalus*.

132. *Myxobolus edellae* Sarkar, 1999b

(Fig. 133 a-c)

Diagnosis : Spores nearly spherical to oval in valvular view, ellipsoidal in sutural view; shell valves symmetrical, moderately thick, smooth; sutural line broad, straight, ridged; polar capsules equal, pyriform; sporoplasm binucleate; iodophilous vacuole present; no mucous envelop.

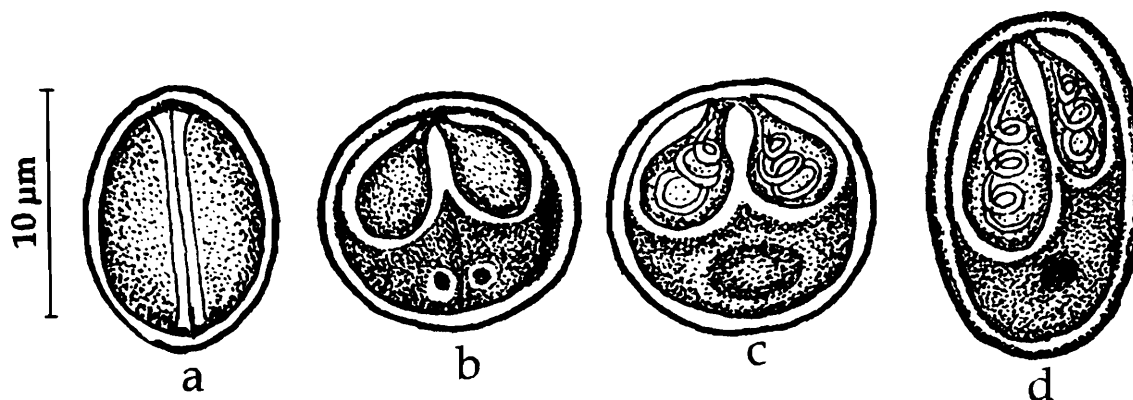


Fig. 133. *Myxobolus edellae* : a. Fresh spore sutural view, b. Spore stained with Giemsa, c & d. Spore with treated with iodine

Size : Spore length 10.5–11.5 (10.7) μm , width 9.0–10.0 (9.4) μm ; polar capsule length 5.5–6.5 (6.14) μm , width 2.5–3.5 (3.12) μm ; polar filament length 10.0–25.0 (20.7) μm .

Host : *Ctenopharyngodon edella* (Ham); *site of infection* : kidney; *pathogenicity* : not apparent.

Distribution : India : West Bengal (24 Parganas district).

133. *Myxobolus eeli* Mandal and Nair, 1975

(Fig. 134 a-b)

Diagnosis : Spore subspherical in front view, lenticular in lateral view; shell valves smooth, with 2-3 triangular folds; suture distinct and ridged; polar capsule two, equal, pyriform, convergent; polar filament making 6 coils while inside the capsule, thin when extended; sporoplasm hemispherical, 7-8 μm diameter; iodophilous vacuole spherical.

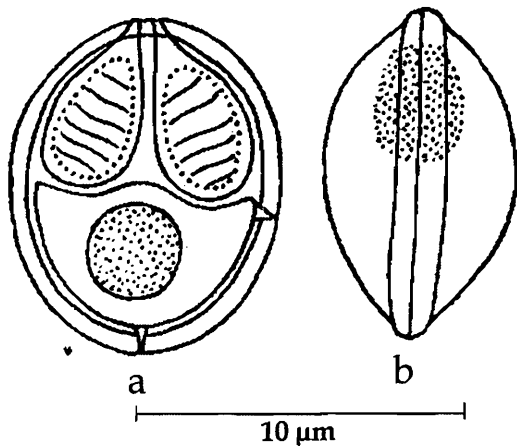


Fig. 134. *Myxobolus eeli* : a. Fresh spore valvular view, b. Spore sutural view

Size : Spore length 10.5-14 μm , width 8.2-11.5 μm ; polar capsule length 4.5-5.5 μm , width 2.5-3.0 μm ; polar filament length 28-32 μm .

Host : *Mastacembelus armatus* (Lacepede); *site of infection* : inner wall of intestine; *pathogenicity* : not apparent.

Distribution : India : West Bengal (South 24-Parganas district).

134. *Myxobolus encephalicus* (Muslow, 1911)
(Syn. *Lentospora encephalica* Muslow, 1911)

Diagnosis : Plasmodia in the blood vessels, long, 35-110 μm ; spores mostly oval, sometimes circular or irregularly rounded, greatly variable in both shape and size; iodophilous vacuole present; no mucous envelope on the surface of the spore.

Size : Spore length 6.2-12.6 μm , width 5.8-10.6 μm .

Host : *Labeo bata* (Ham); *site of infection* : brain, blood vessels; *pathogenicity* : emaciation, loss of balance, sunken eyes and fish exhibited whirling movements.

Distribution : India : Orissa (Cuttack district). *Elsewhere* : Germany.

Remarks : Das *et al.* (1988) reported this species from India.

135. *Myxobolus episquammalis* Egusa, Maeno and Sorimachi, 1990
(Fig. 135 a-c)

Diagnosis : Trophozoite flat, oval or irregularly outlined cyst; spores oval in front view, enclosed in a thick mucus coat; shell valves thin, smooth; sutural line thin, straight; polar capsules unequal, one narrow and the other broad, pyriform, convergent, terminal; inter-capsular appendix present; polar filaments making 4-6 coils while inside the capsule; sporoplasm semicircular, hyaline, iodophilous vacuole absent.

Size : Spore length 6.0-7.6 (7.2) μm , width 5.16-5.84 (5.6) μm ; polar capsule (broad) length 3.2-3.6 (3.45) μm , width 2.0-2.8 (2.6) μm ; capsule (narrow) length 3.2-3.6 (3.45) μm , width 1.4-1.6 (1.5) μm .

Host : *Mugil cephalus*, *Liza macrolepis*;
site of infection : gills, visceral peritoneum,
 intestine **Pathogenicity :** Inflammation and
 erosion of gills.

Distribution : India : Andhra Pradesh
 (Coastal waters of Visakhapatnam and
 Bheemunipatnam, Visakhapatnam district
 and Kakinada, East Godavari district),
 Orissa (Chilka Lake); **Elsewhere :** Japan :
 (Gokasho Bay), (Egusa *et al.*, 1990);
 Australia (Clarence River, New south
 Wales), (Rothwell *et al.*, 1997).

Remarks : This species is reported from
 the scales of *Mugil cephalus* in Japan and
 Australia. The species is recorded only
 from internal organs in India (Kalavati and
 Anuradha, 1992).

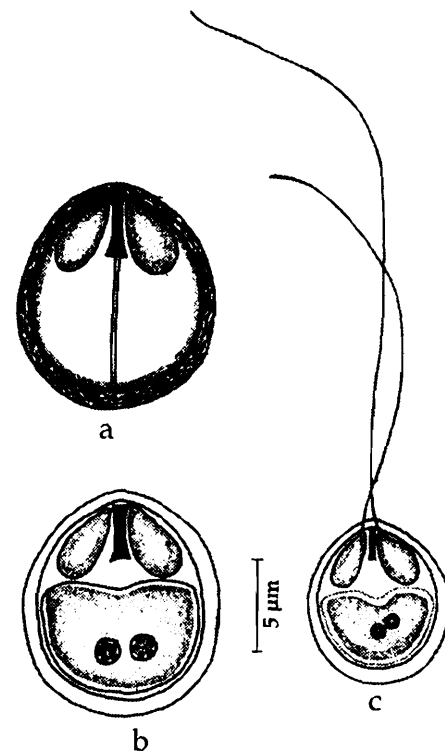


Fig. 135. *Myxobolus episquamalis* : a. Fresh spore valvular view, b. Spore stained with Giemsa, c. Spore with extruded polar filament

136. *Myxobolus esomi* (Kalavati and Narasimhamurti 1984a) emend. Landsberg and Lom, 1991
 (Syn. *Rudicapsula esomi* Kalavati and Narasimhamurti, 1984a)
 (Fig. 136 a-c)

Diagnosis : Trophozoites in the form of
 multilobulated tumors, 2.0-3.0 mm in size;
 spore pear-shaped; anterior end truncated,
 posterior end rounded; valves smooth,
 refractile, double layered, inner thick and
 outer thin; sutural line not noticed; polar
 capsules unequal, dissimilar; large capsule
 pyriform, subterminal; polar filament making
 9-10 coils while inside the capsule; smaller
 polar capsule rudimentary, terminal, non-
 functional, no polar filament; a small deeply
 stained rod-like structure seen inside;
 sporoplasm half-moon-shaped occupying the
 entire extracapsular space; iodophilous
 vacuole 3-4 µm in diameter.

Size : Spore length 11.2-12.4 (11.8) µm,
 width 6.8-7.2 (7.0) µm; polar capsule (large)
 length 4.8-5.2 (5.0) µm, width 3.0-3.2 (3.16)

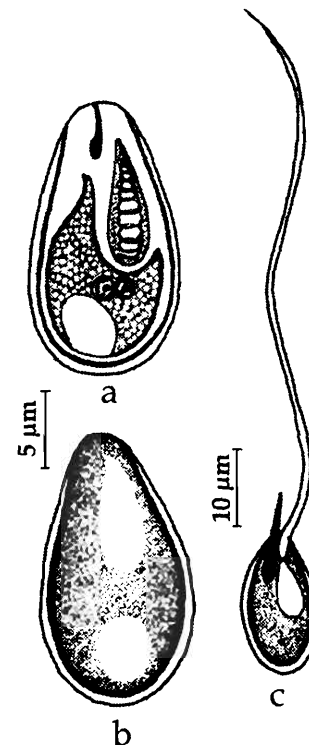


Fig. 136. *Myxobolus esomi* : a. Fresh spore valvular view, b. Spore stained with Giemsa, c. Spore with extruded polar filament

μm ; polar capsule (small) length 1.6-2.0 μm , width 1.0 μm ; polar filament length 48-56 (52.5) μm .

Host : *Esomus* sp. *site of infection* : caudal fin; *pathogenicity* : not apparent.

Distribution : India : Andhra Pradesh (Kondakarla lake, Visakhapatnam district).

Remarks : Landsberg and Lom (1991) abolished the genus *Rudicapsula* as a junior synonym of *Myxobolus* and renamed *R. eosomi* as *M. esomi*.

137. *Myxobolus etropi* Rajendran, Vijayan and Alvandi, 1998
(Fig. 137 a-d)

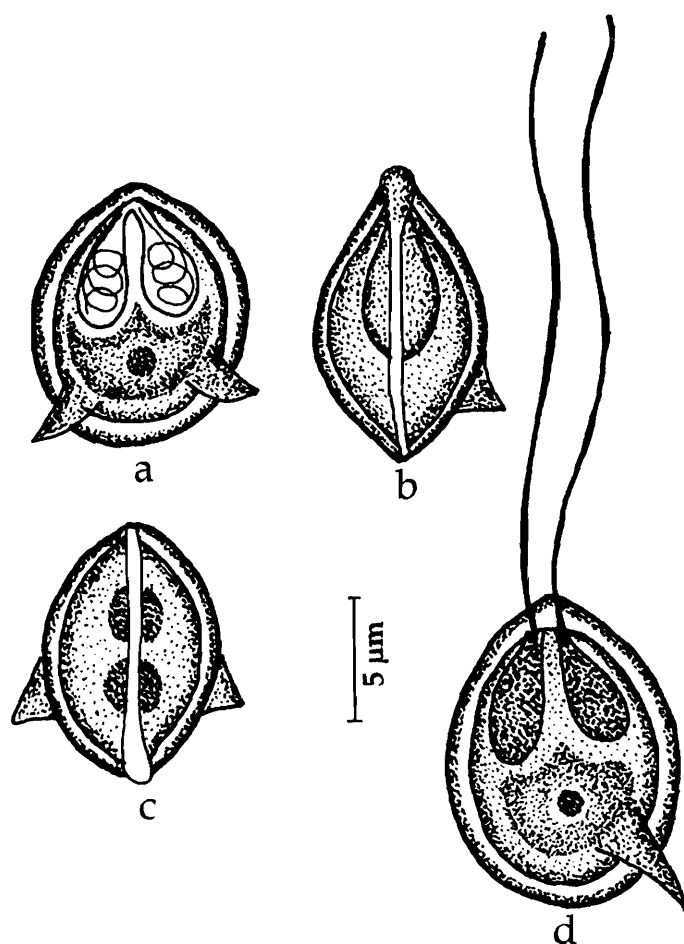


Fig. 137. *Myxobolus etropi* : a. Fresh spore valvular view, b & c. Spore sutural view, c. Spore with extruded polar filament

Diagnosis : 'Cysts' opaque, milky white to yellow 0.1-2.0 mm in size; spores oval in valvular view and lenticular in sutural view; shell valves symmetrical, smooth with short wing like out growths at the posterior end; sutural line prominent, straight to curved; polar capsules generally 2, rarely 3, equal, pyriform; polar filament forming 4-5 coils inside the capsule; sporoplasm uni or binucleate, filling the entire extracapsular spore cavity; iodophilous vacuole absent.

Size : Spore length 10.2-14.5 (12.2) μm , width 8.5 -11.9 (10.5) μm ; polar capsule length 3.8- 6.0 (5.0) μm , width 1.7-3.4 (2.4) μm .

Host : *Etroplus suratensis* (Bloch); *site of infection* : heart, bulbous arteriosis; *pathogenicity* : infected bulbous grossly enlarged, distorted with pericardial adhesions to visceral organs, elevated discoloured foci seen on the bulbous, metastasis and necrosis of elastic fibers reported.

Distribution : India : Tamil Nadu (Chennai coast, Muttukkadu lagoon).

138. *Myxobolus filamentosus* (Haldar, Mukherji and Kundu, 1985) emend. Landsberg and Lom, 1991
(Syn. *Myxosoma filamentosa* Haldar, Mukherji and Kundu 1985)
(Fig. 138 a-d)

Diagnosis : Spores broadly oval or slightly elongated in valvular view, lenticular in sutural view; shell valves considerably elevated; sutural ridge prominent; polar capsules unequal, pyriform, convergent; polar filament making 5-6 coils while inside the capsule, long, uniform, thread-like when extended; sporoplasm granular, binucleate filling the entire extracapsular space; iodophilous vacuole absent; mucous envelop present.

Size : Spore length 11.2-17.3 (13.7) μm , width 8.1-12.2 (9.5) μm , thickness 5.0-6.0 (5.20) μm ; polar capsule length 4.0-7.1 (3.6) μm , width 2.0-4.0 (3.1) μm ; polar filament length 23.4-34.6 (29.3) μm .

Host : *Puntius filamentosa*; **site of infection** : cartilage, brain; **pathogenicity** : not apparent.

Distribution : India : West Bengal (Kalyani, Nadia district)

Remarks : Gupta and Khera (1988) while transferring this species to genus *Myxobolus* wrongly named it as *Myxobolus filamentosa*. Landsberg and Lom (1991) further emended the species as *Myxobolus filamentosus*.

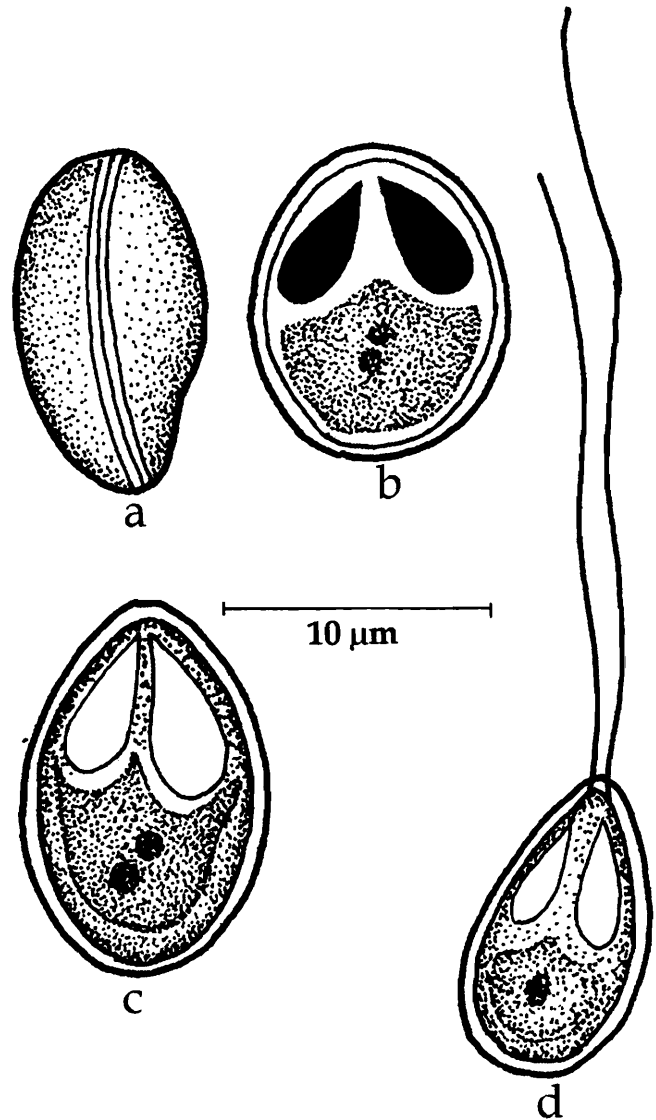


Fig. 138. *Myxobolus filamentosus* : a. Fresh spore sutural view, b. Spore treated with iodine, c. Spore stained with Giemsa, d. Spore with extruded polar filament

139. *Myxobolus fossilii* n. comb.
(Syn. *Myxosoma fossilii* Gupta, Gupta and Saraswat, 2001)
(Fig. 139 a-b)

Diagnosis : Spores elongated, oval with bluntly pointed anterior end and round posterior end in valvular view, lenticular in sutural view; shell valves considerably elevated; sutural ridge prominent; polar capsules equal, pear-shaped, parallel to each

other; polar filament coils not discernable while inside the capsule, thin, medium sized, deeply stained when extruded; sporoplasm triangular in shape, binucleate, not extending into inter capsular space; iodophilous vacuole absent.

Size : Spore length 9.0-12.0 (10.25) μm , width 6.2-8.5 (7.44) μm , thickness 5.0-6.0 (5.2) μm ; polar capsule length 4.5-7.0 (6.43) μm , width 1.75-2.75 (2.2) μm ; polar filament length 39.0-52.0 (44.75) μm .

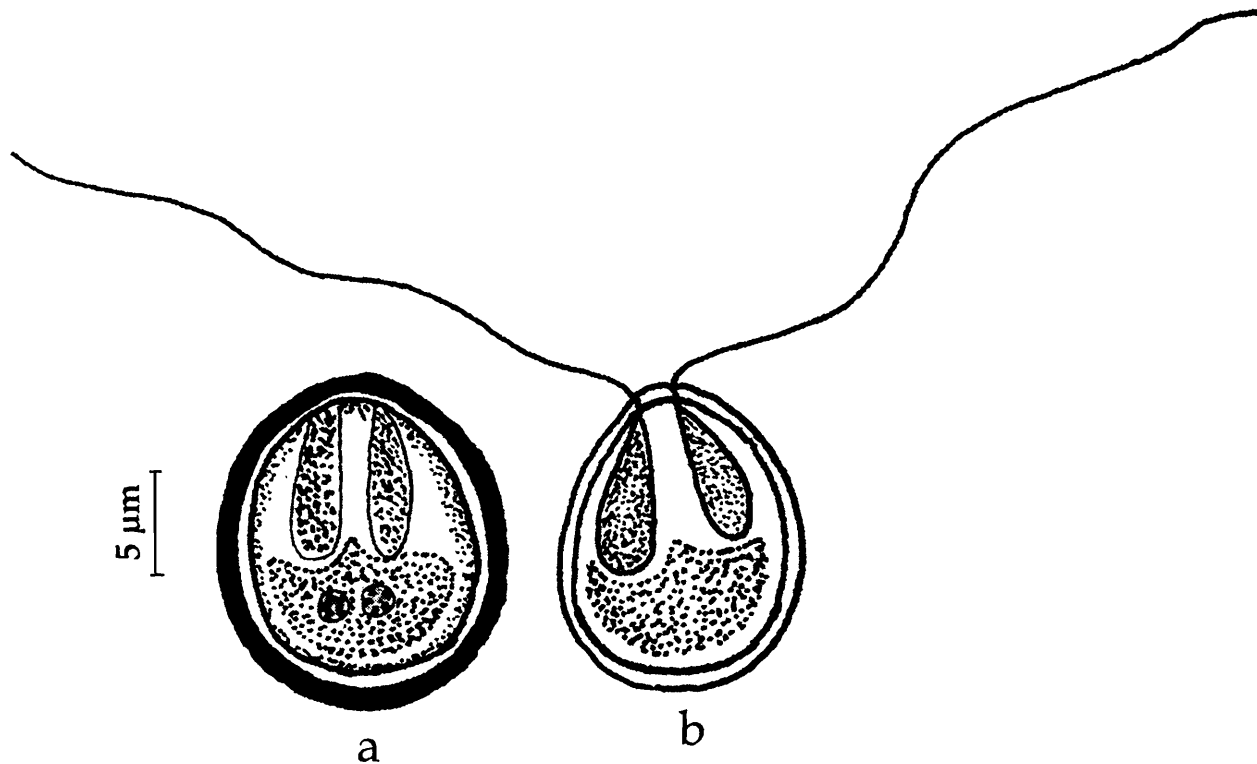


Fig. 139. *Myxobolus fossilii* : a. Fresh spore valvular view, b. Spore with extruded polar filament

Host : *Heteropneustes fossilis*; *site of infection* : cartilage, brain; *pathogenicity* : significant decrease in blood glucose levels reported when infected with this parasite. This species often occurred concomitantly with haemoflagellate, *Trypanosoma karensis*.

Distribution : India : Uttar Pradesh (Kareli, Rithora, Ramganga).

Remarks : Gupta, Gupta and Saraswat (2001) described a new species *Myxosoma fossili* from *Heteropneustes fossilis*. The genus *Myxosoma* is an invalid genus. Lom and Noble as early as 1984 synonymised the genera *Myxobolus* and *Myxosoma* since presence or absence of the iodophilous vacuole was no longer a taxonomic character for separation of these genera. Subsequently, Landsberg and Lom (1991) listed the valid species under the genus *Myxobolus* and revised extensively the species published under the generic name *Myxosoma*. Therefore, it is considered that the generic identification of *Myxosoma fossilii* is incorrect and we propose to change it to genus *Myxobolus* and amend the name as *Myxobolus fossilii* n. comb.

146. *Myxobolus gangulyi* (Sarkar, Haldar and Chakraborti, 1982) emend. Gupta and Khera, 1988b
(Syn. *Myxosoma ganguli* Sarkar, Halder and Chakraborti, 1982)
(Fig. 140 a-d)

Diagnosis : Trophozoites oval, 100 μm in size; pansporoblast spherical, 11-14 μm in diameter with 1-4 spores; spores oval to ellipsoidal in valvular view; anterior end slightly pointed, posterior end round; shell valves striated with 6-8 striations on each valve; polar capsules unequal, pyriform, convergent; polar filament making 5-6 coils while inside the capsule; sporoplasm granular, binucleate filling the entire extra capsular space; iodophilous vacuole absent.

Size : Spore length 8.0-10.5 (8.73) μm , width 4.8-6.5 (5.03) μm , thickness 5.0-6.0 (5.2) μm ; polar capsule (large) length 2.8-4.6 (3.6) μm , width 1.5-2.5 (1.9) μm ; polar capsule (small) length 2.2-3.0 (2.4) μm , width 1.3-2.0 (1.5) μm .

Host : *Sillago maculata*; **site of infection** : cartilage of the head skeleton; **pathogenicity** : not apparent.

Distribution : India : Andaman Islands (South Andaman sea).

Remarks : Gupta and Khera (1988) while reviewing the genus *Myxobolus* discussed the abolition of the genus *Myxosoma* and transferred all species of *Myxosoma* described till then from India to the genus *Myxobolus*. Further they corrected the spelling of *M. gangulii* Sarkar *et al.*, 1982 as *M. gangulyi* following the Articles 31 and 32(c) of International Code of Zoological Nomenclature. This change was, however, not followed by Landsberg and Lom (1991).

141. *Myxobolus goensis* Eiras and D'souza, 2004
(Fig. 141)

Diagnosis : Developing plasmodia digitiform, cylindrical, 80-120 μm x 280-360 μm with rounded extremities, enveloped by a thin layer of epithelial cells; spores oval in front view, lemon-shaped in lateral view, with 6 sutural marks along the sutural ridge; shell valves thin, symmetrical, smooth; polar capsules markedly unequal, pyriform;

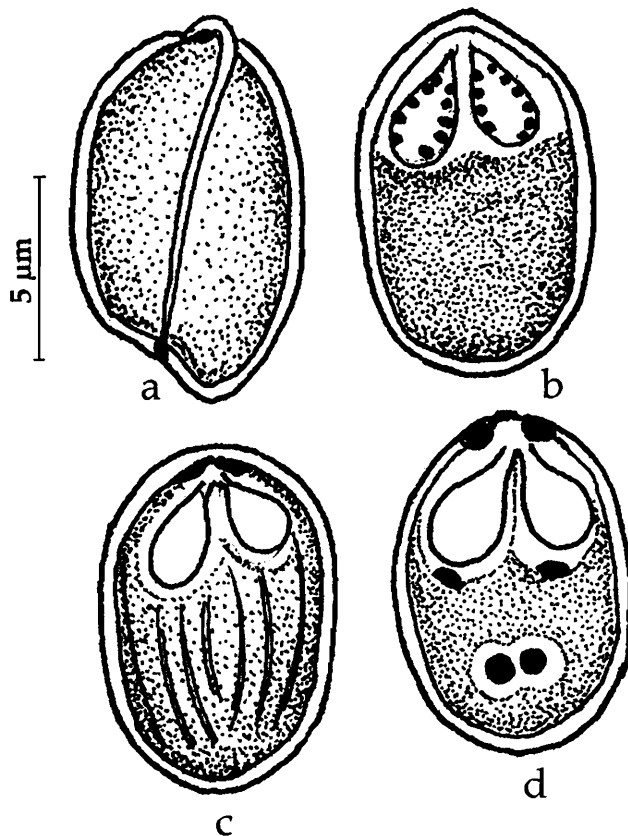


Fig. 140. *Myxobolus gangulyi* : a-c. Fresh spores, d. Spore stained with Giemsa

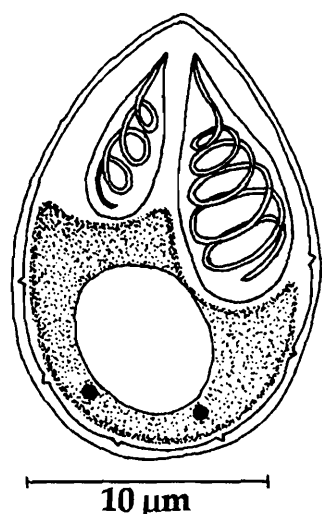


Fig. 141. *Myxobolus goensis* :
Spore valvular view

polar filament making 5 coils while inside the large capsule and 3 coils in small capsule; a thin mucuous envelop present around the spore; no intercapsular ridge; iodophilous vacuole present.

Size : Spore length 9.5-10.5 (9.7) μm , width 6.0-7.5 (6.6) μm , thickness 5.0-6.0 (5.2) μm ; polar capsule (large) length 4.5-6.0 (5.3) μm , width 2.0-3.0 (2.4) μm ; polar capsule (small) length 2.0-3.0 (2.4) μm , width 1.5-2.0 (1.8) μm .

Host : *Mugil cephalus*; *site of infection* : gill rakers; *pathogenicity* : not apparent.

Distribution : India : Goa (Indian Ocean coast).

142. *Myxobolus haldari* Gupta and Khera, 1989b
(Fig. 142 a-c)

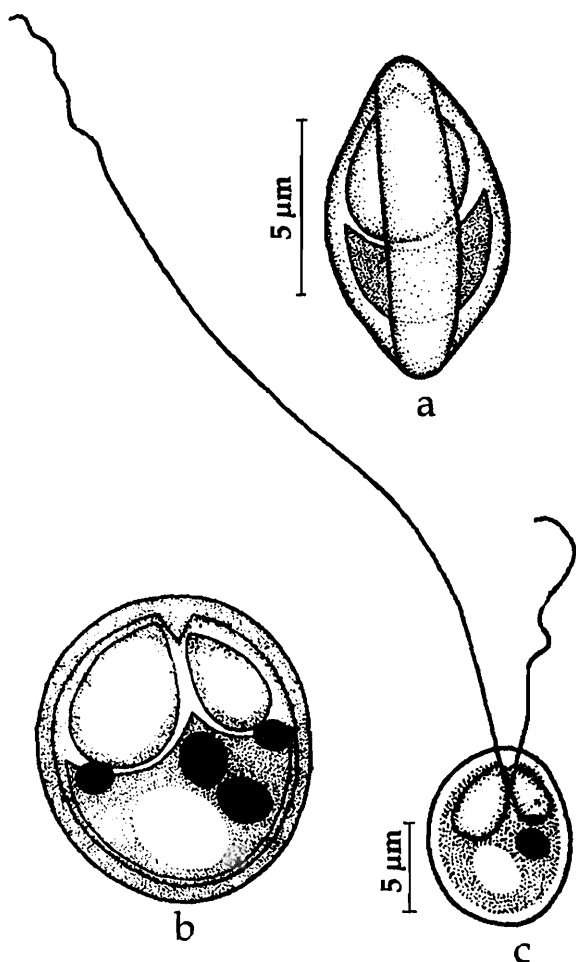


Fig. 142. *Myxobolus haldari* : a. Fresh spore sutural view, b. Spore valvular view

Diagnosis : Cysts milky white, spherical to oblong, 0.152-0.68 mm x 0.102-0.532 mm in size; spores oblong to oval in valvular view, elliptical in sutural view; shell valves symmetrical; sutural ridge straight, prominent; polar capsules 2, unequal, oval with a small distinct neck; intercapsular ridge triangular; sporoplasm granular, binucleate occupying the extra capsular space, iodophilous vacuole present.

Size : Spore length 9.0-10.0 (9.31) μm , width 7.0-8.5 (7.95) μm ; polar capsule (large) length 4.0-5.0 (4.31) μm , width 2.5-3.0 (2.97) μm ; polar capsule (small) length 2.5-3.0 (2.95) μm , width 1.5-2.0 (1.98) μm ; polar filament (long) length 31-70 μm .

Hosts : *Cirrhinus mrigala* (Hamilton), *Labeo dyocheilus* (McClelland), *L. rohita* (Hamilton), *L. bata* (Hamilton); *site of infection* : fins and gills; *pathogenicity* : not apparent.

Distribution : India : Punjab (Chandigarh, Ropar, Ludhiana, Harike, Ferozpur).

Remarks : Localisation of various macromolecules such as proteins, carbohydrates, nucleic acids and enzymes were studied using cytochemical methods (Gupta and Khera, 1988). Concentration of acid and alkaline phosphatases, glucose -6- phosphotase and ATP in the spore wall, polar capsules was reported. Extranuclear DNA was also reported from spore wall and capsular membrane and polar filaments.

143. *Myxobolus hosadurgensis* Seenappa and Manohar, 1981
(Fig. 143)

Diagnosis : Spore histozoic, elongately ovoidal in valvular view, lenticular in sutural view; shell valves smooth, symmetrical; sutural ridge clear; polar capsules pyriform, unequal, convergent; sporoplasm round, granular, binucleate, filling the extracapsular cavity; iodophilous vacuole present; inter capsular ridge in the form of a rod.

Size : Spore length 9.0-11.0 (10.5) μm , width 5.0-8.0 (6.25) μm ; polar capsule (large) length 4.0-6.0 (5.37) μm , width 2.0-3.0 (2.3) μm ; polar capsule (small) length 2.5-4.0 (3.3) μm , width 1.0-2.5 (1.43) μm .

Host : *Cirrhina mrigala* (Ham.); **site of infection** : gills, muscle; **pathogenicity** : not apparent.

Distribution : India : Karnataka (Vanivilasa farm ponds).

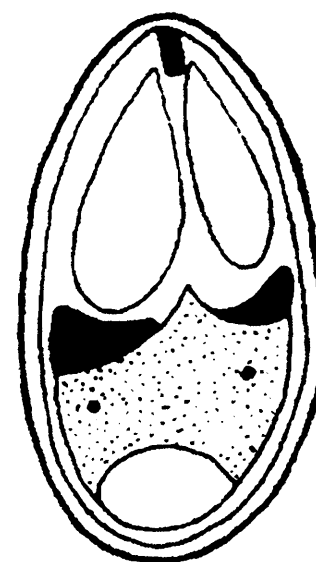


Fig. 143. *Myxobolus hosadurgensis* : spore valvular view

144. *Myxobolus hyderabadense* (Lalitha Kumari 1969) emend. Gupta and Khera, 1988b
(Syn. *Myxosoma hyderabadense* Lalitha Kumari, 1969)
(Fig. 144 a-d)

Diagnosis : Spores pyriform; anterior end narrow, pointed, posterior end rounded; shell valves equal with 4-6 ridges at the posterior end; sutural ridge broad with a clear median sutural line; polar capsules 2, equal, pyriform, subterminal with small intercapsular space; polar filaments equal, forming 8-9 coils within the capsule, long and thin when extended; sporoplasm small, granular, homogenous; iodophilous vacuole absent.

Size : Spore length 9.3-11.5 (10.1) μm , width 5.0-8.0 (5.9) μm ; polar capsule length 5.0-7.3 (5.8) μm , width 1.4-3.0 (2.2) μm ; polar filament length 69.0 μm .

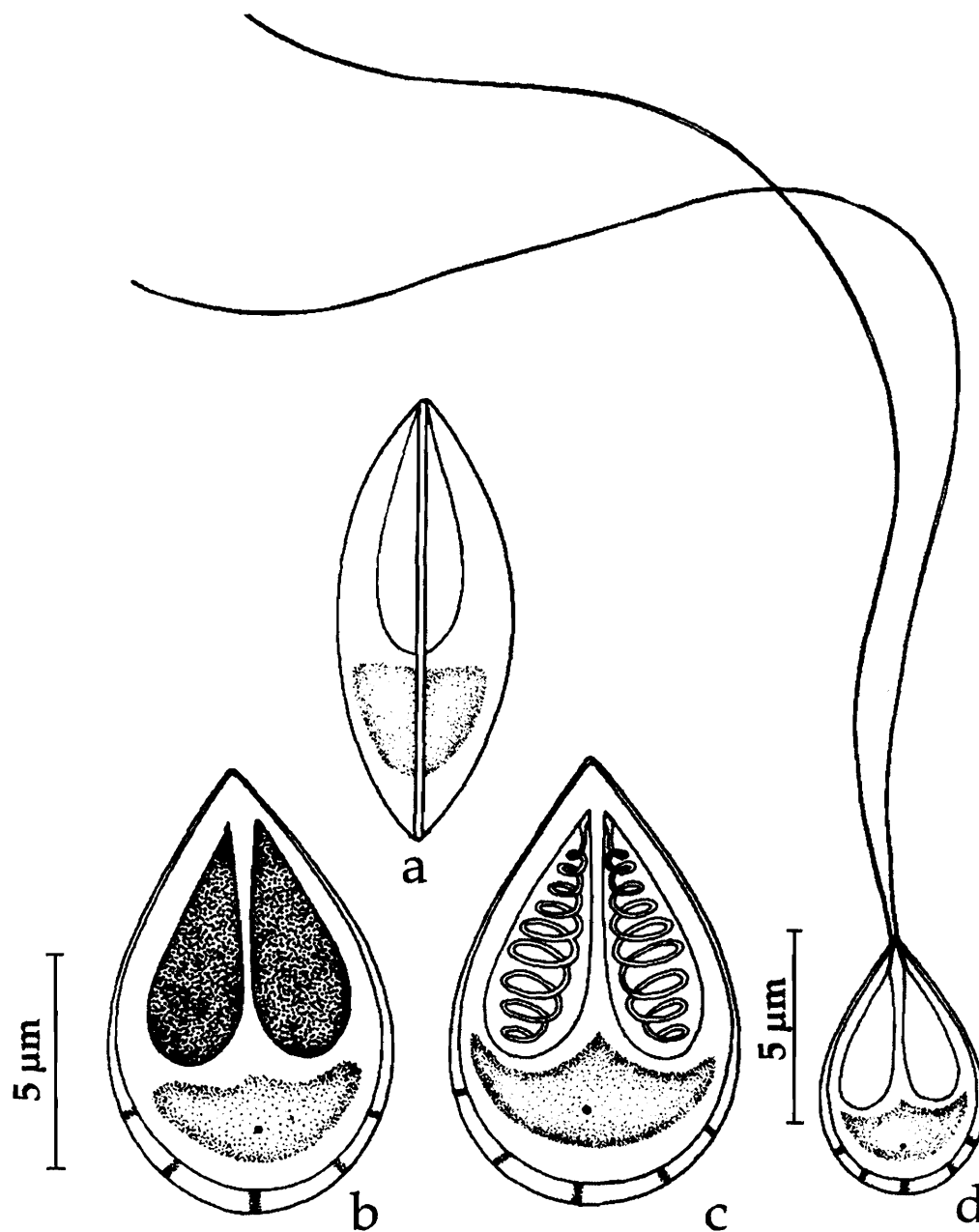


Fig. 144. *Myxobolus hyderabadense* : a. Fresh spore sutural view, b. Spore valvular view, c. Spore stained with Giemsa, d. Spore with extruded polar filament

Host : *Barbus pinnauratus*, *Puntius filamentosus*; *site of infection* : gill filaments; *pathogenicity* : not apparent.

Distribution : India : Andhra Pradesh (Hyderabad city), Kerala; (Vellayani lake).

Remarks : Krishnakumar (2000) described this species from Kerala infecting *Puntius filamentosus*.

145. *Myxobolus indiae* (Lalitha Kumari 1969) emend. Gupta and Khera, 1988b
 (Syn. *Myxosoma indiae* Lalitha Kumari, 1969)
 (Fig. 145 a-d)

Diagnosis : Trophozoites 1.0–2.0 mm in diameter; pansporoblasts disporous; spores pyriform or ovoid; anterior end narrow, pointed, posterior end rounded; sutural ridge median visible to the middle of the spore; polar capsules 2–3 in number, unequal, pyriform opening independently; polar filaments unequal, forming 8–10 coils within the capsule, thin and long when extended; sporoplasm clear, homogenous filling the entire spore cavity extending into intra capsular space; iodophilous vacuole absent.

Size : Spore length 12.4–15.0 (13.7) μm , width 6.4–8.6 (7.3) μm ; polar capsule (large) length 5.7–7.1 (5.9) μm , width 1.4–2.5 (2.1) μm ; polar capsule (small) length 5.0–6.4 (5.2) μm , width 1.4–2.5 (2.1) μm ; polar filament length 71.5–107.0 (87.0) μm .

Host : *Barbus sarana*; **site of infection** : gill filaments; **pathogenicity** : not apparent.

Distribution : India : Andhra Pradesh : (Hyderabad city, and Warangal, Warangal districts).

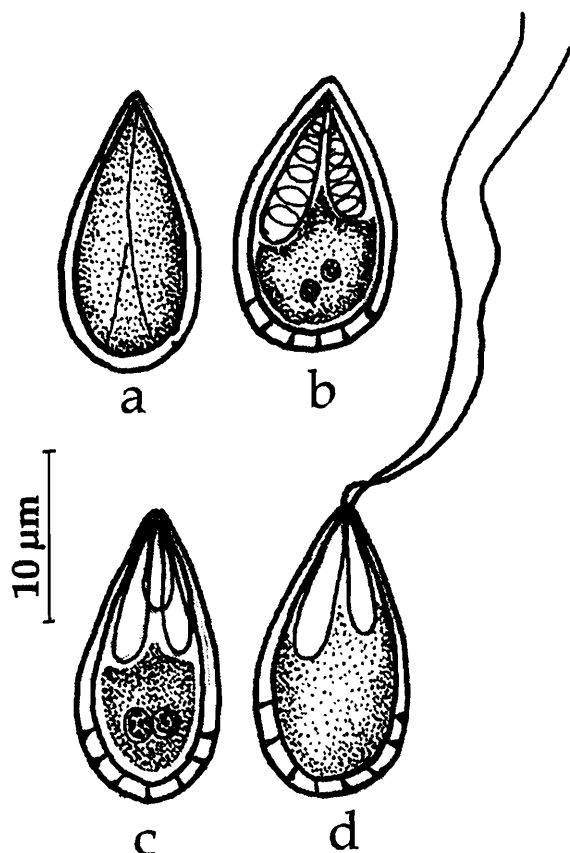


Fig. 145. *Myxobolus indiae* : a. Fresh spore valvular view, b. Spore stained with Giemsa, c. Spore with 3 polar capsules, d. Spore with extruded polar filament

146. *Myxobolus indicum* Tripathi, 1952
 (Fig. 146 a-b)

Diagnosis : Spore oval in front view, lenticular in side view; shell valves moderately thick, smooth and symmetrical; polar capsules unequal and divergent; longer one pyriform, the smaller one more or less spherical; iodophilous vacuole round to oval, 2.5 μm in diameter.

Size : Spore length 9.5–10.8 μm , width 7.5–8.2 μm ; polar capsule (large) length 2.7–3.6 μm , width 1.8 μm ; polar capsule (small) length 1.8 μm , width 1.0 μm .

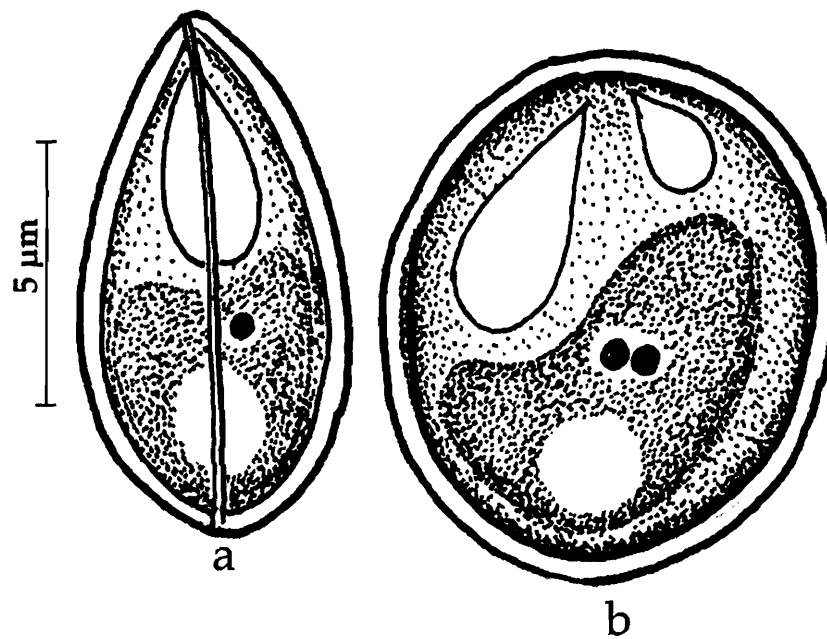


Fig. 146. *Myxobolus indicum* : a. Fresh spore sutural view, b. Spore valvular view

Host : *Cirrhinus mrigala* (Ham.); *site of infection* : muscles, liver and intestinal wall; *pathogenicity* : not apparent.

Distribution : India : West Bengal (North 24-Parganas district).

147. *Myxobolus indirae* (Kundu, 1985) emend. Gupta and Khera, 1988b
(Syn. *Myxosoma indirae* Kundu, 1985)
(Fig. 147 a-d)

Diagnosis : Cysts small, round or egg-shaped, 0.5-1.0 mm in size; spores oval or spherical in valvular view and lenticular in sutural view; shell valves thick, smooth; sutural ridge thick; polar capsules pyriform, equal, convergent; polar filament making 8-10 coils while inside the capsule; sporoplasm crescentic, finely granular, binucleate, filling the extra capsular spore cavity; iodophilous vacuole absent.

Size : Spore length 11.0-14.0 (12.6) μm , width 9.0-11.0 (9.6) μm ; polar capsule length 4.0-6.0 (4.7) μm , width 2.0-2.5 (2.2) μm ; polar filament length 28.0-37.0 (31.6) μm .

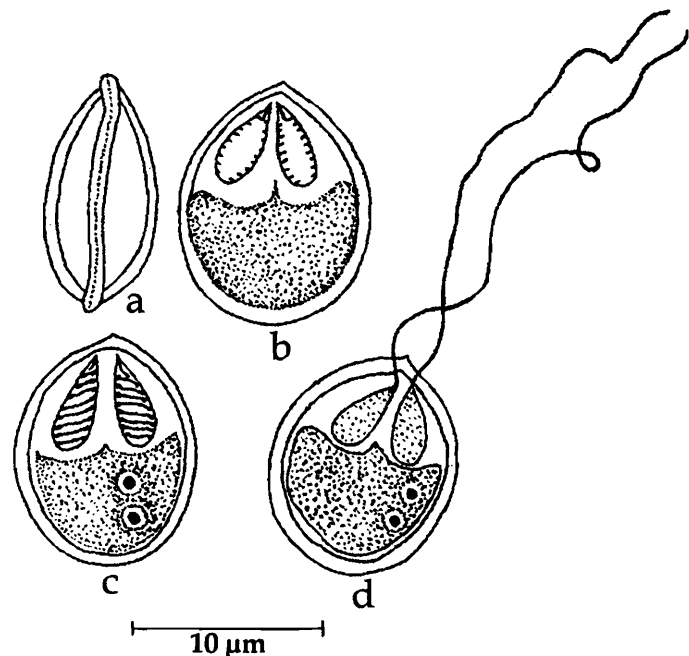


Fig. 147. *Myxobolus indirae* : a. Fresh spore sutural view, b. Spore valvular view, c. Spore stained with Giemsa, d. Spore with extruded polar filament

Host : *Cirrhina mrigala* (Hamilton); *site of infection* : scales of tail fin, cartilage of head; *pathogenicity* : not apparent.

Distribution : India : West Bengal (Ranaghat, Nadia district).

148. *Myxobolus karnatakae* (Hagargi and Amoji, 1981) emend. Landsberg and Lom, 1991
(Syn. *Myxosoma karnatakae* Hagargi and Amoji, 1981)
(Fig. 148 a-b)

Diagnosis : Spores pyriform; valves thin, equal; sutural ridge broad; polar capsules 2, equal, pyriform; polar filament forming 6-7 coils while inside the capsule; sporoplasm granular, uninucleate, iodophilous vacuole absent.

Size : Spore length 16.32–19.04 (17.58) μm , width 10.88–13.6 (11.1) μm ; polar capsule length 7.3–10.88 (11.11) μm , width 3.58–5.44 (4.78) μm .

Host : *Barbus chola* (Ham. et Buch); *site of infection* : caudal muscles; *pathogenicity* : not apparent.

Distribution : India : Karnataka (Gulbarga).

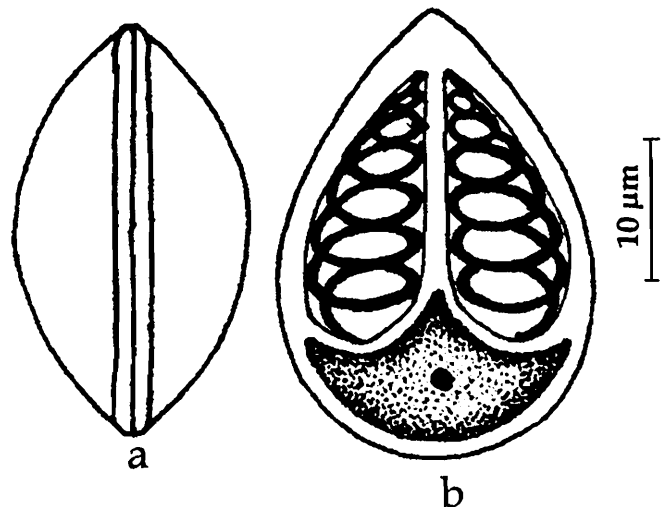


Fig. 148. *Myxobolus karnatakae* : a. Fresh spore sutural view, b. Spore stained with Giemsa

149. *Myxobolus koli* Lalitha Kumari, 1969
(Fig. 149 a-c)

Diagnosis : Pansporoblasts disporous; spores oval with broad posterior and truncated anterior ends; shell valves thin, transparent, uniformly thick with 6–8 parietal

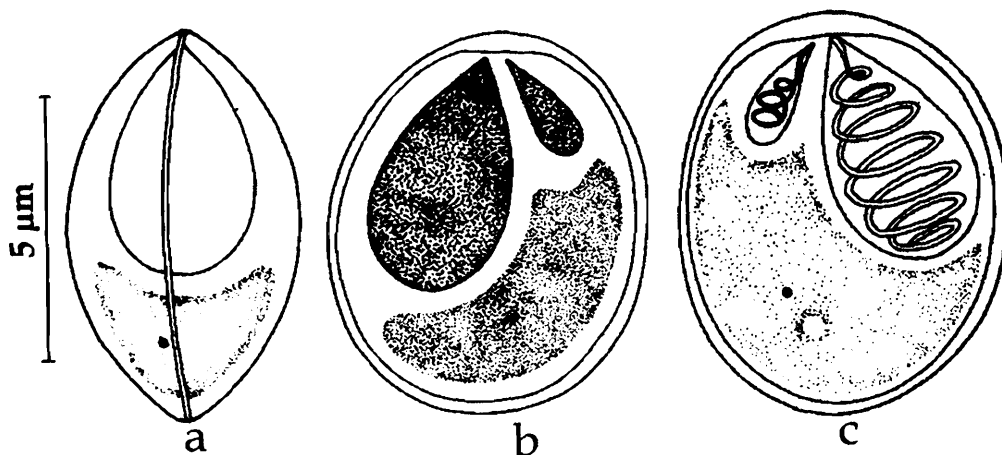


Fig. 149. *Myxobolus koli* : a. Fresh spore sutural view, b. Spore valvular view, c. Spore stained with Giemsa

markings on posterior margin; sutural ridge not prominent; sutural line fine slightly curved; polar capsules 2, unequal, one very small, pyriform; polar filament remarkably unequal, forming 5-6 tight coils while inside the capsule; sporoplasm granular, homogenous occupying the place behind the polar capsule; iodophilous vacuole large, oval or spherical.

Size : Spore length 7.1–9.6 (8.4) μm , width 5.0–6.4 (6.0) μm ; polar capsule (large) length 3.9–4.6 (4.3) μm , width 2.1–3.1 (2.8) μm ; polar capsule (small) length 1.4–2.1 (2.0) μm , width 0.7–1.4 (1.2) μm ; polar filament length- long 42.0–70.5 (51.3) μm , small 6.0–13.5 (8.9) μm .

Host : *Barbus kolus*, *Puntius filamentosus*; *site of infection* : dorsal and ventral fins; *pathogenicity* : not apparent.

Distribution : India : Andhra Pradesh : (Local market in Hyderabad city), Kerala (Vellayani lake).

Remarks : Krishnakumar (2000) reported this species from Kerala infecting *Puntius filamentosus*.

150. *Myxobolus labeosus* Sarkar, 1995b

(Fig. 150 a-d)

Diagnosis : Spores oval to egg-shaped, asymmetric with rounded ends in valvular view; valves smooth, thick, double layered; sutural line broad but not ridged; polar capsules unequal and dissimilar, broadly pyriform, located at right angles to each other, subterminal; polar filament forming 5-7 coils in the large capsule and 3-5 in the smaller

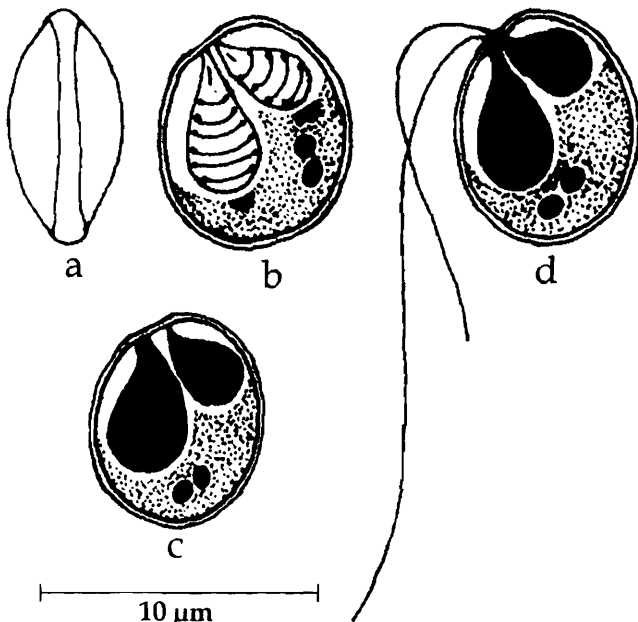


Fig. 150. *Myxobolus labeosus* : a. Fresh spore valvular view, b. Spore stained with Giemsa, c. Spore treated with iodine, d. Spore with extruded polar filament

capsule; unequal, fine, thread-like when extended; sporoplasm crescentic, binucleate, filling the entire extracapsular spore cavity; iodophilous vacuole absent.

Size : Spore length 8.0–10.0 (9.25) μm , width 6.5–9.0 (7.62) μm ; polar capsule (large) length 6.0–6.5 (6.15) μm , width 2.0–4.0 (4.02) μm ; polar capsule (small) length 3.0–4.5 (4.02) μm , width 1.8–2.5 (2.33) μm .

Host : *Labeo fimbriatus*; *site of infection* : mesentery associated with spleen; *pathogenicity* : not apparent.

Distribution : India : West Bengal (South 24 Parganas district).

151. *Myxobolus lalithae* Gupta and Khera, 1988c
(Fig. 151 a-b)

Diagnosis : Cysts opaque white without any clear wall; spores oval or elliptical; shell valves symmetrical; sutural ridge prominent, triangular; intercapsular ridge present; polar capsules pyriform, unequal; sporoplasm small, finely granular, uninucleate, located posterior to capsules; iodophilous vacuole present.

Size : Spore length 9.0–11.0 (10.0) μm , width 8.0–9.0 (8.4) μm ; polar capsule (large) length 5.0–6.0 (5.8) μm , width 3.0–3.5 (3.05) μm ; polar capsule (small) length 4.0–5.0 (4.8) μm , width 2.5–3.0 (2.85) μm ; polar filament length-long 65–70.5 μm , small 50 μm .

Host : *Labeo calbasu* (Hamilton); **site of infection :** gills; **pathogenicity :** not apparent.

Distribution : India : Punjab; (Harike).

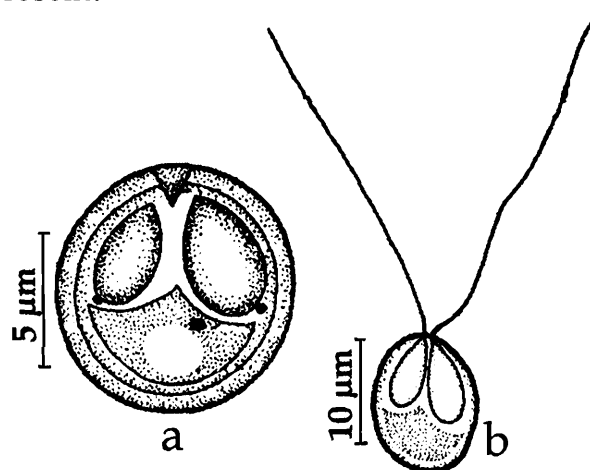


Fig. 151. *Myxobolus lalithae* : a. Fresh spore valvular view, b. Spore with extruded polar filament

152. *Myxobolus lizae* (Narasimhamurti and Kalavati, 1979) emend. Landsberg and Lom, 1991
(Syn. *Myxosoma lairdi* Narasimhamurti and Kalavati, 1979a)
(Fig. 152 a-c)

Diagnosis : Trophozoites opaque, white, spherical, 1.5–3.0 μm , attached to the outer wall of the intestine; spores pear-shaped in valvular view; outer mucus envelop forming 2 prominent lateral lappets on either side; shell valves smooth, equal; sutural line faint; polar capsules 2, equal, parallel to each other, pear-shaped with long neck; a characteristic deeply stained dot seen at the site of capsular foramina; polar filament forming 5–7 coils while inside the capsule; sporoplasm dumb-bell-shaped, iodophilous vacuole not seen.

Size : Spore length 4.6–5.2 (4.9) μm , width 9.0–9.5 (9.3) μm ; polar capsule length 3.0–4.6 (3.2) μm , width 1.8–2.6 (2.0) μm ; polar filament length 50–60 (56.5) μm .

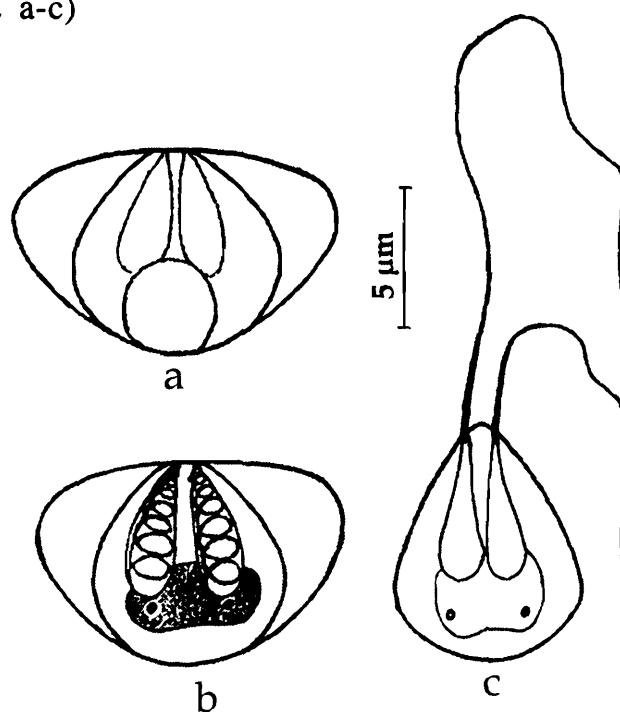


Fig. 152. *Myxobolus lizae* : a. Fresh spore valvular view, b. Spore stained with Giemsa, c. Spore with extruded polar filament

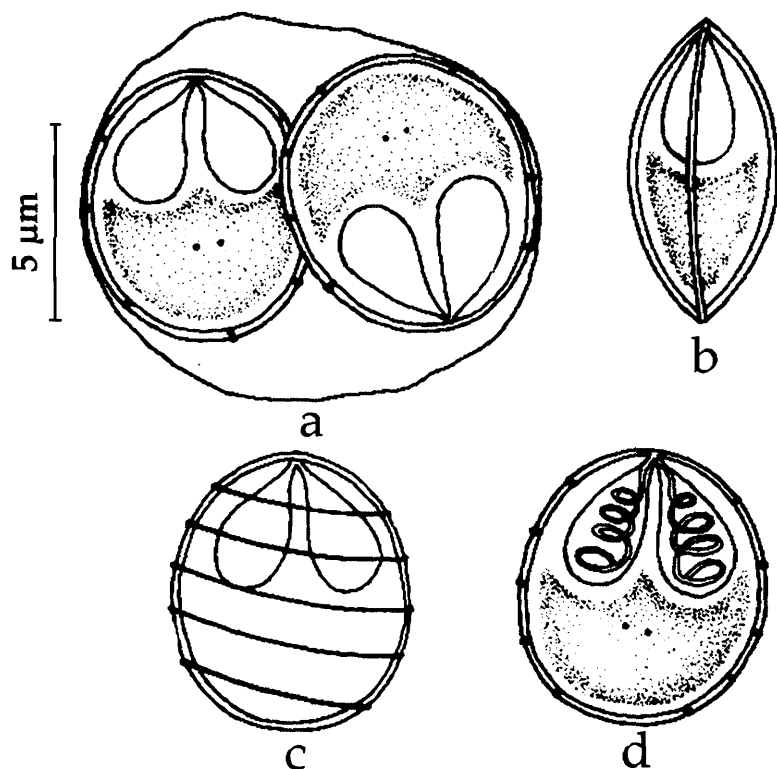
Host : *Liza macorlepis*; *site of infection* : intestinal wall; *pathogenicity* : not apparent.

Distribution : India : Andhra Pradesh (Bheemunipatnam and Visakhapatnam, Visakhapatnam district, Kakinada, East Godavari district).

Remarks : Gupta and Khera (1988b) changed the species *Myxosoma lairdi* to the genus *Myxobolus* naming it as *Myxobolus lairdi*. Later, Landsberg and Lom (1991) emended it as *Myxobolus lizae* since *Myxobolus lairdi* is a preoccupied name (Moser and Noble, 1977).

153. *Myxobolus macrolepi* Padma Dorothy and Kalavati, 1992b
(Fig. 153 a-d)

Diagnosis : Trophozoites opaque, white, spherical 188-200 μm ; pansporoblast disporous; spores oval or spherical; shell valves equal, symmetrical; 5 widely spaced diagonal striations extend between lateral walls; sutural line bent; polar capsules 2, equal, pyriform, convergent; polar filaments forming 3-4 coils while inside the capsule, unequal, thin when fully extended; sporoplasm oval, in the posterior part of the spore; iodophilous vacuole absent.



Size : Spore length 5.2-6.9 (6.28) μm , width 4.3-6.9 (5.26) μm ; polar capsule length 1.72-3.44 (2.78) μm , width 1.72-2.58 (2.0) μm ; polar filament (long) length 14.4-17.6 (15.62) μm , Polar filament (short) length 8.0-11.2 (10.34) μm .

Host : *Liza macrolepi*; *site of infection* : intestine; *pathogenicity* : hypertrophy and rupture of epithelial cells in the intestinal villi reported.

Distribution : India : Andhra Pradesh (Bheemunipatnam, Visakhapatnam district); Kerala (Velli Lake).

Remarks : Krishnakumar (2000) recorded this species from Kerala.

Fig. 153. *Myxobolus macrolepi* : a. Sisorous trophozoite, b. Fresh spore sutural view, c Spore surface view, d. Spore stained with Giemsa

154. *Myxobolus magauddi* (Bajpai, Haldar and Kundu, 1981) emend. Gupta and Khera, 1988b
 (Syn. *Myxosoma magauddi* Bajpai, Haldar and Kundu, 1981)
 (Fig. 154 a-d)

Diagnosis : Trophozoites white, spherical; spores oval in valvular view, lenticular in sutural view; shell valves smooth; sutural line straight, inner wall of the valves showed a triangular projection at the anterior end; polar capsules unequal, pear-shaped; polar filament forming 6-7 coils inside the capsule; sporoplasm granular, binucleate, occupying the entire extracapsular spore cavity; iodophilous vacuole absent.

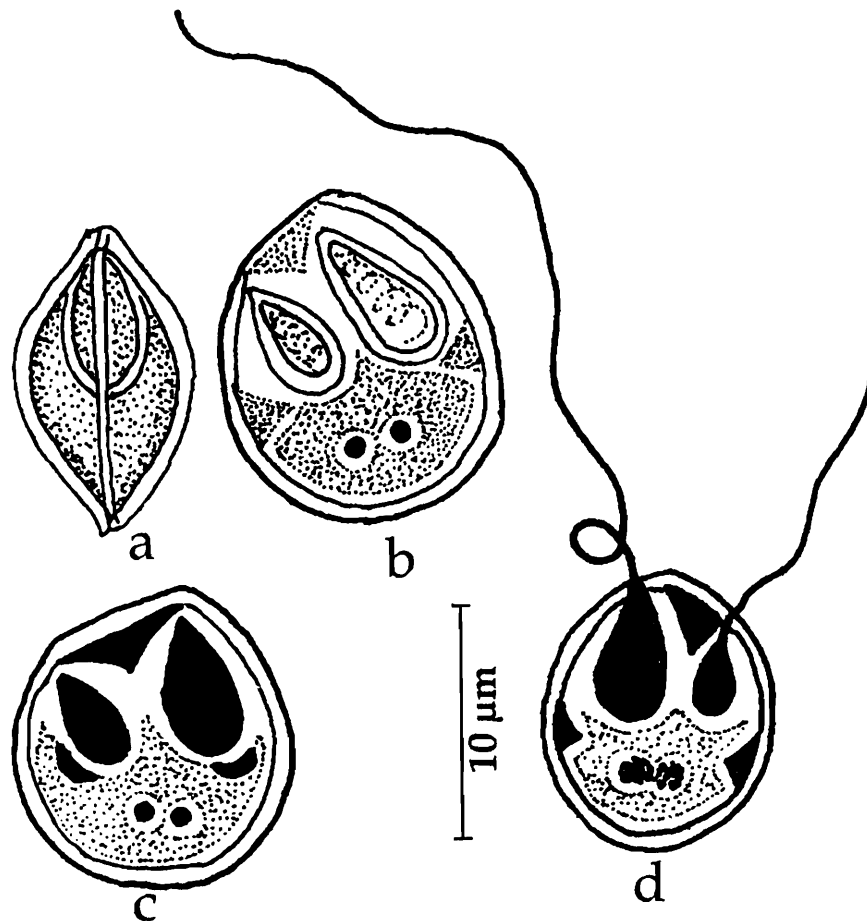


Fig. 154. *Myxobolus magauddi* : a. Fresh spore sutural view, b. Spore stained with Giemsa, c Spore treated with iodine, d. Spore with extruded polar filament

Size : Spore length 10.8–11.7 (11.2) μm , width 8.3–10.0 (9.2) μm ; polar capsule (large) length 3.3–5.0 (4.0) μm , width 2.5–3.3 (3.0) μm ; polar capsule (small) length 2.5–3.3 μm (2.6), width 1.7–2.5 (1.8) μm ; polar filament length-long 18.2–42.5 (31.0) μm , small 8.3–10.8 (9.3) μm .

Host : *Trichogaster fasciatus*; **site of infection :** branchial filaments; **pathogenicity :** not apparent.

Distribution : India : West Bengal (Ranaghat, Nadia district).

155. *Myxobolus magurii*, Sarkar, 1993

(Fig. 155 a-b)

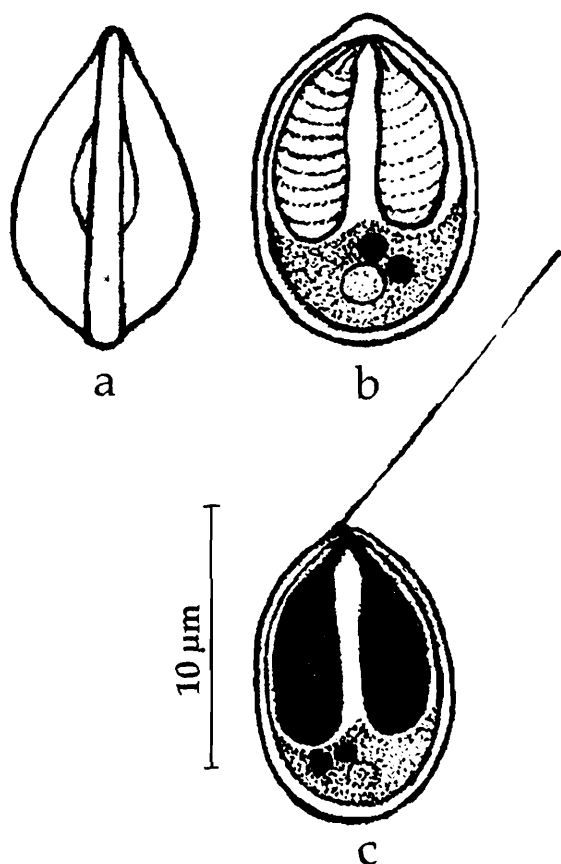


Fig. 155. *Myxobolus magurii* : a. Fresh spore valvular view, b. Spore stained with Giemsa, c. Spore treated with iodine, d. Spore with extruded polar filament

Diagnosis : Trophozoites small, round, creamy white in colour with 2-4 spores; spore broadly ellipsoidal in valvular view, lenticular in sutural view with compressed anterior end; anterior end acuminate, posterior end broadly rounded; shell valves thick, smooth, sutural line broad, straight, ridged; polar capsules equal, narrow, elongated, banana-shaped, parallel to each other occupying more than half the spore cavity; polar filament making 7-9 horizontal coils while inside the capsule; sporoplasm granulated, binucleate; iodophilous vacuole present.

Size : Spore length 13.0–15.00 (14.13) μm , width 6.5–8.0 (7.75) μm ; polar capsule length 7.0–8.0 (7.53) μm , width 2.0–3.0 (2.34) μm .

Host : *Clarias magur (batrachus)* Linn : **site of infection** : arborescent organ (accessory respiratory organ); **pathogenicity** : not apparent.

Distribution : India : West Bengal (Chinsurah, Hugli district).

156. *Myxobolus mahendrae* Sarkar, 1986a

(Fig. 156 a-c)

Diagnosis : Trophozoites 2.0–3.0 mm in size; spores cylindrobiconical; valves smooth, refractile, double-layered; sutural line slightly curved; polar capsules unequal, dissimilar; large capsule pyriform, subterminal, with 6-7 coils of the polar filament inside the capsule; long and thin when extended; smaller polar capsule terminal, polar filament making 4–5 coils while inside the capsule; polar filament small, deeply stained; sporoplasm half-moon shaped, occupying the entire extracapsular spore cavity; iodophilous vacuole spherical 1.0–1.6 μm .

Size : Spore length 11.52–13.96 (12.7) μm , width 9.77–10.47 (9.2) μm ; polar capsule (large) length 6.28–7.33 (6.98) μm , width 3.49–4.19 (3.73) μm ; polar capsule (small) length 4.19–6.98 (5.44) μm , width 3.14–3.49 (3.42) μm .

Host : *Catla catla*; *site of infection* : gill rachii; *pathogenicity* : retarded growth.

Distribution : India : West Bengal (Chinsurah, Hugli district); Andhra Pradesh (Vogaruvagu, Chilakaluripet, Guntur district), Punjab (Harike).

Remarks : The species has been reported widely from different states of the country but with considerable variation in spore morphometrics. Lakshminarayana (1988) reported this species from the same host from different regions in Andhra Pradesh, while Gupta and Khera (1990) recorded this species from Harike Lake in Punjab where the spores are relatively smaller in size.

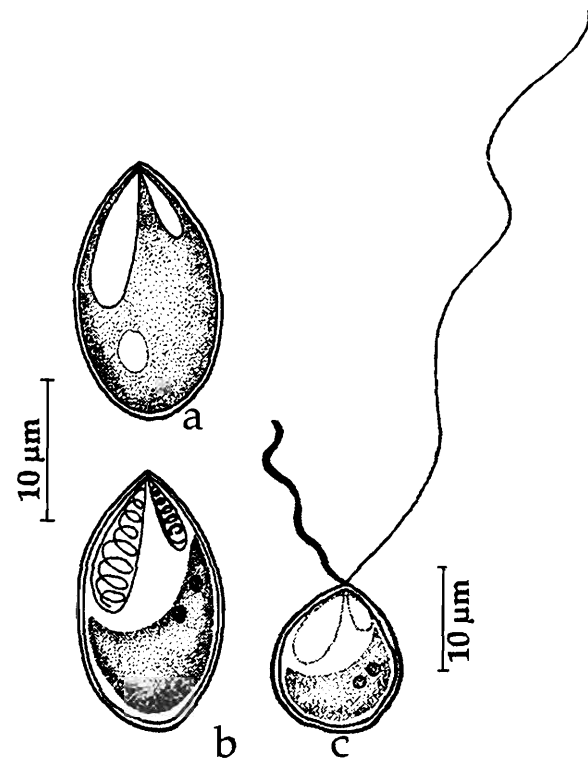


Fig. 156. *Myxobolus mahendrae* : a. Fresh spore valvular view, b. Spore stained with Giemsa, c. Spore with extruded polar filament

157. *Myxobolus manoramae* Basu and Haldar, 2002b
(Fig. 157 a-d)

Diagnosis : Trophozoites small, round, creamy white in colour, 200–310 µm in size; spores pyriform in valvular view, anterior end blunt and narrow, posterior end round; shell valves thick; sutural ridge distinct; polar capsules either equal or unequal, pyriform, subterminal; when equal occupying half the length of the spore; large capsule

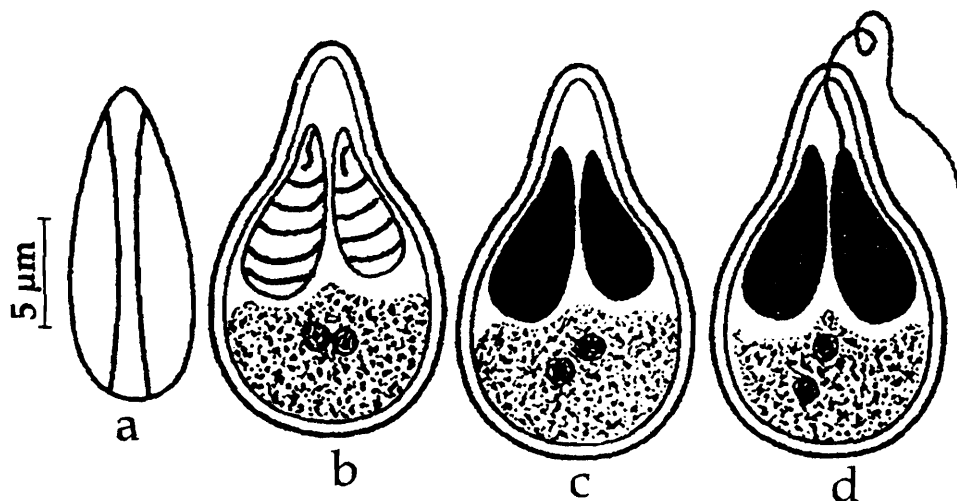


Fig. 157. *Myxobolus manoramae* : a. Fresh spore sutural view, b. Spore valvular view, c. Spore stained with Giemsa, d. Spore with extruded polar filament

with 5-6 coils of the polar filament inside the capsule; polar filament short and uniform when extended; smaller polar capsule with 4-5 coils of polar filament; sporoplasm granular, homogenous filling the cup-shaped extracapsular spore cavity below the capsules; iodophilous vacuole absent.

Size : Spore with equal polar capsules : length 10.7-13.1 (11.8) μm , width 4.8-6.3 (5.6) μm ; polar capsule length 5.5-6.6 (6.2) μm , width 2.0-2.5 (2.2) μm ; polar filament 10.2 μm . Spore with unequal polar capsules : length 10.6-12.5 (11.5) μm , width 4.8-6.3 (5.7) μm ; polar capsule (large) length 5.8-6.5 (6.1) μm , width 2.0-2.5 (3.73) μm ; polar capsule (small) length 4.5-5.9 (5.44) μm , width 1.9-2.1 (2.0) μm .

Host : *Catla-Rohu* hybrid; *site of infection* : tail fins; *pathogenicity* : not apparent.

Distribution : India : West Bengal (Ranaghat, Nadia district).

Remarks : Occurrence of 2 different populations in the same plasmodium, identified by the variations in the size of the spore and polar capsules seem to be an unique character of the species.

158. *Myxobolus maruliensis* (Sarkar, Mazumdar and Pramanik, 1985) emend. Gupta and Khera, 1988b
(Syn. *Myxosoma maruliensis* Sarkar *et al.*, 1985)
(Fig. 158 a-d)

Diagnosis : Spore pyriform or planoconvex in valvular view; anterior end pointed, posterior end truncated; valves thin, smooth; sutural line thin slightly bent with minute anterior orifice; polar capsules equal, elongated, tubular; polar filament making 9-11 coils

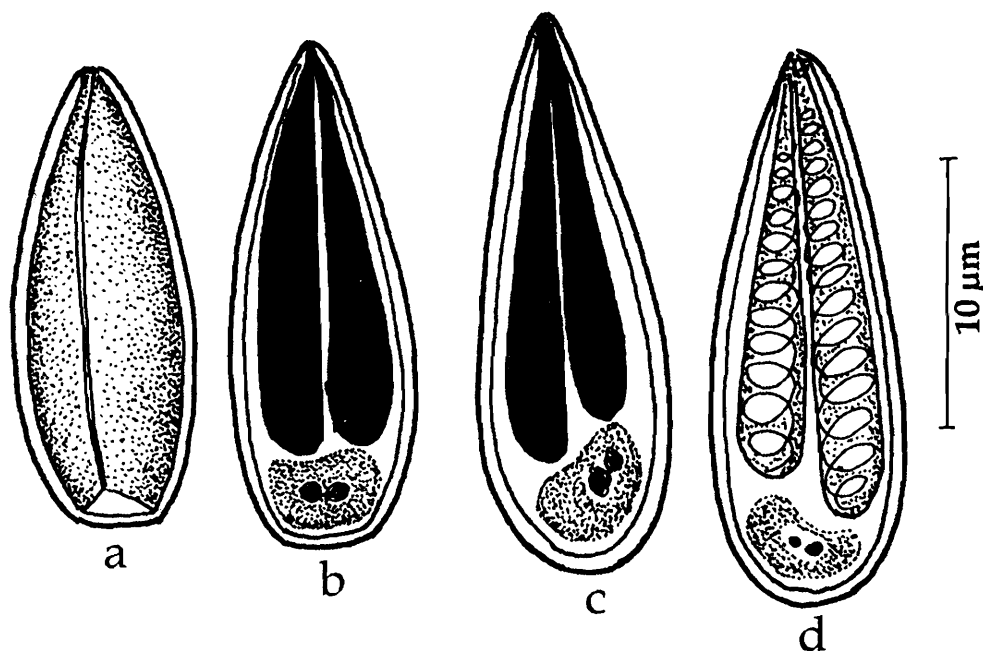


Fig. 158. *Myxobolus maruliensis* : a. Fresh spore valvular view, d. Spore with equal polar capsules, c. Spore with unequal polar capsules, d. Spore with extruded polar filament

while inside the capsule; sporoplasm granulated, binucleate; iodophilous vacuole absent, some spores with unequal polar capsules also reported.

Size : Spore length 12.0–17.5 (14.37) μm , width 2.5–5.0 (4.23) μm ; polar capsule length 7.5–13.0 (10.05) μm , width 1.0–2.0 (1.55) μm .

Host : *Channa marulius*; *site of infection* : kidney; *pathogenicity* : not apparent.

Distribution : India : West Bengal (Islampur, Mushirabad district).

159. *Myxobolus mathuri* Jayasri, Parvateesam and Mathur, 1981
(Fig. 159 a-b)

Diagnosis : Spore oval to pyriform in valvular view, lenticular in sutural view; anterior end pointed, posterior end slightly thickened; valves thin, smooth; polar capsules unequal, pyriform; polar filament making 8-9 coils while inside the large capsule and 3-4 coils inside the smaller capsule; sporoplasm granulated, binucleate; iodophilous vacuole very small; intercapsular ridge absent.

Size : Spore length 8.7–23.5 μm , width 5.1–10.1 μm ; polar capsule (large) length 2.7–11.9 μm , width 1.8–4.6 μm ; polar capsule (small) length 2.7–7.8 μm , width 1.8–4.6 μm .

Host : *Puntius sarana* (Ham.); *site of infection* : gills; *pathogenicity* : not apparent.

Distribution : India : Rajasthan : (Parvatsar Lake).

Remarks : Gupta and Khera (1988) while reviewing the genus *Myxobolus* corrected the spelling of *M. mathurii* Jayasri *et al.* 1981 as *M. mathuri* following the Articles 31 and 32(c) of International Code of Zoological Nomenclature.

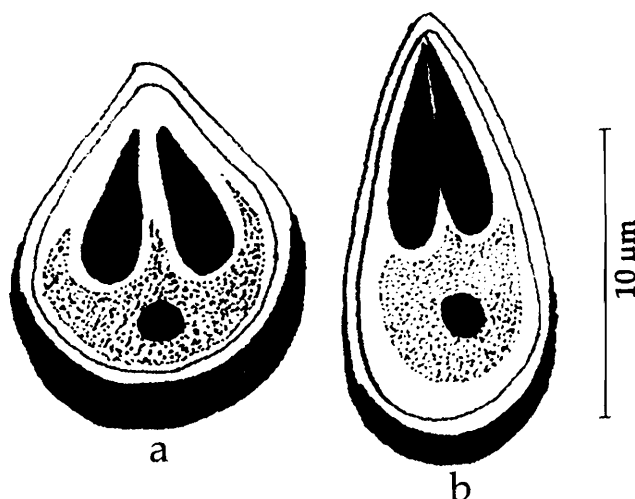


Fig. 159. *Myxobolus mathuri* : a & b. Spores valvular view

160. *Myxobolus meglitschus* Sarkar, 1996b
(Fig. 160 a-d)

Diagnosis : Cysts small, spherical or oval, 90.0–100.0 μm x 45.0 μm ; spore small, ellipsoidal to oval in valvular view, lenticular in sutural view; shell valves thick, symmetrical, smooth; sutural line broad, straight; polar capsules equal, pyriform, distinct; polar filament making 5-7 coils while inside the capsule; inter capsular ridge spine-like between the polar capsules; sporoplasm finely, granulated, binucleate; iodophilous vacuole absent.

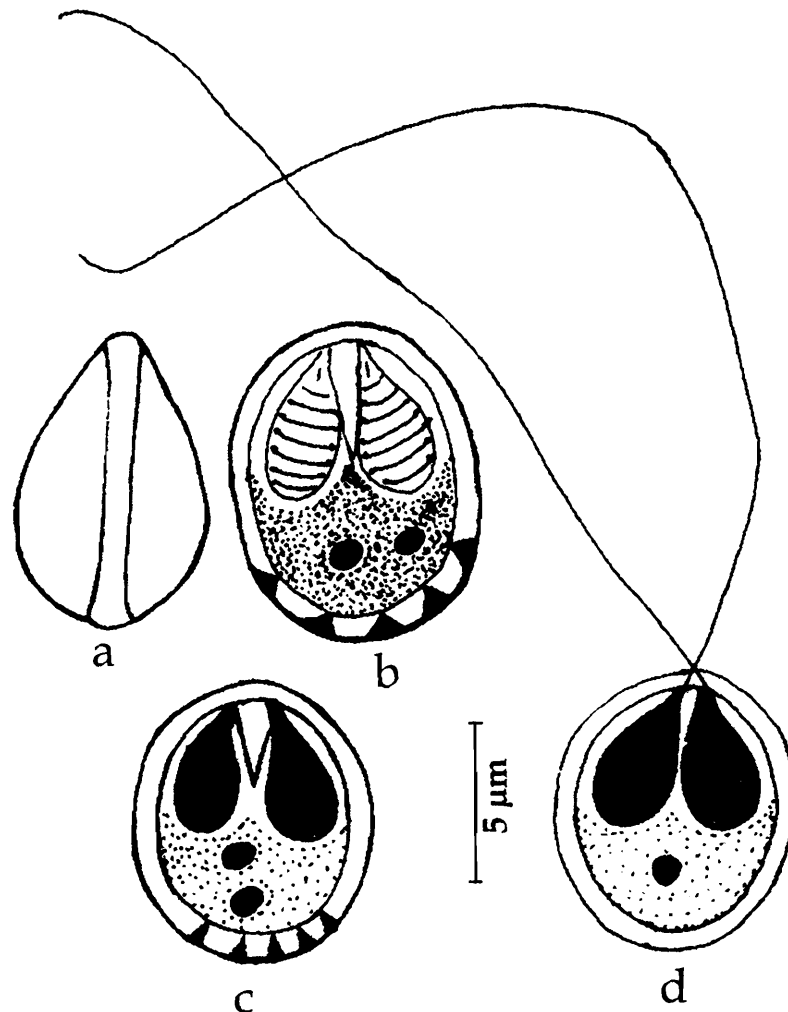


Fig. 160. *Myxobolus meglitschus* : a. Fresh spore sutural view, b & c. Spore stained with Giemsa, c. Spore with extruded polar filament

Size : Spore length 8.0–9.5 (8.8) μm , width 6.0– 7.5 (6.96) μm ; polar capsule length 3.5–5.0 (4.42) μm , width 1.5–3.0 (2.07) μm .

Host : *Notopterus notopterus* (Pallas); *site of infection* : lamellar epithelium of gills; *pathogenicity* : not apparent.

Distribution : India : West Bengal (Hugli district).

161. *Myxobolus molae* Sarkar, 1993
(Fig. 161 a-b)

Diagnosis : Spore oval in valvular view, lenticular in sutural view; anterior end pointed, posterior end broadly rounded; shell valves moderately thick, smooth; sutural line broad, flat, straight; polar capsules equal, broadly pyriform with a very distinct anterior long neck, convergent; polar filament making 4–6 horizontal coils while inside the capsule; intercapsular appendix short and sharply pointed; sporoplasm granulated, binucleate; iodophilous vacuole present.

Size : Spore length 8.5–9.5 (9.00) μm , width 7.0–8.5 (7.4) μm ; polar capsule length 5.0–6.5 (6.00) μm , width 3.8–4.5 (1.55) μm .

Host : *Amblypharyngodon mola*; **site of infection** : kidney; **pathogenicity** : not apparent.

Distribution : India : West Bengal (Chinsurah, Hugli district).

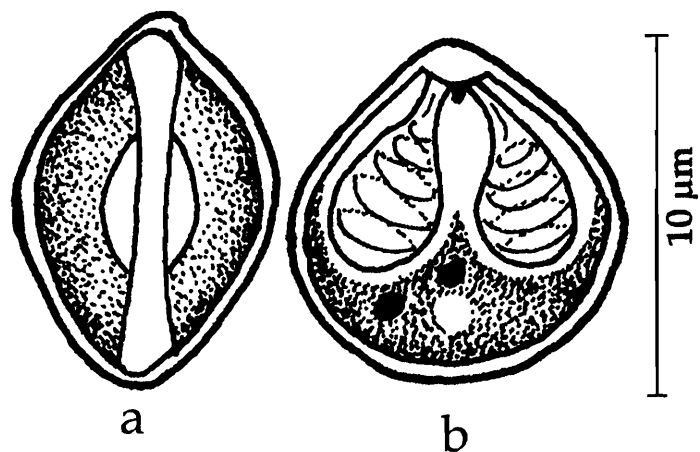


Fig. 161. *Myxobolus molae* : a. Fresh spore sutural view, b. Spore stained with Giemsa

162. *Myxobolus mrigalae* Chakravarty, 1939
(Fig. 162 a-c)

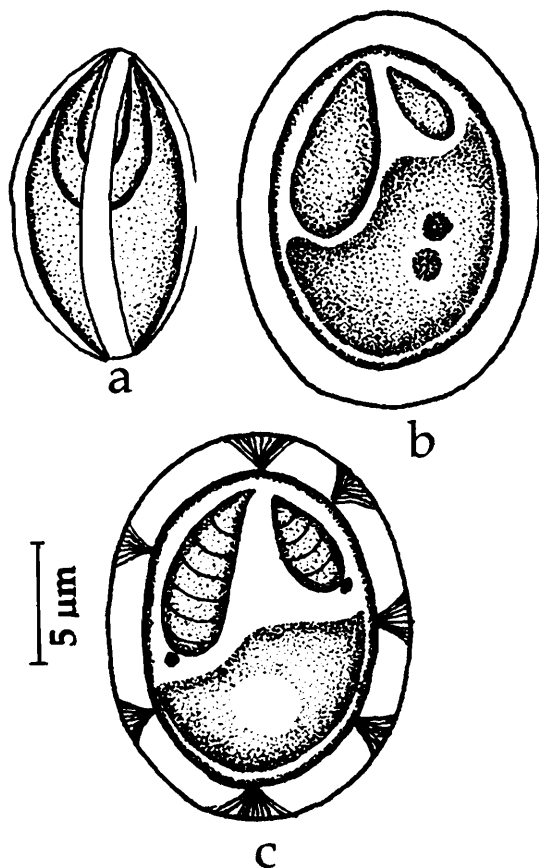


Fig. 162. *Myxobolus mrigalae* : a. Fresh spore sutural view, b. Spore valvular view, c. Spore stained with Giemsa

Diagnosis : Cysts oval, opaque white in colour, 0.75–1.5 mm x 0.75–1.0 mm, polysporous; spore spherical or slightly oval in front view, lenticular in lateral view; shell somewhat thick; valves symmetrical with several triangular markings; sutural ridge unequal; sutural line indistinct; polar capsules pyriform, unequal; sporoplasm located posteriorly; iodophilous vacuole spherical, 3.1 μm in diameter; polar filament unequal.

Size : Spore 17.21–8.24 μm in diameter; polar capsule (large) length 5.15 μm , width 3.09 μm ; polar capsule (small) length 3.09 μm , width 2.06 μm .

Host : *Cirrhinus mrigala* (Ham.); **site of infection** : scales; **pathogenicity** : not apparent.

Distribution : India : West Bengal (Calcutta district).

Remarks : Sarkar (1946) reported heavy infestation with *Myxobolus mrigalae* in evidently healthy and normal fry of *Cirrhina mrigala* from Kalighat Fish Fry Market at Calcutta. The cysts, forming small white patches, were found all over the body except head region.

163. *Myxobolus mrigalhitae* Basu and Haldar, 2003a
(Fig. 163 a-c)

Diagnosis : Developing plasmodia round attached to gill filaments; pansporoblast disporous; immature spores round or spherical; mature spores pyriform, valves thin anteriorly and thick posteriorly; sutural ridge broad straight, median; 2-5 parietal folds seen in the posterior region of the spore; polar capsules unequal; larger capsule pyriform with 5-6 coils of the polar filament inside; filament extruded from the anterior end; smaller capsule tear-shaped, with 3-4 coils, filament extruding anterolaterally; 2 capsular foramina; sporoplasm granular, homogenous filling the extracapsular space; iodophilous vacuole present.

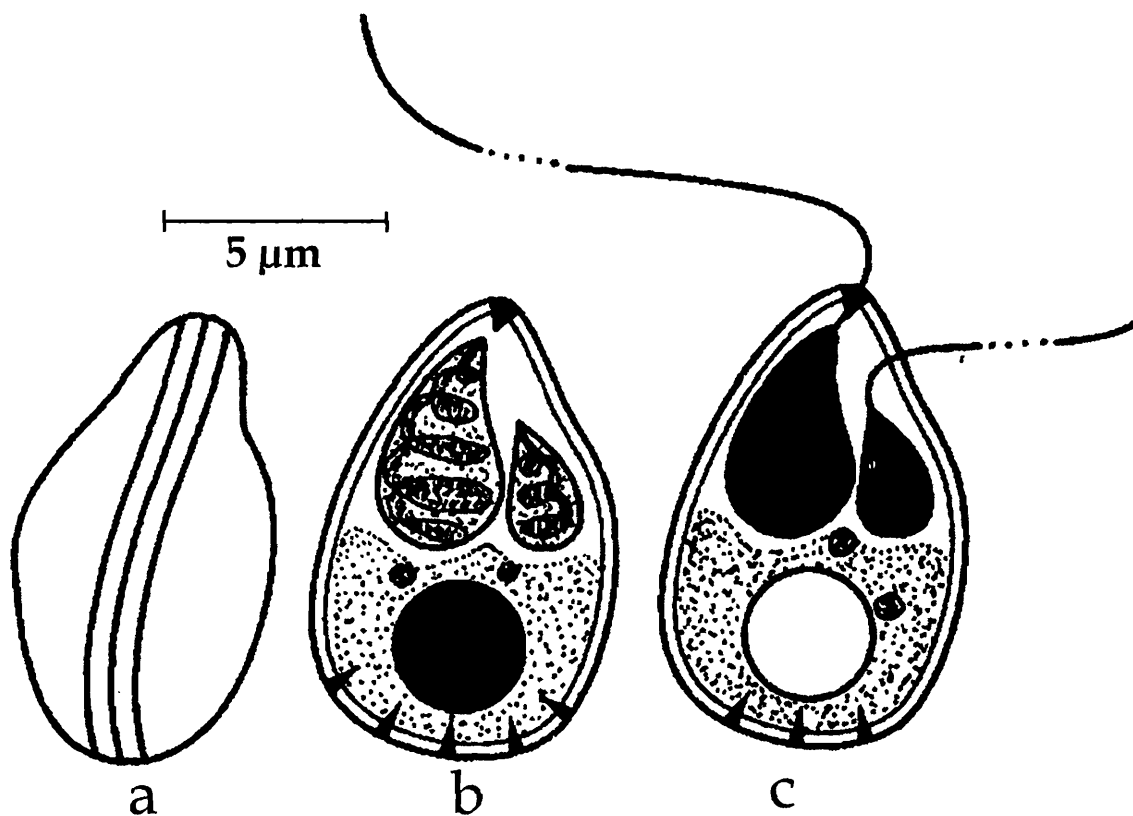


Fig. 163. *Myxobolus mrigalhitae* : a. Fresh spore sutural view, b. Spore stained with Giemsa, c. Spore with extruded polar filament

Size : Spore length 10.8-11.3 (10.8) μm , width 7.6-8.1 (7.9) μm ; polar capsule (large) length 4.3-5.2 (4.8) μm , width 2.7-3.2 (2.1) μm ; polar capsule (small) length 2.9-3.2 (3.0), width 2.0-3.2 (2.1) μm ;

Host : *Cirrihina mrigala* - *Labeo rohita* hybrid; **site of infection :** gills; **pathogenicity :** not apparent.

Distribution : India : West Bengal (Kalna, Burdwan).

164. *Myxobolus mugcephalus* (Narasimhamurti, Kalavati and Saratchandra, 1980)
emend. Landsberg and Lom, 1991

(Syn. *Myxosoma microspora* Narasimhamurti *et al.*, 1980)

(Fig. 164 a-c)

Diagnosis : Trophozoites opaque, white, spherical, 0.5-1 mm in diameter; pansporoblast disporous; spores spherical or slightly oval with outer mucus membrane having two protuberances in equatorial axis; shell valves smooth, equal; sutural line thick, straight; polar capsules 2, pyriform, equal, terminal; polar filament making 5-6 loose coils while inside the capsule; sporoplasm homogeneous, bean-shaped, below the capsule; iodophilous vacuole absent.

Size : Spore 4.8-5.2 (5.1) μm in diameter; polar capsule length 1.6-2.0 (1.8) μm , width 1.0-1.2 (1.1) μm ; polar filament length 22-28 (26) μm .

Host : *Mugil cephalus*; **site of infection :** gill filaments; **pathogenicity :** not apparent.

Distribution : India : Andhra Pradesh, (Visakhapatnam district), Orissa : (Chilka lake).

Remarks : Gupta and Khera (1988) transferred this species to genus *Myxobolus* naming it as *Myxobolus microspora*. Later, Landsberg and Lom (1991) renamed this species as *Myxobolus mugcephalus* since the species name *microspora* is preoccupied by *Myxobolus microspora* Li and Nie in Chen (1973).

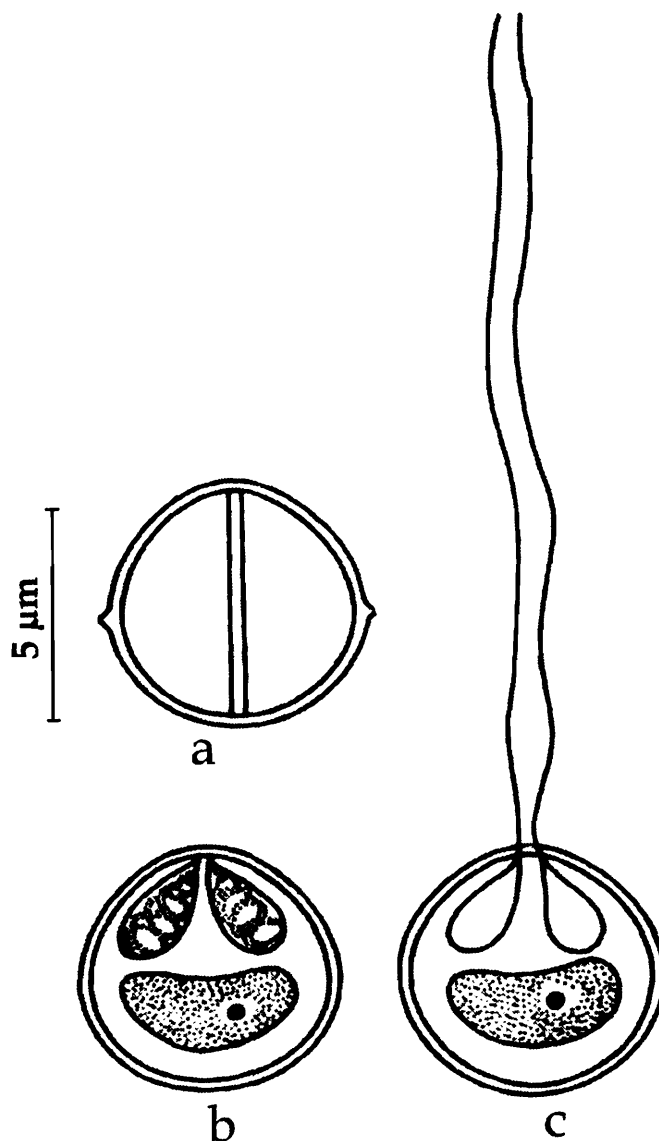


Fig. 164. *Myxobolus Mugcephalus* : a. Fresh spore valvular view, b. Spore stained with Giemsa, c. Spore with extruded polar filament

165. *Myxobolus mugilii* Haldar, Samal and Mukhopadhyay, 1996
(Fig. 165 a-b)

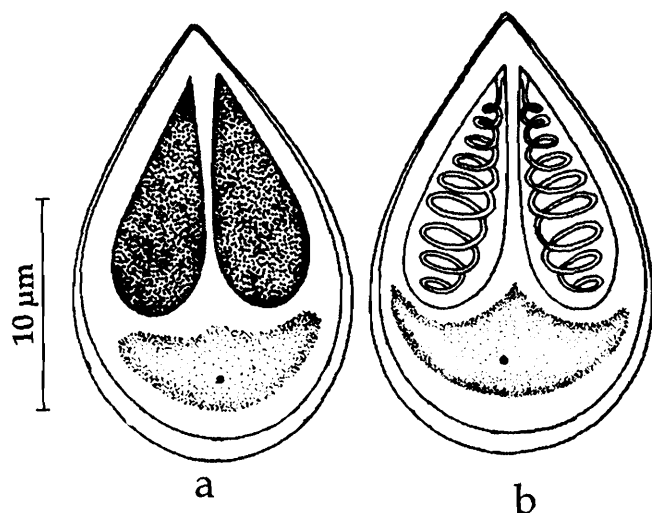


Fig. 165. *Myxobolus mugilii* : a. Fresh spore valvular view, b. Spore stained with Giemsa

Diagnosis : Spore ovoid; pointed anteriorly, broadly rounded posteriorly; valves symmetrical, uniformly thick; intercapsular ridge absent; polar capsules equal, pyriform, projected anteriorly; sporoplasm cup-shaped, binucleate; iodophilous vacuole present.

Size : Spore length 8.1–16.3 µm, width 4.0–7.3 µm; polar capsule length 2.4–8.1 µm.

Host : *Mugil cephalus*; **site of infection** : gills; **pathogenicity** : not apparent.

Distribution : India : Orissa (Chilka Lake).

166. *Myxobolus multivaderis* Mukhopadhyay and Haldar, 1998
(Fig. 166 a-c)

Diagnosis : Spores encountered in different organs exhibiting variability in shape and structure; in gills spore round, anterior end pointed; polar capsules equal; in palate spore more or less spherical, anterior end with beak-like prolongation; polar capsules unequal; polar filaments forming 8 coils in larger and 6 coils in smaller capsule; in intestine spore spherical, polar capsules unequal, located at an acute angle with each other; sporoplasm binucleate, granular filling the entire extra capsular region; iodophilous vacuole present.

Size : Spore in gills : length 4.98–6.64 (5.519) µm, width 3.32–4.15 (3.44) µm; polar capsule length 1.66–3.32 (3.029) µm, breadth 0.83–1.66 (1.577) µm; On palate : spore length 8.47–10.28 (8.98) µm, width 6.05–7.26 (6.77) µm; polar capsule (large) length 3.66–5.44 (4.837) µm, breadth 2.42–4.23 (3.508) µm; polar capsule (small)

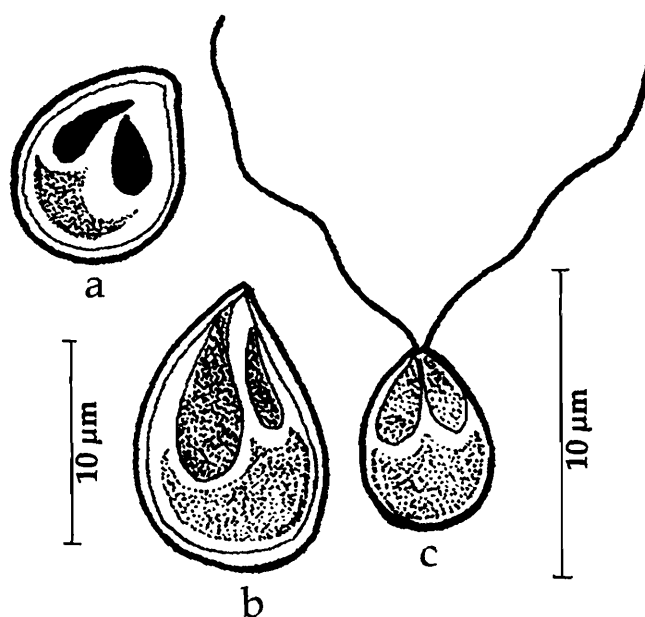


Fig. 166. *Myxobolus multivaderis* : a & b. Fresh spores valvular view, c. Spore with extruded polar filament

length 1.21-3.63 (2.448) μm , breadth 1.21-2.42 (1.752) μm ; in intestine : spore length 6.65-9.68 (8.35) μm , width 4.23- 6.05 (5.049) μm ; polar capsule (large) length 1.81-2.42 (4.902) μm , breadth 0.6-1.81 (1.269) μm ; polar capsule (small) length 0.6-1.81 (1.147) μm , breadth 0.36-1.21 (1.17) μm ; in brain tissue : spore length 4.98-8.3 (6.88) μm , width 3.32-6.64 (5.14) μm ; polar capsule (large) length 2.49-5.81 (4.837) μm , breadth 0.83-1.66 (1.45) μm ; polar capsule (small) length 1.66-3.32 (2.57) μm , breadth 0.83-1.66 (1.12) μm .

Host : *Catla catla*; *site of infection* : gills, palate, intestine and brain tissue; *pathogenicity* : not apparent.

Distribution : India : West Bengal (Kalyani, Nadia district).

167. *Myxobolus mystusius* Sarkar, 1986a

(Fig. 167 a-c)

Diagnosis : Spore histozoic; almost lenticular with straight thin suture in sutural view and broadly pyriform with rounded posterior and sharply-pointed anterior tip in valvular view; valves two, symmetrical and thin-walled; polar capsules two, convergent, unequal; larger capsule broadly pyriform, polar filament forming 8-9 coils in side the capsule, smaller polar capsule narrowly pyriform, with 3-4 coils of the polar filament inside; polar filament extruded only from larger capsule, flat, ribbon-like; sporoplasm finely granular and binucleate; iodophilous vacuole small.

Size : Spore length 12.23-13.96 (13.18) μm , width 8.73-10.47 (9.39) μm ; polar capsule (large) length 6.28-7.68 (7.12) μm , width 2.79-4.19 (3.59) μm ; polar capsule (small) length 3.49-4.19 (4.05) μm , width 1.4-1.75 (1.33) μm ; polar filament length 16-20 μm .

Host : *Mystus vittatus*; *site of infection* : scale; *pathogenicity* : not apparent.

Distribution : India : West Bengal (Chinsurah, Hugli district).

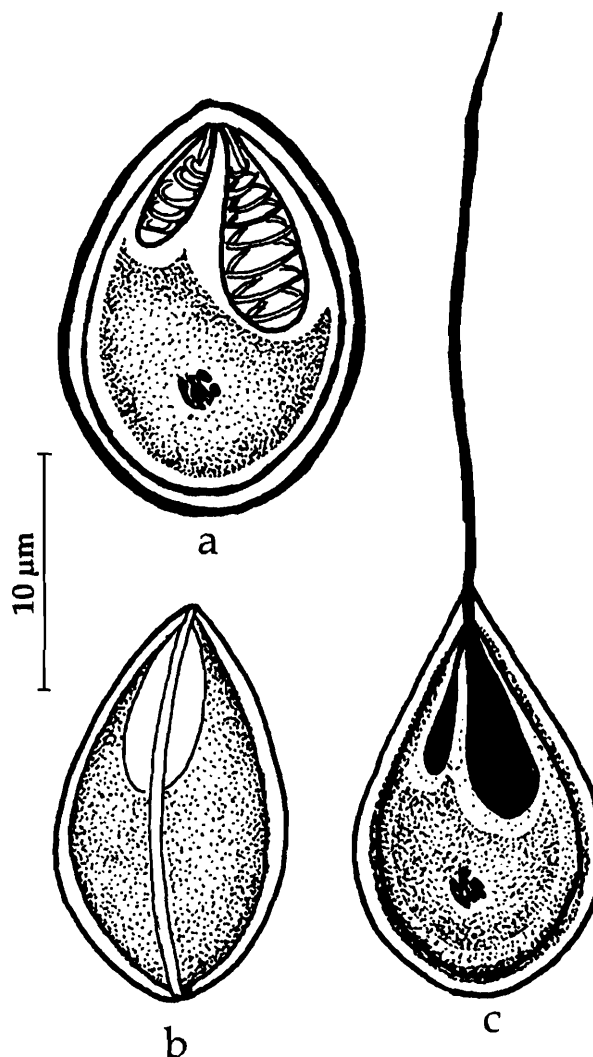


Fig. 167. *Myxobolus mystusius* : a. Fresh spore sutural view, b. Spore stained with Giemsa, c. Spore with extruded polar filament

168. *Myxobolus narasii* (Narasimhamurti, 1970) emend. Landsberg and Lom, 1991
(Syn. *Myxosoma intestinalis* Narasimhamurti, 1970)
(Fig. 168 a-c)

Diagnosis : Trophozoites spherical, about 2.0 mm, attached to intestinal wall; spore oval, longer than wide; valves thin, equal, symmetrical; sutural line fine, sutural ridge narrow; polar capsules 2, equal, sub-terminal, pear-shaped; polar filament thin and uniform, making 4-5 coils while inside the capsule; iodophilous vacuole absent.

Size : Spore length 12.5-13.5 (12.8) μm , width 8.6-9.5 (9.0) μm ; polar capsule length 2.9-3.6 (3.2) μm , width 1.6-1.8 (1.7) μm ; polar filament length 30-45 (42.5) μm .

Host : *Mugil waigensis*; **site of infection :** intestine; **pathogenicity :** not apparent.

Distribution : India : Andhra Pradesh (Fish market at Bheemunipatnam and Visakhapatnam, Visakhapatnam district)

Remarks : While synonymising Genus *Myxosoma* and *Myxobolus* Gupta and Khera (1988) renamed *Myxosoma intestinalis* Narasimhamurti, 1970 as *Myxobolus intestinalis*. Since the species name was preoccupied by *Myxobolus intestinalis* Kudo, 1929, Landsberg and Lom (1991) changed it as *Myxobolus narasii* (an abbreviated form of Narasimhamurti, the author of *Myxosoma intestinalis*).

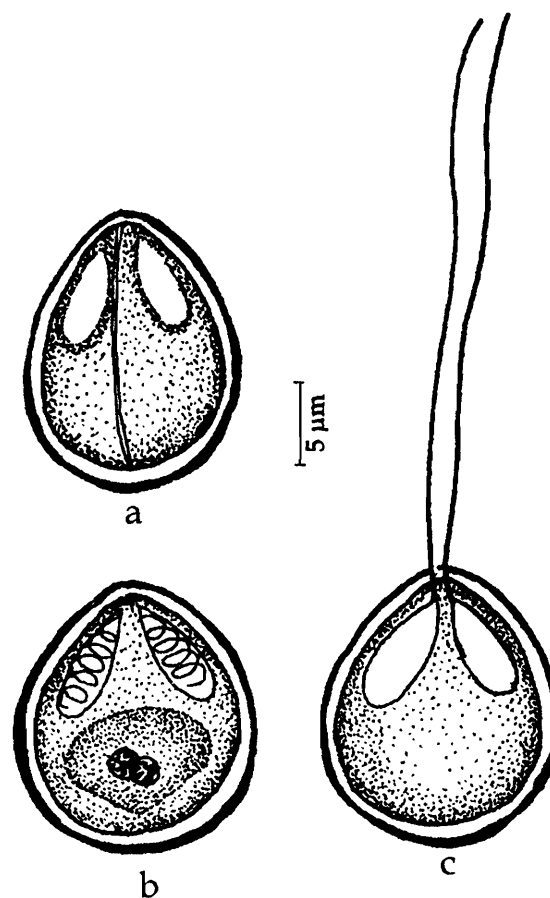


Fig. 168. *Myxobolus narasii* : a. Fresh spore valvular view, b. Spore stained with Giemsa, c. Spore with extruded polar filament

169. *Myxobolus noblei* (Sarkar, 1982) emend. Gupta and Khera, 1988b
(Syn. *Myxosoma noblei* Sarkar, 1982b)
(Fig. 169 a-d)

Diagnosis : Cysts oval or elongated, 121 μm x 98 μm in size; spores elliptical in valvular view and lenticular in sutural view; shell valves thick, with short, blunt posterior extension; sutural line straight; polar capsules pyriform, equal; sporoplasm finely granular uni or binucleate; iodophilous vacuole absent; mucous envelop present.

Size : Spore length 11.5-14.3 (12.7) μm , width 8.3-10.5 (9.5) μm ; polar capsule length 5.8-8.5 (7.0) μm , width 3.0-4.5 (3.7) μm .

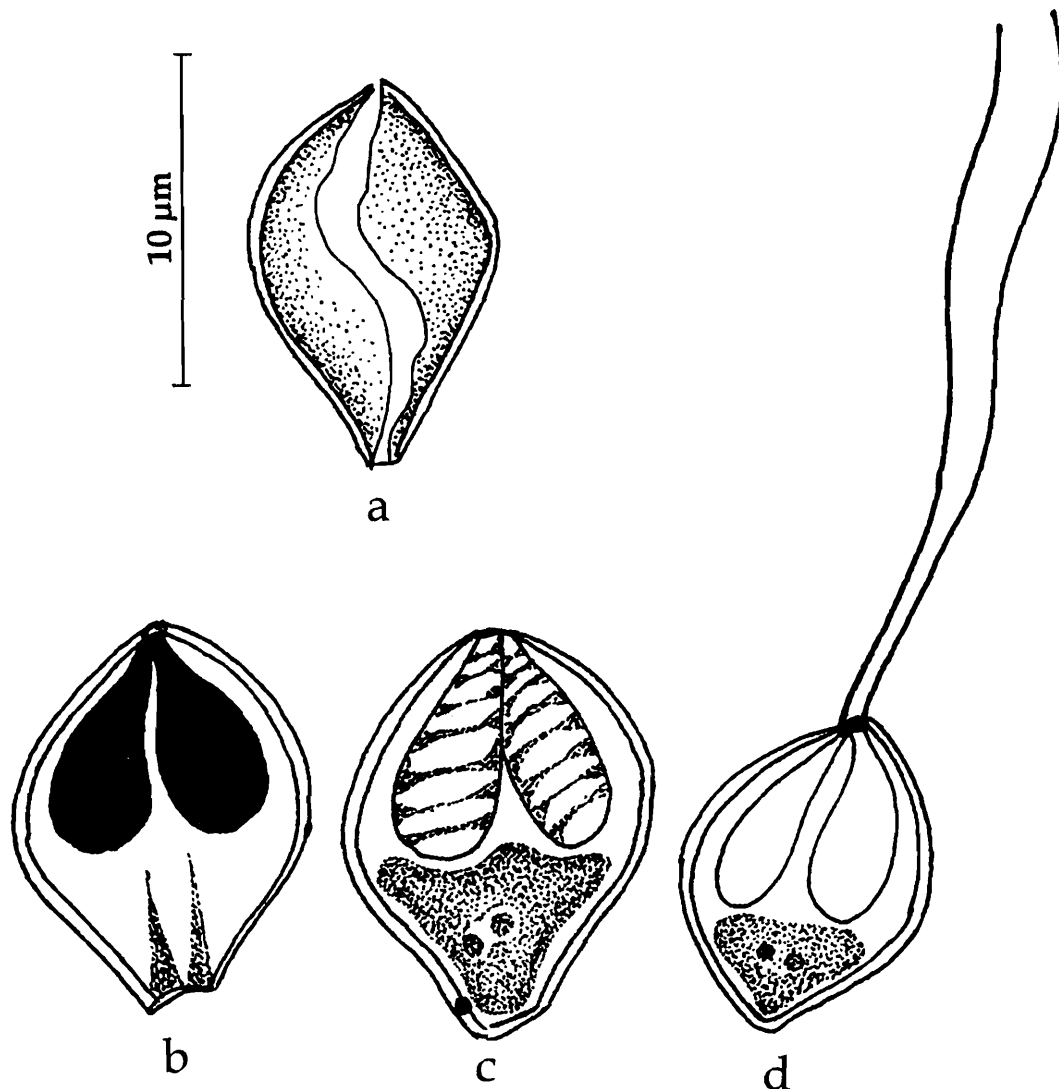


Fig. 169. *Myxobolus noblei* : a. Fresh spore valvular view, b. Spore treated with iodine, c. Spore stained with Giemsa, d. Spore with extruded polar filament

Host : *Ophicephalus striatus*; *site of infection* : gall bladder; *pathogenicity* : not apparent.

Distribution : India : West Bengal (Chinsurah, Hugli district).

170. *Myxobolus nodularis* Southwell and Prashad, 1918
(Fig. 170 a-c).

Diagnosis : Cysts rounded, oval or elongated, white to creamy yellow in colour, 0.26-0.45 mm in size; spores oval to rounded; shell valves smooth; sutural ridge prominent; sutural line straight; polar capsules pyriform, equal, opening independently; polar filament forming 3-5 coils while inside the capsule; intercapsular ridge absent; sporoplasm finely granular, uninucleate.

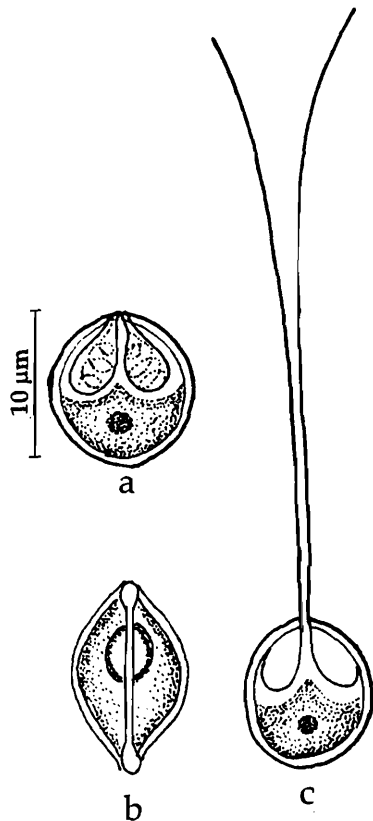


Fig. 170. *Myxobolus nodularis* : a. Fresh spore valvular view, b. Spore sutural view, c. Spore with extruded polar filament

171. *Myxobolus ophthalmasculata*

Basu and Haldar, 2002a

(Fig. 171 a-d)

Diagnosis : Cysts creamy white, spherical to oval, 0.67 -1.0 mm, attached to eye muscle; spore elongated pyriform with a small depression at the anterior end; valves unequal, smooth; sutural ridge undulated; polar capsules unequal; larger polar capsule wide, elongated, pyriform with rounded posterior and nipple-like anterior end, opening anteriorly, polar filament making 7-9 coils while inside the capsule; smaller polar capsule oval or tear-shaped, polar filament making 2-3 coils, opening anterolaterally; no intercapsular ridge or mucous envelop; sporoplasm homogenous, granular, binucleate; iodophilous vacuole present.

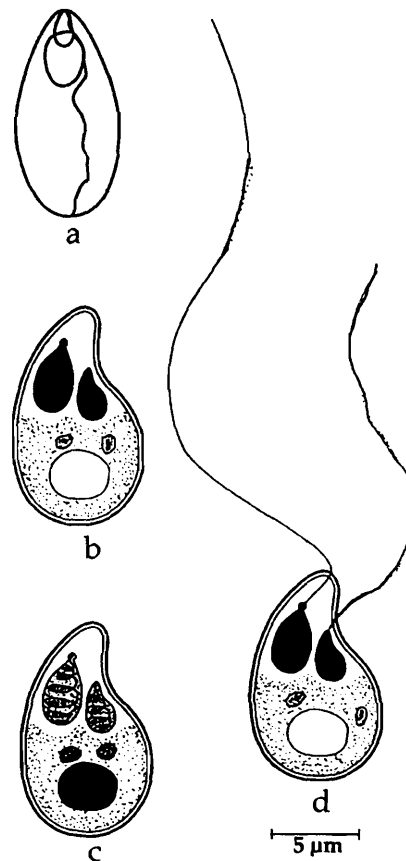


Fig. 171. *Myxobolus ophthalmasculata* : a. Fresh spore sutural view, b. Spore valvular view, c. Spore stained with Giemsa, d. Spore with extruded polar filament

Size : Spore length 6.0–12.0 µm, width 6.0–9.0 µm; polar capsule length 1.85–4.5 µm, width 0.75–3.0 µm.

Host : *Rasbora daniconius* (Hamilton); **site of infection** : fins, muscles, pancreas, intestine, gall bladder; **pathogenicity** : not apparent.

Distribution : India : Kerala (Cannanore, Calicut, Mallapuram district). **Elsewhere** : Bangladesh (Dacca, Mirpur district).

Remarks : Southwell and Prashad (1918) described this species from the same host in Dacca. The parasite encountered in India was found infesting different organs of the host fish and exhibited considerable variation in size in different organs. Spores are also recorded from the metacercaria of *Diplostomum minutum*, a common sterigeoid (Trematoda) parasite of this fish (Rajendran and Janardanan, 1989).

Size : Spore length 12.4–13.97 (13.13) μm , width 7.45– 9.18 (8.04) μm ; polar capsule (large) length 4.9–6.12 (5.47) μm , width 2.65–3.37 (3.06) μm ; polar capsule (small) length 2.35– 3.37 (3.03) μm , width 1.84–2.14 (1.99) μm ; polar filament (long) length, 53.04–114.24 (83.13) μm , polar filament (short) 20.4–32.64 (24.94) μm .

Host : *Cirrhinus mrigala* (Hamilton); **site of Infection** : eye muscles; **pathogenicity** : not apparent.

Distribution : India : West Bengal (Ranaghat, Nadia district).

172. *Myxobolus orissae* Haldar, Samal and Mukhopadhyay, 2002
(Fig. 172 a-c)

Diagnosis : Spores more or less oval; pointed anteriorly, broad posteriorly; valves symmetrical, thick; sutural ridge distinct; inter capsular appendix present; polar capsules unequal, pyriform; sporoplasm spherical or hemispherical, binucleate; iodophilous vacuole present.

Size : Spore length 13.0–19.5 (15.71) μm , width 4.9– 8.1 (6.8) μm ; polar capsule (large) length 7.3–11.8 (8.8) μm , width 2.4–3.2 (1.78) μm ; polar capsule (small) length 6.5–11.4 (7.58) μm , width 1.6–3.4 (2.57) μm .

Host : *Cirrhinus mrigala* (Hamilton); **site of Infection** : gills; **pathogenicity** : not apparent.

Distribution : India : Orissa (River Mahanadi).

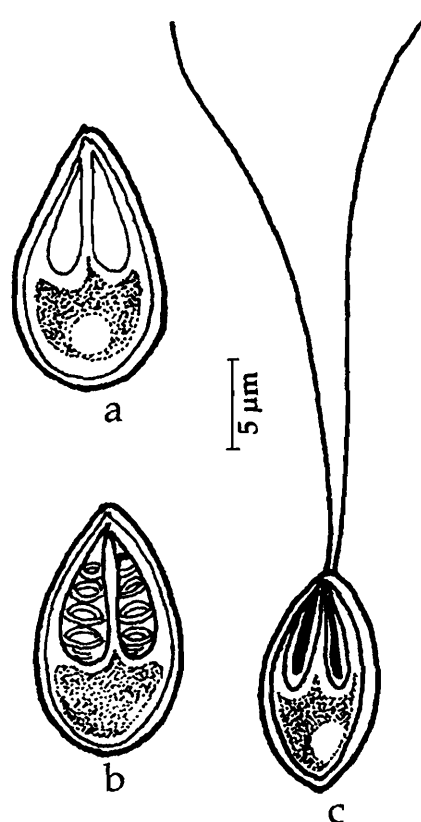


Fig. 172. *Myxobolus orissae* : a. Fresh spore valvular view, b. Spore stained with Giemsa, c. Spore with extruded polar filament

173. *Myxobolus osmaniae* Lalitha Kumari, 1969
(Fig. 173 a-c)

Diagnosis : Trophozoites 1–1.5 mm in diameter; spores pyriform; anterior end narrow, bent to one side, posterior end broad, rounded; shell valves uniformly thick with 8–10 parietal folds on posterior margin; sutural line median, faint; polar capsules 2, unequal, pyriform with prominent neck; intercapsular ridge absent; polar filaments unequal, forming 5–6 tight coils while inside the capsule; sporoplasm granular, homogenous occupying the entire extra capsular spore cavity; iodophilous vacuole large and centrally placed.

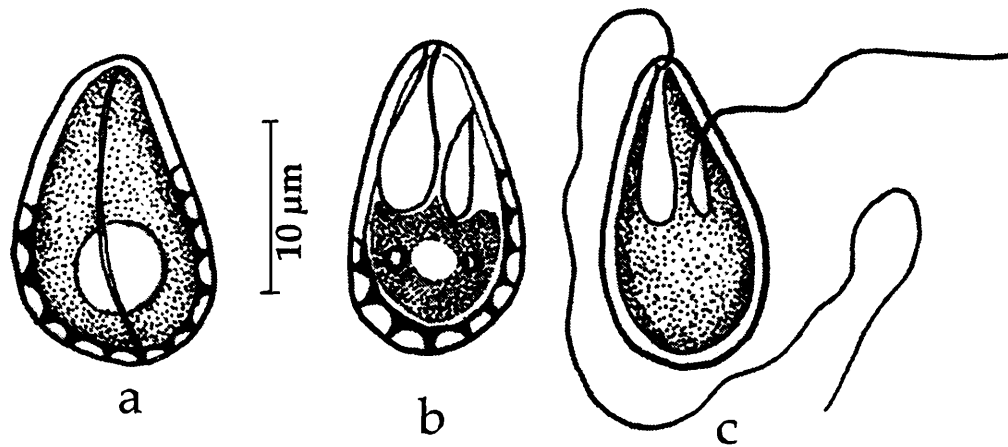


Fig. 173. *Myxobolus osmaniae* : a. Fresh spore valvular view, b. Spore sutural view, c. Spore with extruded polar filament

Size : Spore length 12.4–15.0 (13.5) μm , width 7.1–10.0 (8.6) μm ; polar capsule (large) length 5.0–7.1 (5.6) μm , width 2.0–3.9 (3.2) μm ; polar capsule (small) length 2.1–3.6 (2.6) μm , width 1.4–2.9 (2.5) μm ; polar filament (long) length, 109–134 (126.0) μm , polar filament (small) 18–39 (25.6) μm .

Host : *Barbus punjabensis*; *site of infection* : liver and intestine; *pathogenicity* : not apparent.

Distribution : India : Andhra Pradesh (Local market in Hyderabad city).

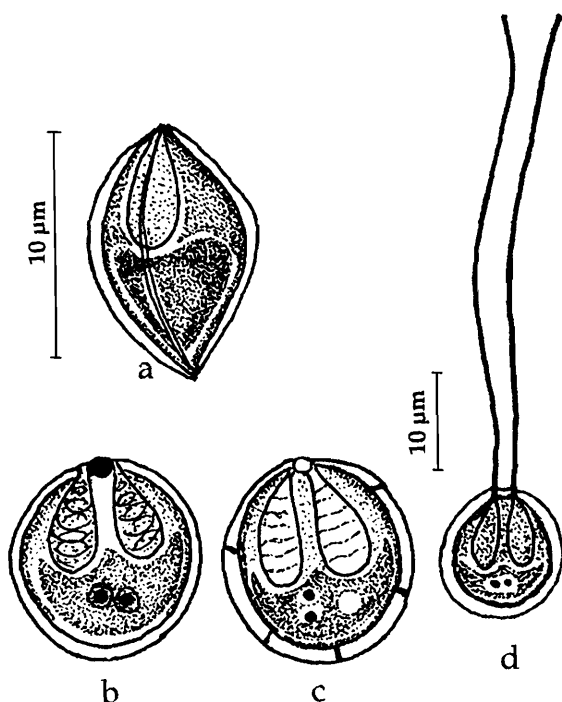


Fig. 174. *Myxobolus parsi* : a. Fresh spore valvular view, b & c. Spore stained with Giemsa, d. Spore with extruded polar filament

174. *Myxobolus parsi* Das, 1996
(Fig. 174 a-d)

Diagnosis : Spore ovoidal to round with a mucuous envelop; valves smooth; sutural line straight; polar capsules equal, pear-shaped; polar filament forming 5 coils while inside the capsule; sporoplasm granular, binucleate; iodophilous vacuole present.

Size : Spore length 9.0–9.5 (9.1) μm , width 8.0–8.5 (8.1) μm ; polar capsule length 4.0–5.0 (4.4) μm , width 2.5–3.0 (2.8) μm .

Host : *Liza parsia*; *site of infection* : gills; *pathogenicity* : not apparent.

Distribution : India : West Bengal (Kakdwip, South 24 Parganas district).

175. *Myxobolus parvus* Schulmann, 1962

(Fig. 175 a-d)

Diagnosis : Developing plasmodia long, thin, slightly oval, 40-50 μm x 640-820 μm with pointed extremities, enveloped by a thick layer of epithelial cells; spores round or slightly oval in front view, oval in lateral view; shell valves thin, symmetrical, smooth; polar capsules equal, slightly pyriform; polar filament making 6-7 coils while inside the capsule; mucous envelop, inter-capsular ridge absent; iodophilous vacuole present.

Size : Spore length 6.0-7.0 (6.3) μm , width 4.5-6.0 (4.8) μm , thickness 4.0 μm ; polar capsule length 3.0-4.0 (3.6) μm , width 1.5-2.0 (1.6) μm .

Host : *Mugil cephalus*; **site of infection** : Gill rakers; **pathogenicity** : not apparent.

Distribution : India : Goa (Indian Ocean coast). **Elsewhere** : Korea : Basin of Liohe River.

Remarks : Eiras and D'souza (2004) reported this species from Goa, India.

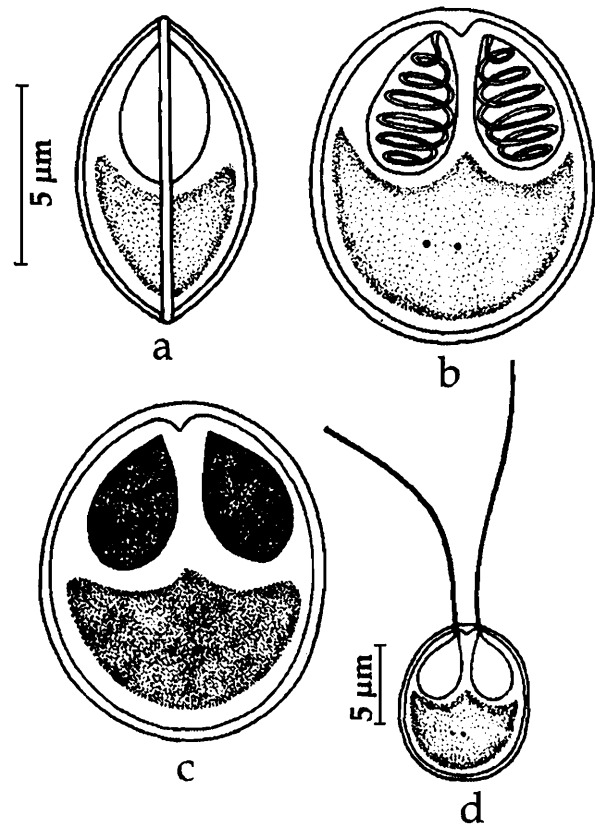


Fig. 175. *Myxobolus parvus* : a. Fresh spore sutural view, b. valvular view, c. spore stained with Giemsa, d. spore with extruded polar filament

176. *Myxobolus pinnaurati* Lalitha Kumari, 1969

(Fig. 176 a-c)

Diagnosis : Spores oblong or oval with rounded ends; shell valves symmetrical, uniform, equal; sutural ridge median, straight with 2 or more parallel ridges on either side; polar capsules 2, unequal, elongated, pyriform, subterminal; polar filaments unequal crossing each other when extended; no intercapsular ridge; sporoplasm finely granular, homogenous, occupying the entire spore cavity; iodophilous vacuole oval, large located in the posterior region.

Size : Spore length 8.0-11.4 (9.6) μm , width 6.5-7.9 (7.0) μm ; polar capsule (large) length 3.6-6.4 (4.4) μm , width 1.1-2.1 (1.9) μm ; polar capsule (small) length 2.9-5.0 (3.1) μm , width 1.1-2.1 (1.6) μm ; polar filament length, long 35.0-46.5 (41.6) μm , small 21.5-26.0 (23.2) μm .

Host : *Barbus pinnauratus*; **site of infection** : gill filaments; **pathogenicity** : not recorded.

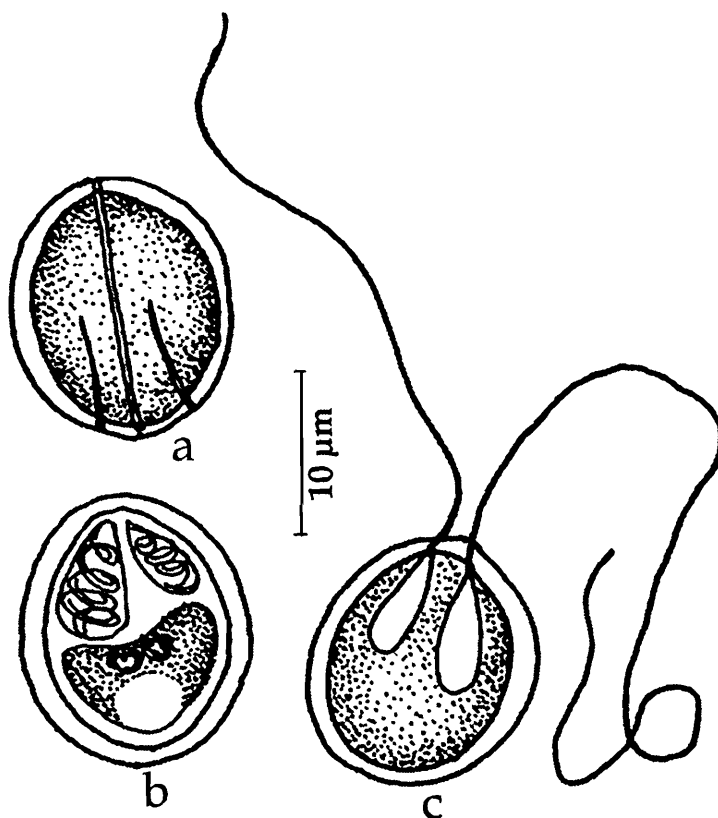


Fig. 176. *Myxobolus pinnaurati* : a. Fresh spore valvular view, b. Spore stained with Giemsa, c. Spore with extruded polar filament

Distribution : India : Andhra Pradesh (Lake near Hyderabad city).

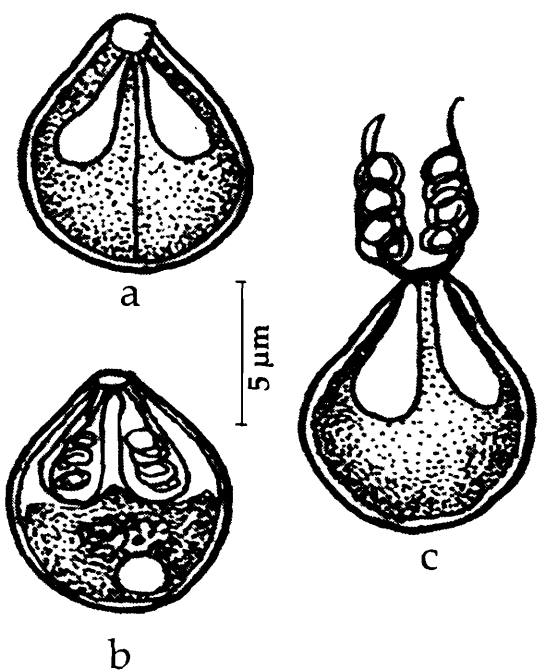


Fig. 177. *Myxobolus potali* : a. Fresh spore valvular view, b. Spore stained with Giemsa, c. Spore with extruded polar filament

177. *Myxobolus potali* Lalitha
Kumari, 1969
(Fig. 177 a-c)

Diagnosis : Spores oval in valvular view with prominent knobs at the anterior end, pyriform in sutural view; posterior end broad, rounded, shell valves equal, symmetrical, with markings on posterior margin; sutural ridge absent; polar capsules 2, equal, oval with prominent ducts; a small clear inter capsular ridge present; polar filaments long forming 3 fine loose coils while inside the capsule; sporoplasm granular, homogenous occupying the entire extra capsular spore cavity; iodophilous vacuole large and in the posterior region of the spore.

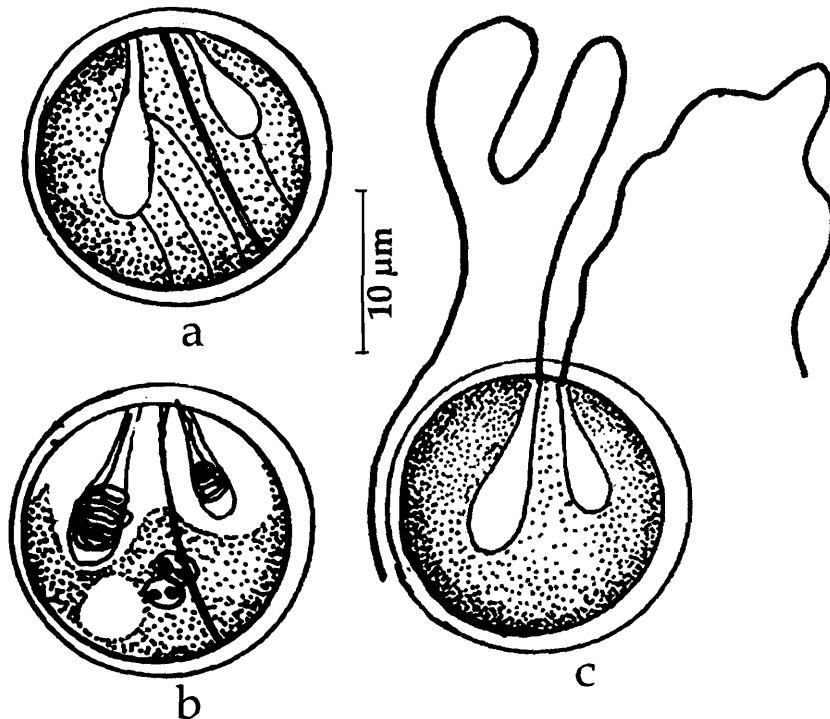
Size : Spore length 6.3–7.9 (7.2) μm , width 4.3–6.4 (5.4) μm ; polar capsule length 2.9–3.6 (3.3) μm , width 1.4–2.1 (2.0) μm ; polar filament length 9.0–15.5 μm .

Host : *Labio potail*; *site of infection* : liver and intestine; *pathogenicity* : not recorded.

Distribution : India : Andhra Pradesh (Local market in Hyderabad city).

178. *Myxobolus psilorhynchi* Lalitha Kumari, 1969
(Fig. 178 a-c)

Diagnosis : Trophozoites small, round, 0.5–1.0 mm in diameter; pansporoblasts disporous; spores spherical or slightly oval with rounded ends; shell valves asymmetrical, with two striations one on either side of the sutural line and 3–4 parietal folds at the posterior end; sutural line slightly shifted; polar capsules 2, unequal, elongated, pyriform, subterminal, with short neck; intercapsular ridge prominent; polar filaments unequal, forming 6–7 tight coils while inside the capsule, thin, long when extended; sporoplasm finely granular, homogenous occupying the entire spore cavity; iodophilous vacuole oval, large, either central or shifted to one side.



Size : Spore length 9.3–10.7 (10.0) μm , width 8.6–10.0 (9.4) μm ; polar capsule (large) length 4.3–5.7 (4.8) μm , width 2.9–3.9 (3.2) μm ; polar capsule (small) length 2.9–4.3 (3.5) μm , width 2.1–3.0 (2.5) μm ; polar filament length, long 98–141 (119.8) μm , short 31–68.5 (56.0) μm .

Host : *Psilorhynchus balitora*; *site of infection* : gill filaments; *pathogenicity* : not recorded.

Distribution : India : Andhra Pradesh (Lake near Hyderabad city).

Fig. 178. *Myxobolus psilorhynchi* : a. Fresh spore valvular view, b. Spore stained with Giemsa, c. Spore with extruded polar filament

179. *Myxobolus punjabensis* Gupta and Khera, 1989a
(Fig. 179A-D)

Diagnosis : Cyst opaque-white in colour, generally rounded, or elongate; spore bowl-shaped with truncated anterior end and round posterior end, lenticular in sutural view; shell valves symmetrical; sutural ridge prominent; polar capsules two, unequal, opening independently to outside; polar filaments thick; sporoplasm granular, homogeneous with one or two sporoplasmic nuclei, iodophilous vacuole absent.

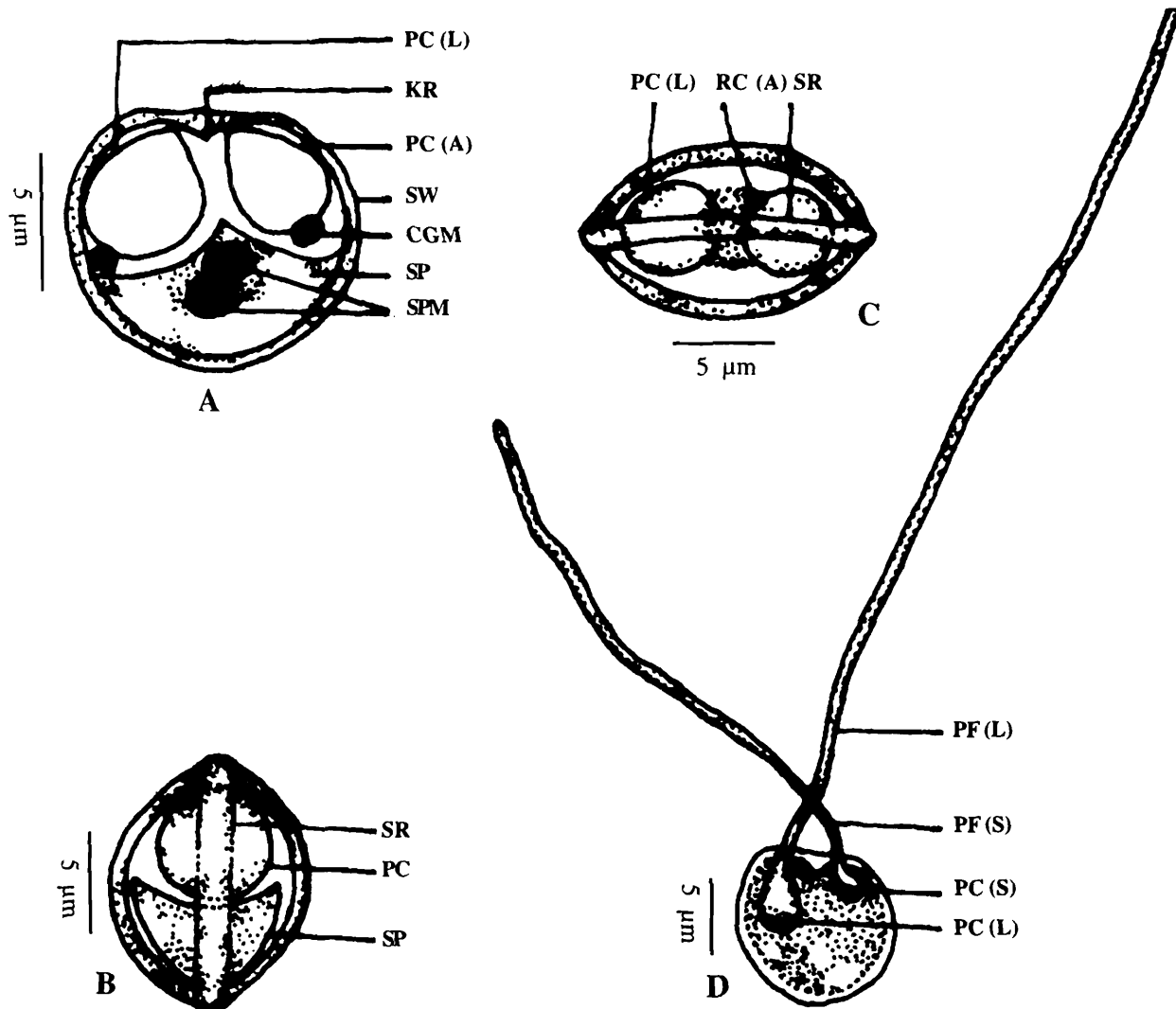


Fig. 179. *Myxobolus punjabensis* : a. Fresh spore valvular view, b. Fresh spore sutural view, c. Fresh spore anterior view, d. Spore with extruded polar filament

Size : Cyst 0.076-0.133 mm in diameter or 0.133-0.380 mm x 0.095-0.223 mm; spore 10-12 (10.86) μm x 10-11 (10.64) μm ; polar capsule (large) 5-6 (5.72) μm , (shorter) 39-50 μm .

Host : *Labeo dyocheilus* (McClelland); *site of infection* : fins and gills; *pathogenicity* : not recorded.

Distribution : India : Punjab (Ropar, Ludhiana and Harike).

180. *Myxobolus rewensis* Srivastava, 1978

(Fig. 180)

Diagnosis : Trophozoites small, round, about 2.0 mm in diameter; spores spherical with rounded ends; shell valves thick, smooth, symmetrical; sutural line prominent; polar capsules 2, equal, circular, convergent, opening by small ducts; intercapsular ridge present; sporoplasm granular; iodophilous vacuole round prominent.

Size : Spore length 9.66 μm , width 8.05 μm , thickness 6.44 μm ; polar capsule length 4.8 μm , width 3.2 μm .

Host : *Cirrhinus mrigala* (Hamilton); **site of infection :** scales; **pathogenicity :** not recorded.

Distribution : India : Madhya Pradesh (Rewa).

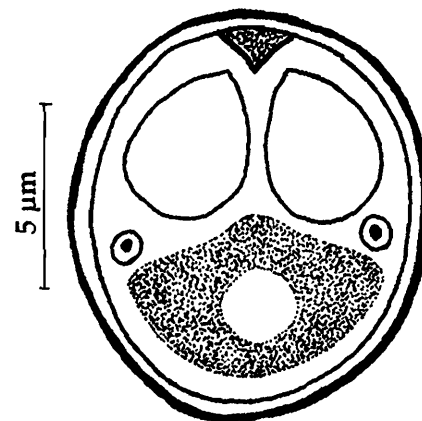


Fig. 180. *Myxobolus rewensis* : Fresh spore valvular view

181. *Myxobolus rigida*, Sarkar, 1999b

(Fig. 181 a-c)

Diagnosis : Spores oval to pyriform, pointed anteriorly, broad posteriorly in valvular view, lenticular in sutural view; shell valves symmetrical, smooth; sutural ridge moderately thick, polar capsules pear-shaped, equal; polar filament making 7-8 coils while inside the capsule; intercapsular ridge vertical, long, rod-like; sporoplasm binucleate; iodophilous vacuole present; no mucous envelop.

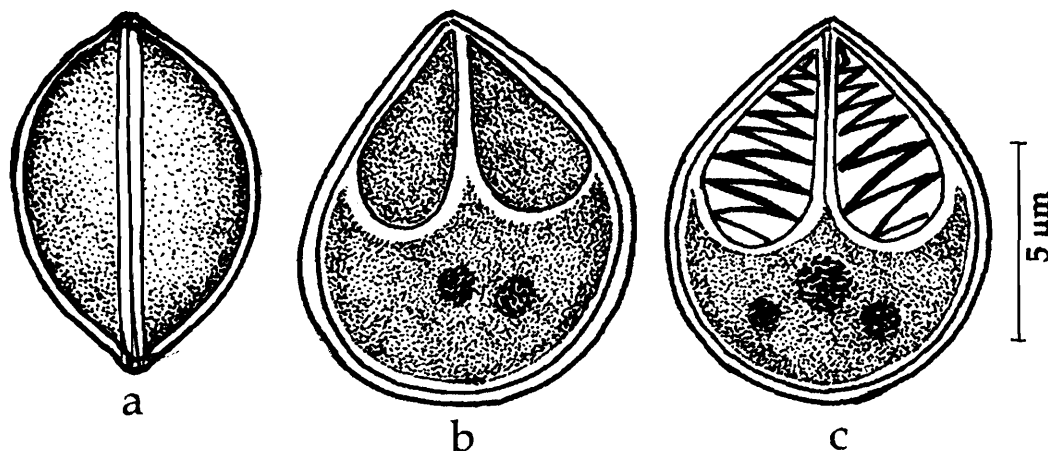


Fig. 181. *Myxobolus rigida* : a. Fresh spore sutural view, b. Spore valvular view, c. Spore stained with Giemsa

Size : Spore length 10.0–11.0 (10.8) μm , width 7.5–9.5 (8.6) μm ; polar capsule length 5.5–7.0 (6.3) μm , width 3.0–4.0 (3.6) μm .

Host : *Amblypharyngodon mola* (Ham); **site of infection;** kidney; **pathogenicity :** not apparent.

Distribution : India : West Bengal (24 Parganas district).

182. *Myxobolus rocatlae* Basu and Haldar, 2002b

(Fig. 182 a-e)

Diagnosis : Trophozoites oval (1100 μm x 560 μm) or horse-shoe shaped (440 μm x 218 μm), yellowish in colour; 2 distinct populations of spores arising from the same plasmodium. spores histozoic, elongated or pyriform in valvular view, lenticular in sutural view; anterior end bluntly pointed, posterior end round; valves symmetrical, thin; sutural ridge distinct; polar capsules either equal or unequal, pyriform; when equal occupying 2/3 the length of the spore; large capsule with 17-19 coils of the polar filament inside the capsule, long and thin when extended; smaller polar capsule with 15-18 tight coils of polar filament inside the capsule; sporoplasm granular, homogenous filling the cup-shaped extracapsular spore cavity below the capsules; iodophilous vacuole absent.

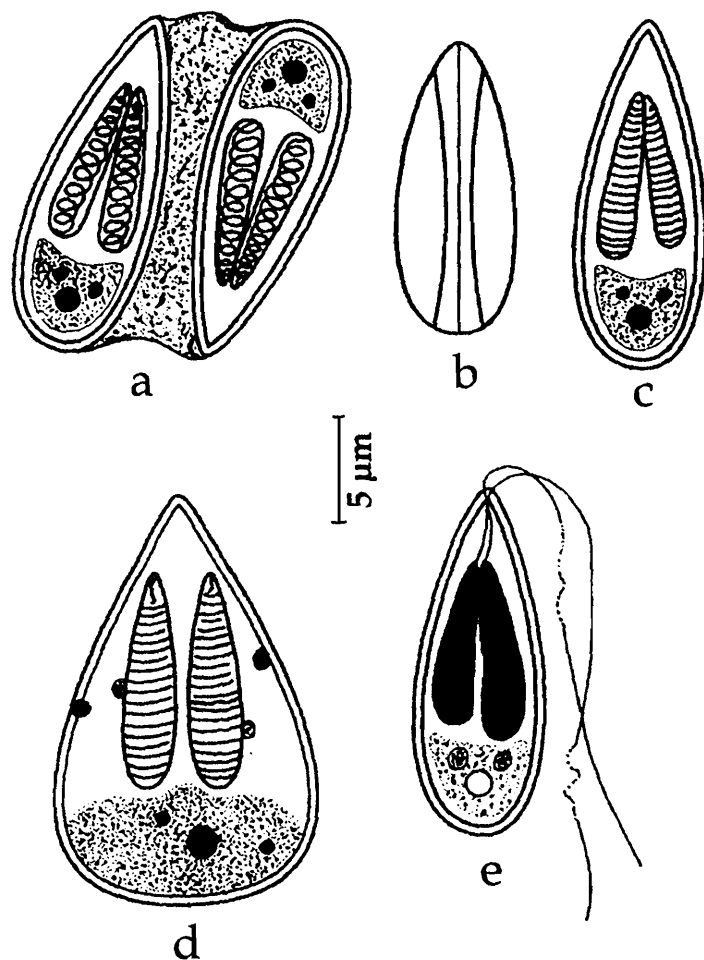


Fig. 182. *Myxobolus rocatlae* : a. Disporic pansproblast, b. Fresh spore sutural view, c. Spore valvular view, d. Spore stained with Giemsa, e. Spore with extruded polar filament

filament inside the capsule, long and thin when extended; smaller polar capsule with 15-18 tight coils of polar filament inside the capsule; sporoplasm granular, homogenous filling the cup-shaped extracapsular spore cavity below the capsules; iodophilous vacuole absent.

Size : Spore with equal polar capsules : length 16.9–19.3 (18.3) μm , width 5.6–6.9 (6.0) μm ; polar capsule length 10.4–13.7 (12.6) μm , width 2.2–3.1 (2.8) μm ; polar filament 74.9–96.4 (88.1) μm . Spore with unequal polar capsules : length 17.5–19.3 (18.5) μm , width 5.6–6.2 (5.9) μm ; polar capsule (large) length 11.8–13.7 (12.9) μm , width 2.5–3.0 (2.85) μm ; polar capsule (small) length 10.1–12.2 (11.3) μm , width 2.0–2.4 (2.2) μm ; polar filament length 69.5–83.7 (79.0) μm .

Host : Catla–Rohu hybrid; **site of infection :** gills and gut; **pathogenicity :** not recorded.

Distribution : India : West Bengal (Ranaghat, Nadia district).

183. *Myxobolus rohita* Haldar, Das and Sharma, 1983
(Fig. 183 a-d)

Diagnosis : Cysts white round, 200-300 μm ; spore ovoidal to rounded; shell valves symmetrical, equal, thick with a triangular notch at the anterior end; polar capsules pear-shaped, equal, open independently separated by notch; polar filaments showing 5-6 coils while inside the capsule; sporoplasm hemispherical, binucleate; iodophilous vacuole present.

Size : Spore length 9.9–12.1 (10.6) μm , width 8.8–9.9 (9.0) μm ; polar capsule length 6.6 μm , width 3.3 μm ; polar filament length 33–45.0 (40.1) μm .

Host : *Labeo rohita*, *L. bata*, *L. dacheilus*, *L. calbasu* and *Puntius sarana*; **site of infection :** scales; **pathogenicity :** not recorded.

Distribution : India : West Bengal (Krishnanagar), Punjab : (Harike, Nangal, Ropar, Ludhiana).

Remarks : Gupta and Khera 1990 reported this species from five species of cyprinids namely, *L. rohita*, *L. bata*, *L. dacheilus*, *L. calbasu* and *Puntius sarana* from different regions in Punjab.

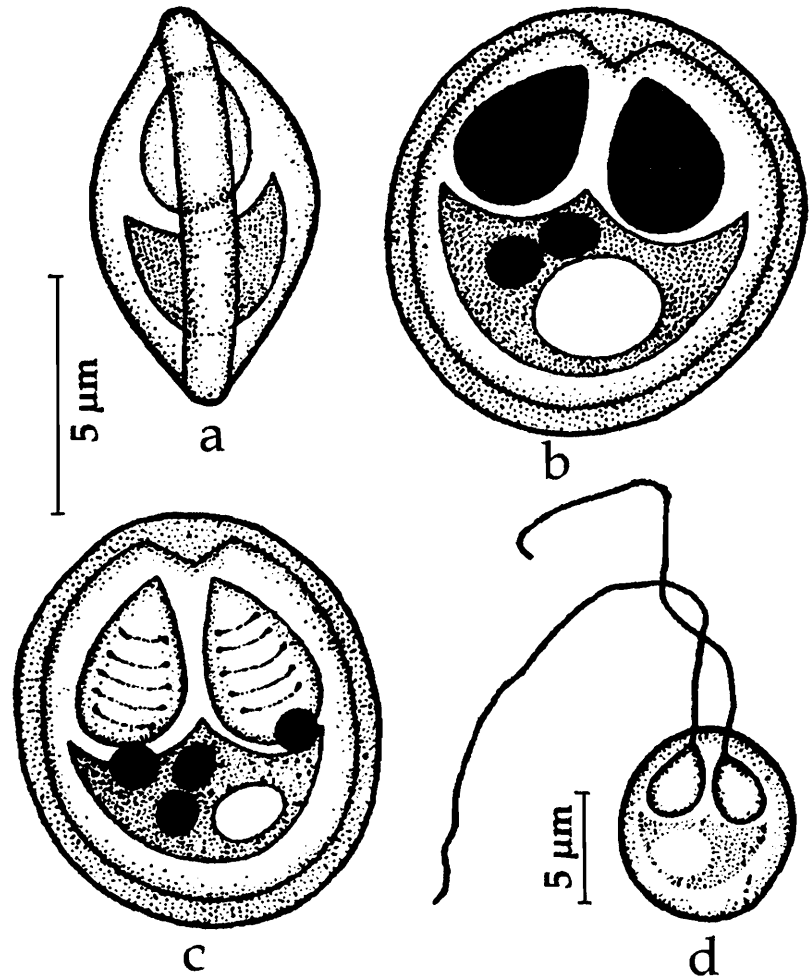


Fig. 183. *Myxobolus rohita* : a. Fresh spore sutural view, b. Spore valvular view, c. Spore stained with Giemsa, d. Spore with extruded polar filament

184. *Myxobolus saranae* Gupta and Khera, 1990
(Fig. 184 a-c)

Diagnosis : Cyst large, white, elongated, 1.75–2.85 mm x 0.986–1.064 mm in size; spores oval, posterior end broad in valvular view, lenticular in sutural view; valves symmetrical; sutural ridge straight, prominent; intercapsular ridge absent; polar capsules unequal, pyriform; polar filaments remarkably unequal; sporoplasm granular, homogenous, uni- or binucleate; iodophilous vacuole large.

Size : Spore length 6.0–9.0 (7.72) μm , width 6.0–7.0 (6.2) μm ; polar capsule (large) length 4.0–5.0 (4.24) μm , width 2.5–4.0 (3.04) μm ; polar capsule (small) length 1.5–3.0 (1.98) μm , width 1.0–2.0 (1.3) μm ; polar filament length, long 23–32 μm , short 5.0–9.0 μm .

Host : *Puntius sarana* (Ham.); *Labeo calbasu*;
site of infection : gills; **pathogenicity :** not recorded.

Distribution : India : Punjab (Ropar and Ludhiana).

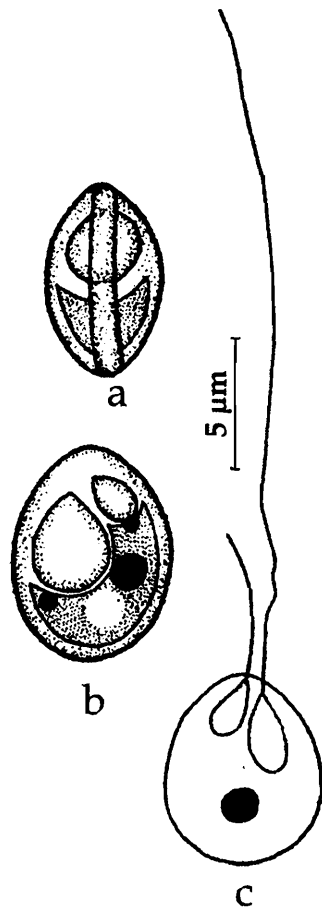


Fig. 184. *Myxobolus saranae* : a. Fresh spore sutural view, b. Spore valvular view, c. Spore with extruded polar filament

185. *Myxobolus saranai* (Tripathi, 1952) emend. Landsberg and Lom, 1991
(Syn. *Myxobolus branchialis* Tripathi, 1952)
(Fig. 185 a-b)

Diagnosis : Spore oval in valvular view, fusiform in sutural view; shell valves smooth, symmetrical and moderately thick; sutural ridge prominent; polar capsule unequal, convergent, oval-shaped; polar filaments unequal; spherical iodophilous vacuole present.

Size : Spore length 6.4–7.0 μm ; width 4.5–5.0 μm ; polar capsule (large) length 3.5 μm , width 1.5 μm ; polar capsule (small) length 1.5 μm , width 1.0 μm ; polar filament length, long 24.8–27.2 μm and short 12.0–14.5 μm .

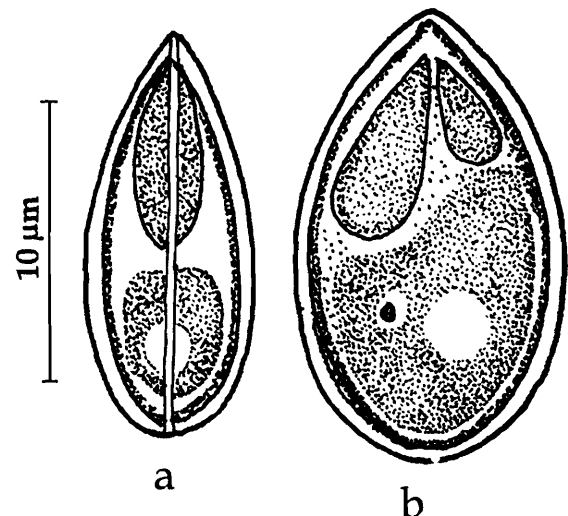


Fig. 185. *Myxobolus saranai* : a. Fresh spore sutural view, b. Spore valvular view

Host : *Barbus sarana* (Ham); *site of infection* : gills; *pathogenicity* : not recorded.

Distribution : India : West Bengal (North 24-Parganas district).

Remarks : Landsberg and Lom (1991) while reviewing the genus *Myxobolus* found that *Myxobolus branchialis* is a preoccupied name. Tripathi's species of *M. branchialis* is different from *M. branchialis* Markevich, 1932. Therefore, Landsberg and Lom (1991) renamed the species described by Tripathi (1952) as *Myxobolus saranai*.

186. *Myxobolus saraswati* Gupta and
Saraswat, 1993
(Fig. 186 a-b)

Diagnosis : Cyst not observed; spores spherical to oval; valves symmetrical, smooth; polar capsules equal, elongated, pear-shaped; polar filaments remarkably long; sporoplasm triangular, homogenous, not extending into the intercapsular space; iodophilous vacuole absent.

Size : Spore length 10.0–20.0 μm , width 7.8–11.0 μm ; polar capsule length 3.5–9.5 μm , width 2.0–3.5 μm ; polar filament length, 109.0–122.0 μm .

Host : *Clarias batrachus* (Linn.); *site of infection* : kidney; *pathogenicity* : not recorded.

Distribution : India : Uttar Pradesh (Rohilkhand).

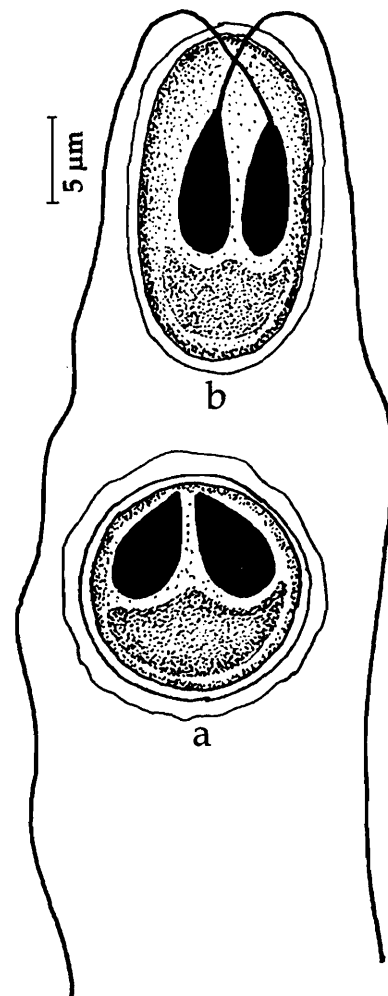


Fig. 186. *Myxobolus saraswati* : a. Fresh spore sutural view, b. Spore with extruded polar filament

187. *Myxobolus scatophagi* Haldar, Samal and Mukhopadhyay, 1996
(Fig. 187 a-d)

Diagnosis : Spores pyriform, pointed anteriorly, broad posteriorly; valves thick, with a thickened notch at the anterior end; polar capsules unequal, pyriform; sporoplasm granular, crescentic; iodophilous vacuole present; intercapsular ridge absent.

Size : Spore length 11.4–17.9 (14.0) μm , width 4.0–8.1 (5.3) μm ; polar capsule (large) length 5.6–9.8 (7.13) μm , width 1.6–3.2 (2.36) μm ; polar capsule (small) length 4.9–8.1 (6.0) μm , width 1.6–2.4 (2.0) μm .

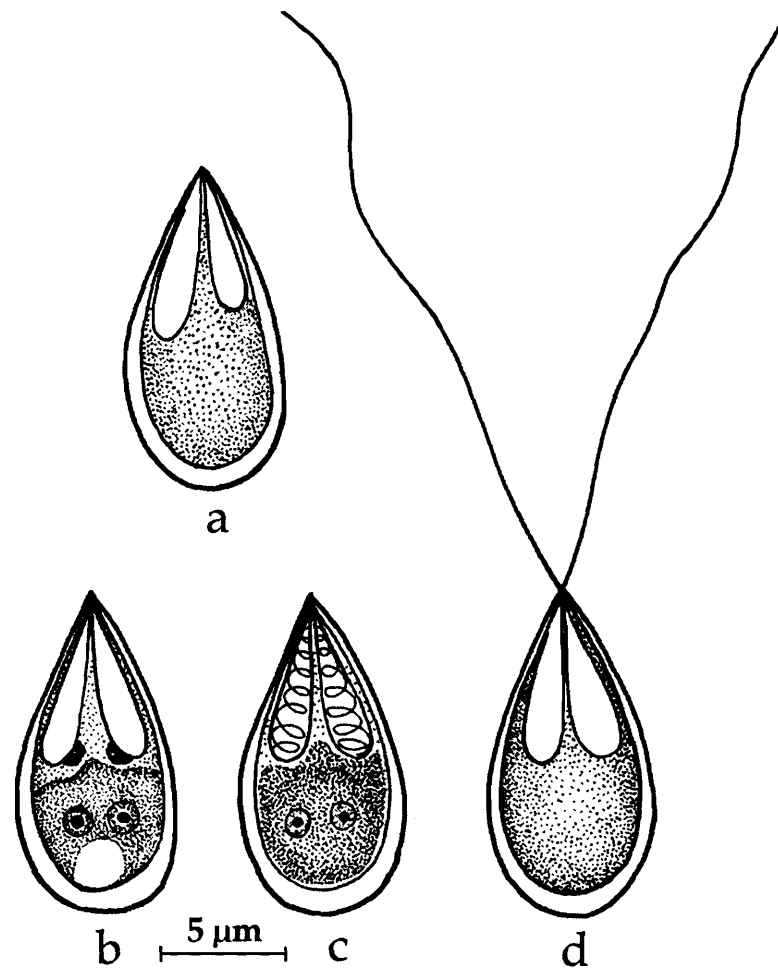


Fig. 187. *Myxobolus scatophagi* : a. Fresh spore sutural view, b. Spore valvular view, c. Spore stained with Giemsa, d. Spore with extruded polar filament

Host : *Scatophagous argus*; *site of infection* : gills; *pathogenicity* : not recorded.

Distribution : India : Orissa (Chilka Lake and Mahanadi).

188. *Myxobolus serrata* Pagarkar and Das, 1993
(Fig. 188 a-b)

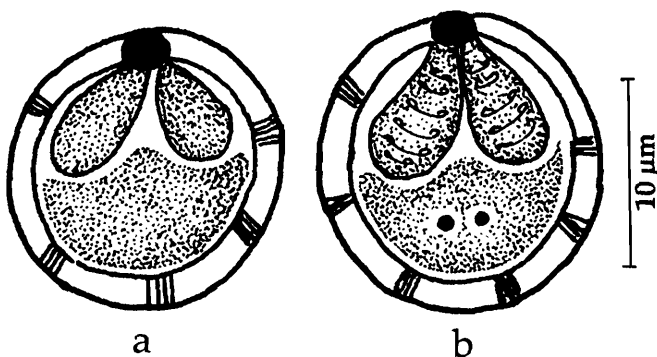


Fig. 188. *Myxobolus serrata* : a. Fresh spore valvular view, b. Spore stained with Giemsa

Diagnosis : Spores oval to spherical in front view, pointed anteriorly, broad posteriorly; valves thick, with a thickened notch at the anterior end; thickenings along the walls of the valves present; polar capsules equal, pyriform, attenuated at the notch; polar filament forming 5-6 coils while inside the capsule; sporoplasm binucleate, granular, hemispherical; iodophilous vacuole present.

Size : Spore length 8.5–10.0 (9.07) μm , width 8.0–9.0 (8.5) μm ; polar capsule length 4.0– 5.0 (4.47) μm , width 2.5–3.00 (2.6) μm .

Host : *Cyprinus carpio*; **site of infection** : gill arch; **pathogenicity** : not apparent.

Distribution : India : West Bengal (Kalyani, Nadia district).

189. *Myxobolus shantipuri* Basu and Haldar, 2002b

(Fig. 189 a-d)

Diagnosis : Trophozoites oval (100 μm x 90 μm) or spherical (140 μm), white colour; spores histozoic, ovoidal or tear-shaped in valvular view, lenticular in sutural view; anterior end bluntly pointed, posterior end round; valves symmetrical, smooth; polar capsules either equal or unequal, ovoidal to pyriform with long neck; when equal the polar filament making 4-5 coils inside the capsule, long and thin when extended; sporoplasm granular, homogenous filling the cup-shaped extracapsular spore cavity below the capsules; iodophilous vacuole absent.

Size : Spore with equal polar capsules : length 6.3–8.2 (7.3) μm , width 5.2–6.1 (5.8) μm ; polar capsule length 3.5–4.1 (4.0) μm , width 2.0–2.8 (2.4) μm .

Spore with unequal polar capsules : length 6.2–8.1 (7.4) μm , width 5.1–6.2 (5.8) μm ; polar capsule (large) length 3.2–4.2 (3.9) μm , width 2.0–3.0 (2.2) μm ; polar capsule (small) length 2.5–4.0 (3.4) μm , width 1.9–2.8 (2.2) μm .

Host : *Catla-Rohu* hybrid; **site of infection** : gill lamellae; **pathogenicity** : not recorded.

Distribution : India : West Bengal (Ranaghat, Nadia district).

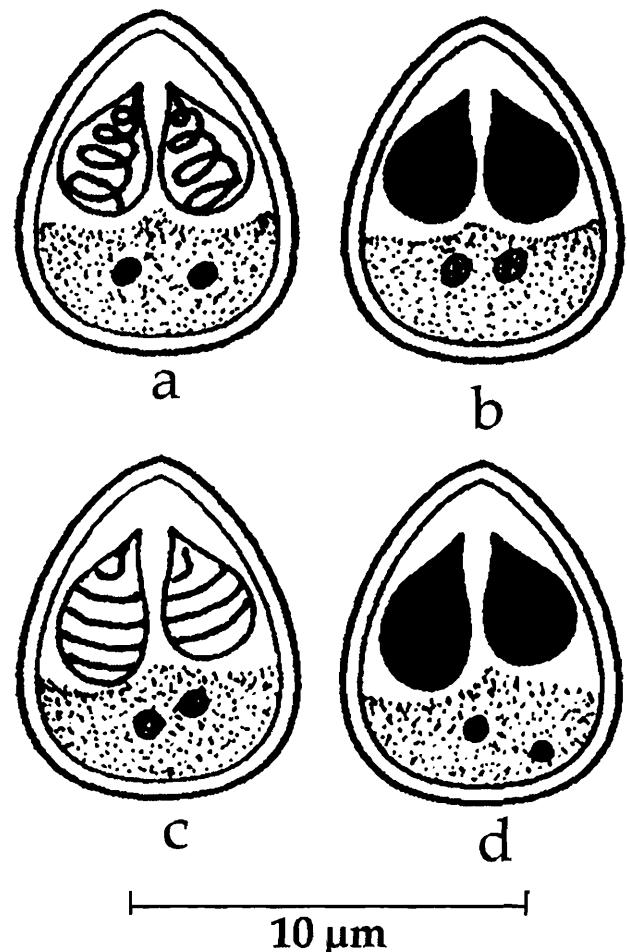


Fig. 189. *Myxobolus shantipuri* : a & b. Spores with equal polar capsules, c & d. Spores with unequal polar capsules

190. *Myxobolus shetti* Seenappa and Manohar, 1981

(Fig. 190 a-d)

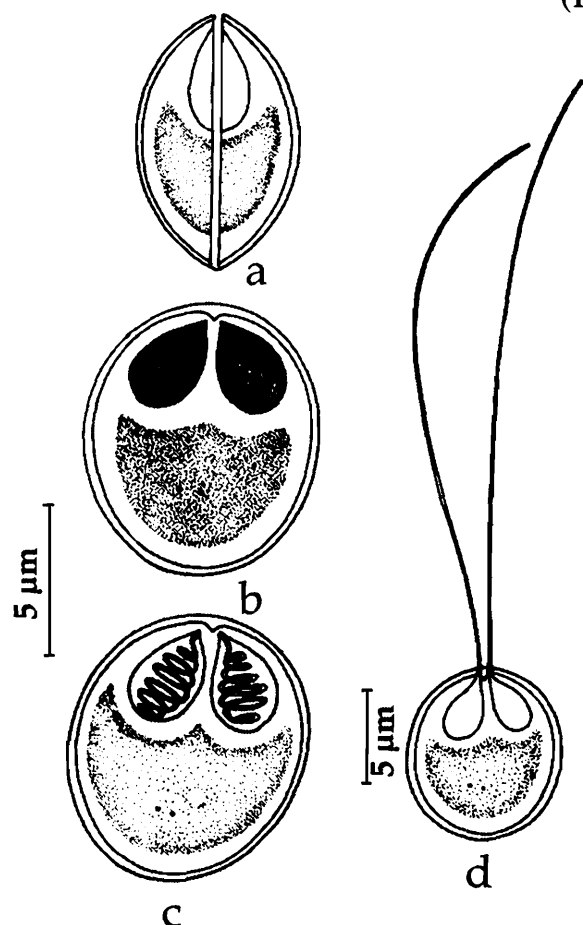


Fig. 190. *Myxobolus shetti* : a. Fresh spore sutural view, b. Spore valvular view, c. Spore stained with Giemsa, d. Spore with extruded polar filament

Diagnosis : Spore histozoic, ovoidal in valvular view, lenticular in sutural view; valves smooth, symmetrical; sutural ridge very clear; polar capsules ovoidal, equal, convergent; sporoplasm granular, binucleate, filling the extracapsular cavity; iodophilous vacuole present.

Size : Spore length 8.0-9.0 (8.8) μm , width 7.0-8.0 (7.4) μm ; polar capsule length 3.0-4.0 (3.4) μm , width 2.0-3.0 (2.3) μm .

Host : *Cirrhina mrigala* (ham.); **site of infection** : gills; **pathogenicity** : not recorded.

Distribution : India : Karnataka (Vanivilas sagar farm ponds), Kerala (Vellayani Lake).

Remarks : Krishnakumar (2000) reported this species from Kerala.

191. *Myxobolus seshadri* Laitha Kumari, 1969

(Fig. 191 a-c)

Diagnosis : Spores oval with narrow blunt anterior end and rounded posterior end; valves thin in the anterior half, thick posteriorly; polar capsules large, ovoid, slightly unequal with small ducts; inter capsular ridge prominent; polar filaments unequal, whip-like, crossing each other at the base when extended; a small constriction at the junction of the capsule; sporoplasm homogenous, granular, occupying the entire extracapsular space.

Size : Spore length 11.4-12.9 (12.21) μm , width 8.6-10.0 (9.04) μm ; polar capsule (large) length 5.7 μm , width 2.9-4.3 (3.66) μm ; polar capsule (small) length 4.3-5.0 (4.9) μm , width 2.5-3.6 (2.99) μm .

Host : *Labeo fimbriatus*; **site of infection** : gills; **pathogenicity** : not recorded.

Distribution : India : Andhra Pradesh (Tungabadhra river, Kurnool, Kurnool district).

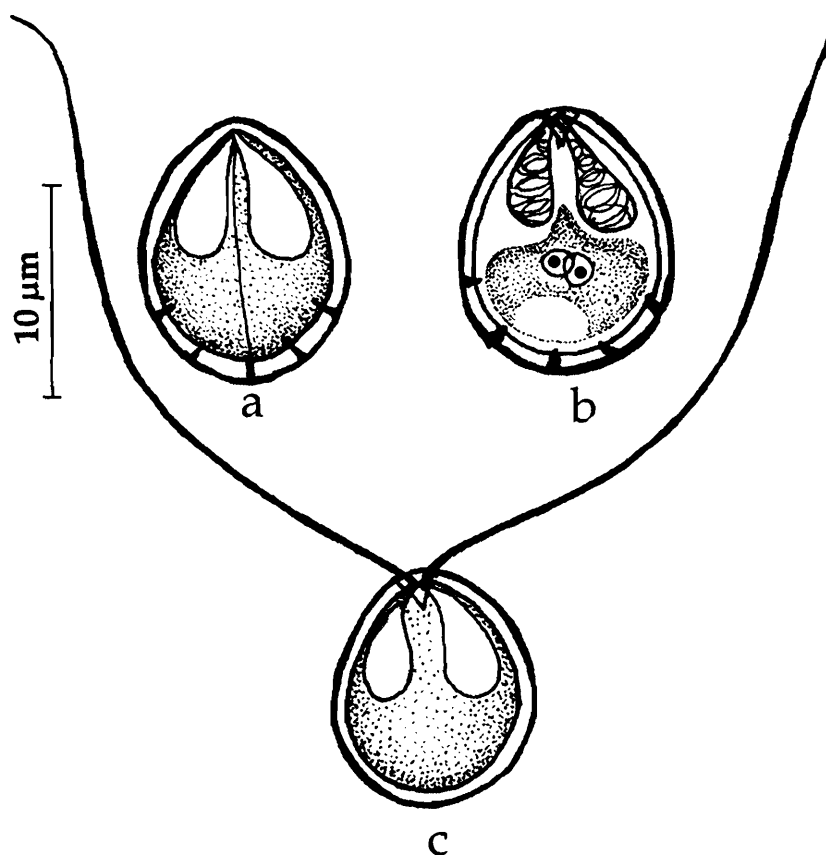


Fig. 191. *Myxobolus seshadri* : a. Fresh spore sutural view, b. Spore stained with Giemsa, c. Spore with extruded polar filament

192. *Myxobolus sophorae* Jayasri, 1982

(Fig. 192 a-b)

Diagnosis : Spores elongately oval or elongate in valvular view; shell valves thick, smooth, symmetrical; polar capsules oval, unequal, convergent; sporoplasm finely granular, uninucleate; iodophilous vacuole prominent.

Size : Spore length 6.4-26.6 (14.9) µm, width 5.9- 10.1 (7.7) µm.

Host : *Puntius sophore*; **site of infection** : gills and kidney; **pathogenicity** : lamellar destruction evident.

Distribution : India : Rajasthan (Parvatsar lake).

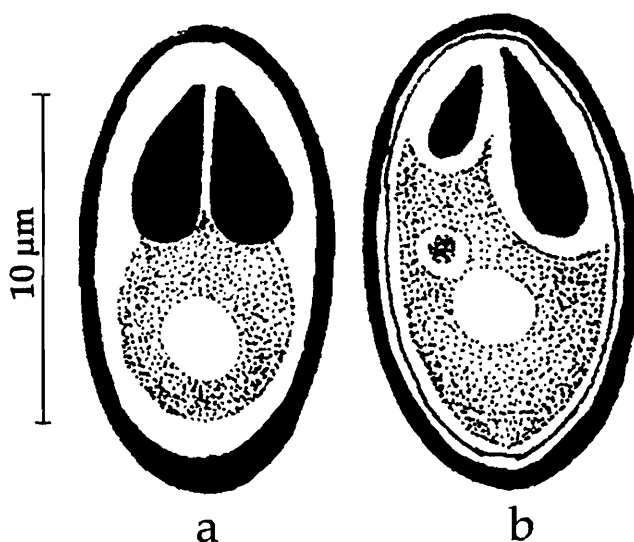


Fig. 192. *Myxobolus sophorae* : a. Spore with equal polar capsules, b. Spore with unequal polar capsules

193. *Myxobolus sphaeralis* Padma Dorothy and Kalavati, 1992b
(Fig. 193 a-c)

Diagnosis : Trophozoites oval, opaque white, 96-215 μm x 80-165 μm ; spores spherical, sutural line straight, distinct; polar capsules 2, equal, pyriform, convergent; polar filaments forming 4-5 coils while inside the capsule, long and thin when extended; sporoplasm hyaline, cup-shaped with 2 small depressions below the capsules; iodophilous vacuole absent.

Size : Spore 6.0-7.3 (6.74) μm in diameter; polar capsule length 3.4-3.9 (3.75) μm , width 2.2-3.4 (2.6) μm ; polar filament length 19.2-27.2 (21.76) μm .

Host : *Liza macrolepis*; **site of infection :** gill filaments; **pathogenicity :** infected gills rusty brown in colour, covered with excess mucous. Hypertrophy of the lamellar epithelium and cellular disintegration are evident.

Distribution : India : Andhra Pradesh (Visakhapatnam).

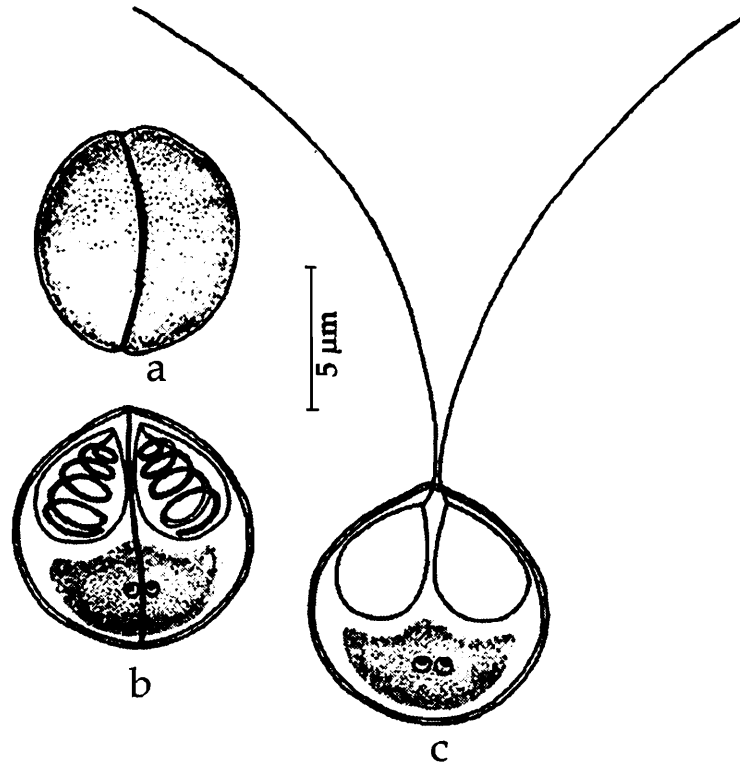


Fig. 193. *Myxobolus sphaeralis* : a. Fresh spore valvular view, b. Spore stained with Giemsa, c. Spore with extruded polar filament

194. *Myxobolus spinocurvatura*, Maeno, Sorimachi, Ogawa and Egusa, 1990
(Fig. 194 a-c)

Diagnosis : Pansporoblast disporous; spores oval with rounded ends in valvular view, lenticular with two 'knob-like' extensions on either side in sutural view; shell valves striated; sutural line distinct, narrow, straight or slightly wavy extending beyond the spore body, like two small knobs at both ends; polar capsules 2, equal, pyriform, subterminal, convergent; polar filament forming 4-6 longitudinal coils while inside the capsule; sporoplasm cup-shaped occupying the entire extra capsular area; no iodophilous vacuole.

Size : Spore length 10.6-13.6 (11.5) μm , width 9.6-11.2 (10.5) μm ; polar capsule length 2.58-4.8 (3.8) μm , width 1.72-3.2 (2.6) μm ; polar filament length 25.8-30.0 (28.0) μm .

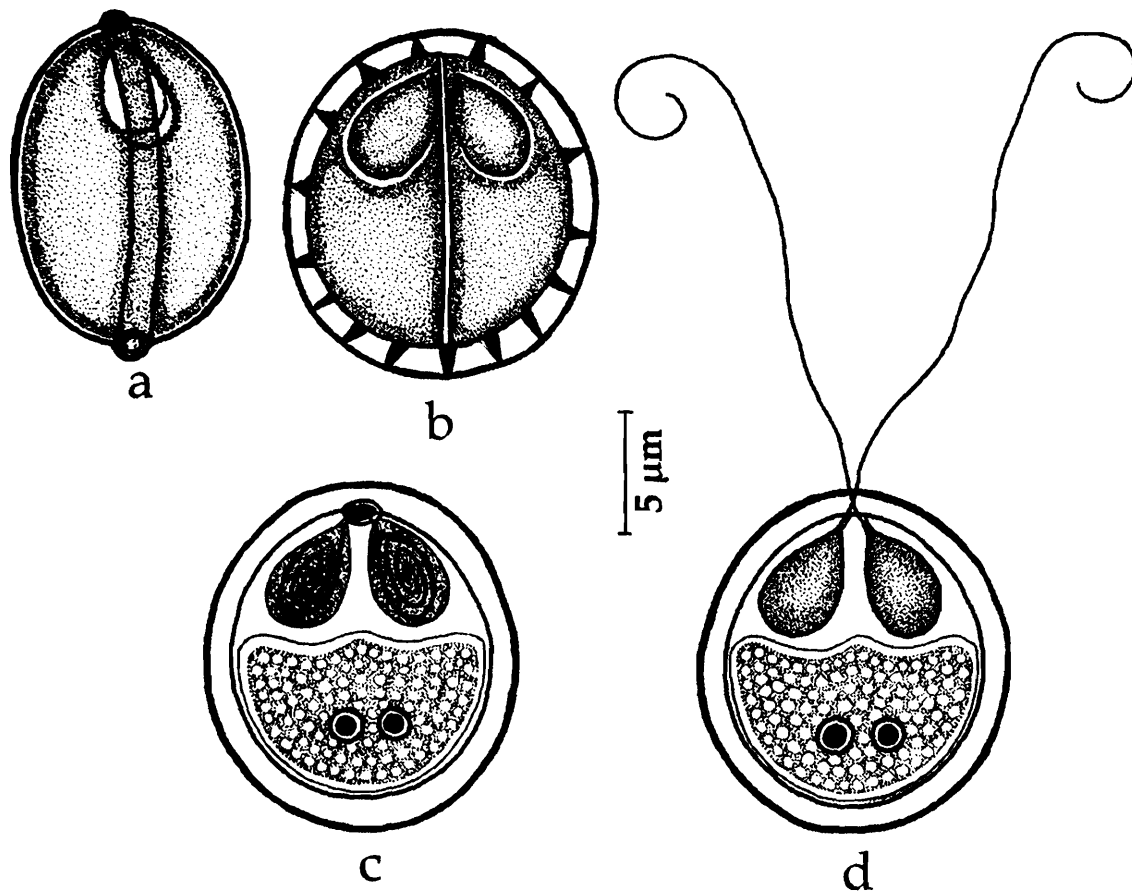


Fig. 194. *Myxobolus spinocurvatura* : a. Fresh spore sutural view, b. Spore valvular view, c. Spore stained with Giemsa, d. Spore with extruded polar filament

Host : *Mugil cephalus*; *site of infection* : branchial cartilage; *pathogenicity* : destruction and lysis of cartilage.

Distribution : India : Andhra Pradesh (Gosthani Estuary, Bheemunipatnam, Visakhapatnam, Visakhapatnam district). *Elsewhere* : Japan (Bay of Mie prefecture).

Remarks : Anuradha (1990) reported this species from *Mugil cephalus* inhabiting the harbour waters of Visakhapatnam.

195. *Myxobolus trichogasteri* (Sarkar, 1985) emend. Gupta and Khera, 1988
(Syn. *Myxosoma trichogasteri* Sarkar, 1985c)
(Fig. 195 a-d)

Diagnosis : Spores coelozoic, broadly pyriform in valvular view, lenticular in sutural view; anterior end broadly pointed, posterior end rounded; valves symmetrical thin walled, smooth; sutural line thick, slightly bent; polar capsules pyriform, equal, arranged parallel to each other; polar filament forming 5-6 coils while inside the capsule; sporoplasm finely granular binucleate; iodophilous vacuole absent.

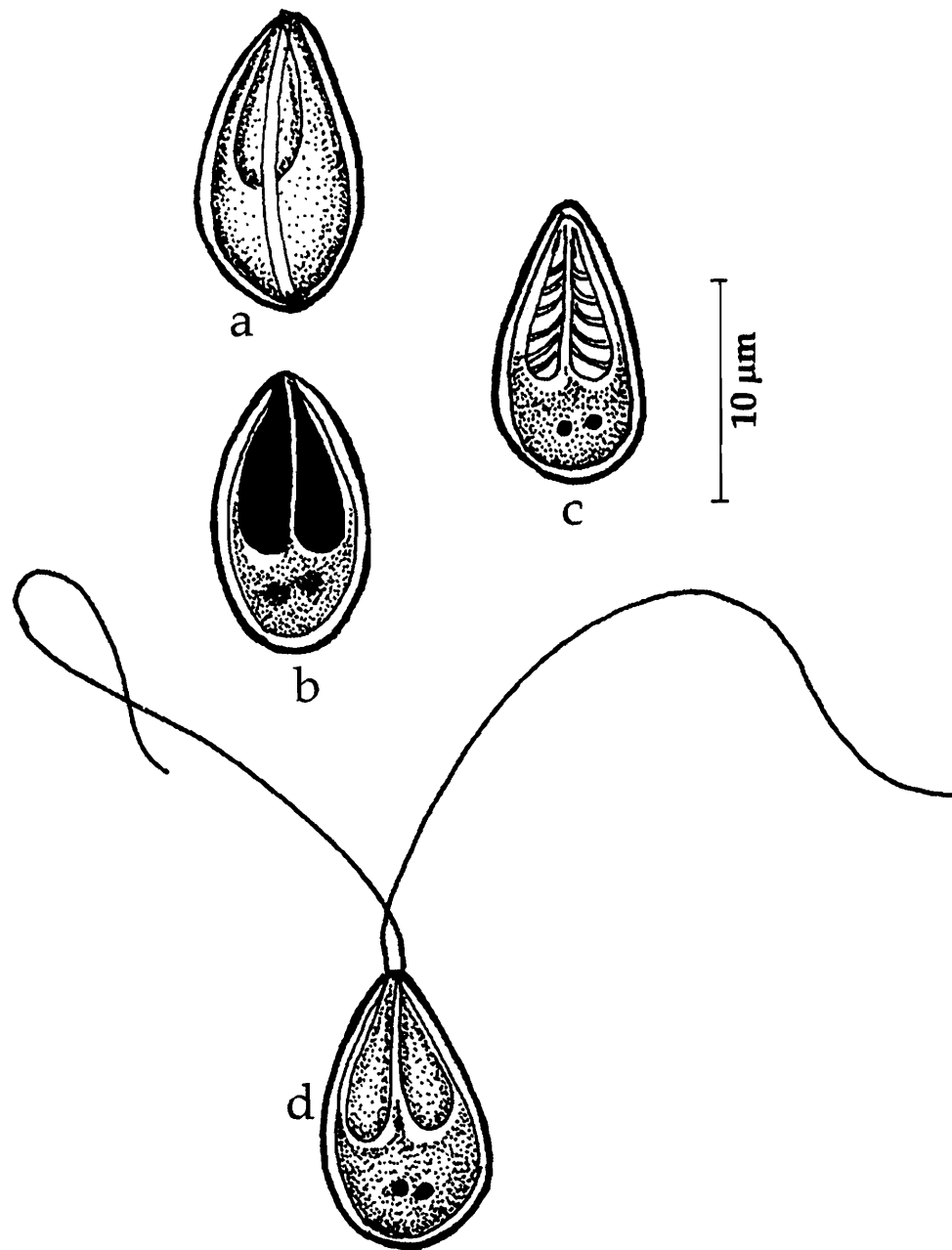


Fig. 195. *Myxobolus trichogasteri* : a. Fresh spore sutural view, b. Spore valvular view, c. Spore stained with Giemsa, d. spore with extruded polar filament

Size : Spore length 14.0-17.0 (15.55) μm , width 8.7-9.85 (9.35) μm ; polar capsule length 9.0-10.47 (10.1) μm , width 3.0- 3.84 (3.32) μm .

Host : *Trichogaster fasciatus*; *site of Infection* : gall bladder, bile; *pathogenicity*; not apparent.

Distribution : India : West Bengal (Barrackpore).

196. *Myxobolus tripathii* Kalavati, Sandeep and Narasimhamurti, 1981
(Fig. 196 a-c)

Diagnosis : Trophozoites opaque, white, 0.5-1.0 mm in diameter; spores spherical or oval; valves smooth, equal, symmetrical; sutural ridge prominent extending beyond the valve periphery like a knob; polar capsules 2, oval, equal, opening independently, with a distinct deeply stained, cushion-like mass at the opening of the polar capsules; polar filaments forming 8 coils while inside the capsule; sporoplasm homogenous, extending like a rim around the large oval iodophilous vacuole.

Size : Spore length 9.8-10.2 (10.1) μm , width 12.0-13.5 (13.0) μm ; polar capsule length 5.0-6.0 (5.5) μm , width 2.5 μm ; polar filament length 45-50 (47.6) μm .

Host : *Clarias* sp.; **site of infection** : wall of the gut and visceral organs; **pathogenicity** : not apparent.

Distribution : India : Andhra Pradesh (Visakhapatnam, Visakhapatnam district, Akiveedu, West Godavari district).

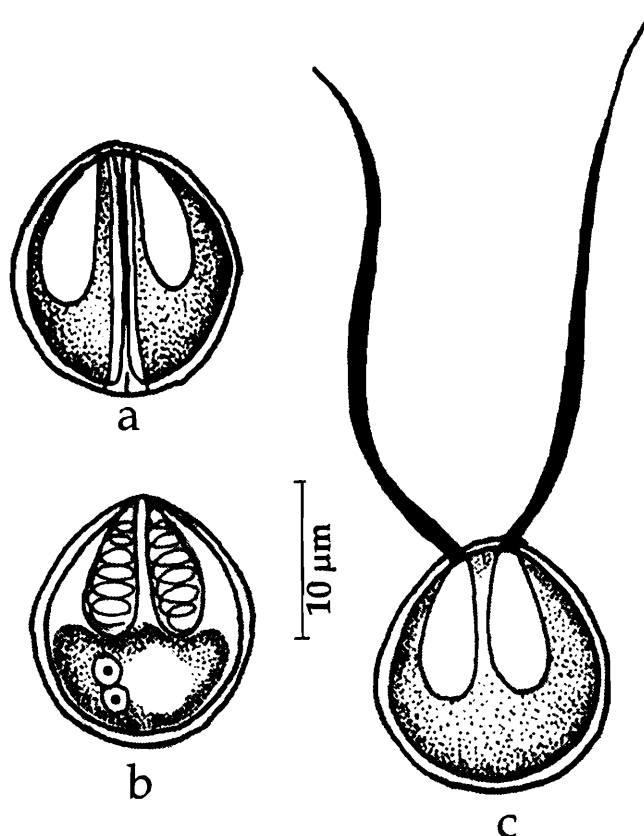


Fig. 196. *Myxobolus tripathii* : a. Fresh spore valvular view, b. Spore stained with Giemsa, c. Spore with extruded polar filament

197. *Myxobolus undasuturæ* Sarkar, 1994
(Fig. 197 a-c)

Diagnosis : Spores small, elongated, pyriform with sharply pointed anterior and rounded posterior end in valvular view and lenticular in sutural view; valves symmetrical, smooth; sutural line ridged, undulated, parallel to the long axis of the spore; polar capsules elongate, pyriform with a long neck, unequal, arranged parallel to each other, convergent; polar filament forming 7-8 coils in the larger

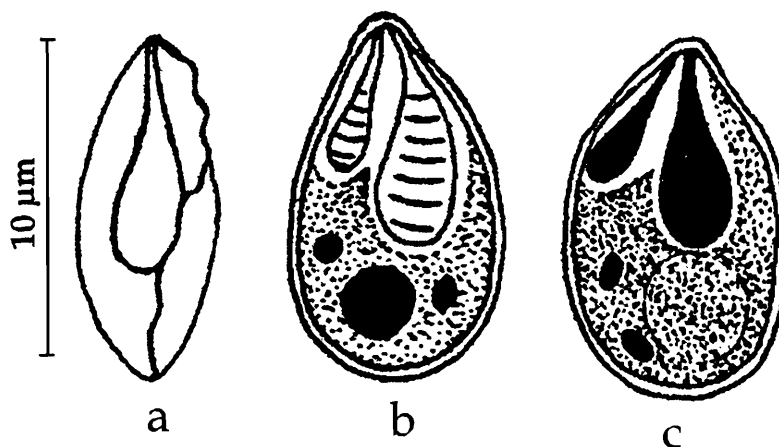


Fig. 197. *Myxobolus undasuturæ* : a. Fresh spore sutural view, b. Spore valvular view, c. Spore stained with Giemsa

capsule, 3-4 while inside the smaller capsule; sporoplasm finely granular binucleate filling the spore cavity; iodophilous large, spherical.

Size : Spore length 10.0–11.0 (10.6) μm , width 5.0–6.0 (5.7) μm ; polar capsule (large) length 5.05–6.5 (6.15) μm , width 2.0–2.5 (2.35) μm ; polar capsule (small) length 3.0–3.5 (3.2) μm , width 1.0–1.2 (1.1) μm .

Host : *Amblypharyngodon mola* (Ham); *site of Infection* : urinary bladder; *pathogenicity*; not apparent.

Distribution : India : West Bengal (Villages of Hugli district).

198. *Myxobolus vanivilasae* Seenappa and Manohar, 1980b
(Fig. 198 a-b)

Diagnosis : Cysts white, oval, 0.45–2.18 mm x 0.33–1.95 mm in size; spores oval in valvular view, lenticular in sutural view; shell valves thick, smooth, symmetrical; sutural ridge clear; sutural line not clear; polar capsules pyriform, equal, sometimes unequal; intercapsular ridge small, triangular; sporoplasm binucleate occupying the entire extra capsular space; iodophilous vacuole present.

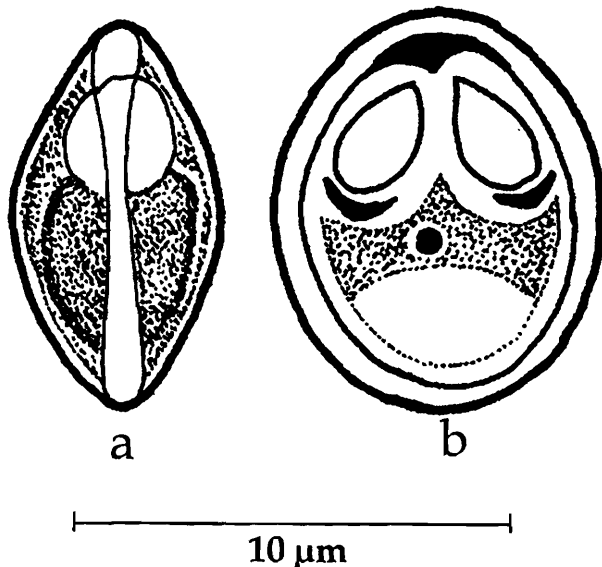


Fig. 198. *Myxobolus vanivilasae* : a. Fresh spore sutural view, b. Spore valvular view

Size : Spore length 8.0–10.0 μm , width 7.0–9.0 μm ; polar capsule length 3.0–4.0 (3.57) μm , width 2.0–3.0 (2.57) μm ; polar capsule (if unequal) (small) length 2.5–3.5 (2.98) μm , width 2.0–3.0 (2.5) μm ; polar filament (long) length, 24.6–49.0 μm ; polar filament (short) 18.6–29.0 μm .

Host : *Cirrhina mrigala* (Ham.); *site of infection* : beneath the scales all over the body; *pathogenicity*; not apparent.

Distribution : India : Karnataka (Vanivilasagar farm ponds).

199. *Myxobolus variformis* n. comb.
(Syn. *Myxobolus variabilis* Haldar, Samal and Mukhopadhyay, 1996)
(Fig. 199 a-b)

Diagnosis : Spore elongated pyriform; anterior end pointed, posterior end rounded; shell valves thick, variable in size; sutural line distinct; polar capsules unequal, pyriform with blunt anterior end; sporoplasm cup-shaped, granular, binucleate; iodophilous vacuole present; spores exhibiting distinct morphological variability when infecting different organs.

Size : Spore from gills : length 13.0-17.9 (15.2) μm , width 4.9-8.1 (5.65) μm ; polar capsule (large) length 8.1-11.4 (9.67) μm , width 1.6-4.0 (2.84) μm ; polar capsule (small) length 6.5-11.4 (8.6) μm , width 1.6-3.2 (2.28) μm .

Spore from body muscles : length 11.0-16.3 (13.1) μm , width 4.9-8.1 (6.93) μm ; polar capsule length 6.5-9.8 (6.3) μm , width 1.6-3.2 (2.61) μm .

Host : *Mystus gulio* (Ham.); **site of infection :** body muscles and gills; **pathogenicity;** not recorded.

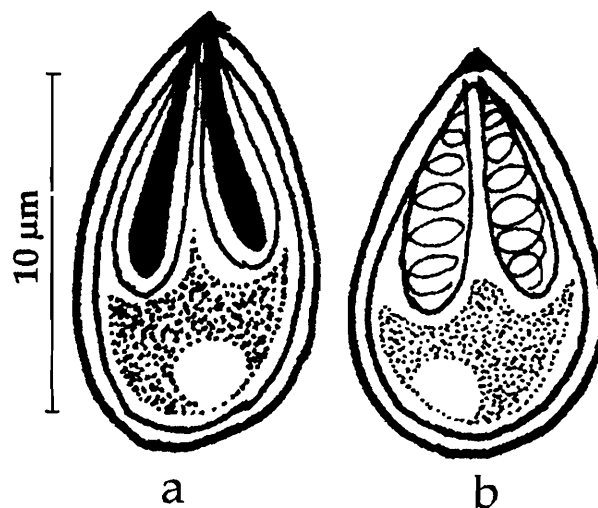


Fig. 199. *Myxobolus variformis* n. comb. : a. Fresh spore valvular view, b. Spore stained with Giemsa

Distribution : India : Orissa (Chilka lake, Bahuda estuary).

Remarks : *Myxobolus variabilis* is a preoccupied name. Jaczo (1940) described *Myxobolus variabilis* from *Abramis brama* and it differs considerably in morphometrics from the present form described by Haldar *et al.* (1996) from *Mystus gulio*. We therefore propose to change the name as *Myxobolus variformis* n. comb.

200. *Myxobolus vedavatiensis* Seenappa and Manohar, 1981
(Fig. 200)

Diagnosis : Spore histozoic, ovoidal in valvular view, lenticular in sutural view; valves moderately smooth, symmetrical; sutural ridge very clear, broad; polar capsules ovoidal, unequal, convergent; smaller capsule pyriform, larger one ovoidal; intercapsular process large, triangular; sporoplasm shield-shaped, granular, binucleate, filling the extracapsular cavity; iodophilous vacuole present.

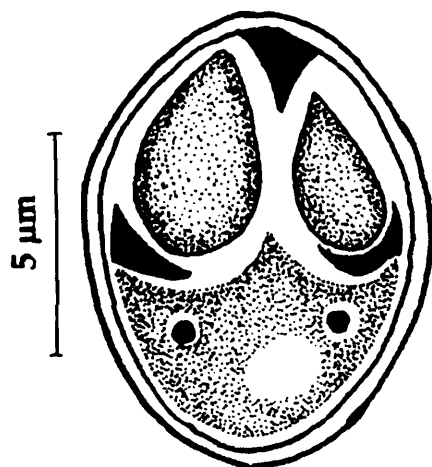


Fig. 200. *Myxobolus vedavatiensis* : Fresh spore valvular view

Size : Spore length 13.0-15.0 (13.8) μm , width 8.0-10.0 (9.2) μm ; polar capsule (large) length 6.0-7.0 (6.2) μm , width 3.0-4.0 (3.4) μm ; polar capsule (small) length 3.0-5.0 (3.9) μm , width 2.0-3.0 (2.6) μm .

Host : *Cirrhina mrigala* (Ham.); **site of infection :** gills; **pathogenicity;** not recorded.

Distribution : India : Karnataka (Vanivilas sagar farm ponds).

201. *Myxobolus venkateshi*
Seenappa and Manohar, 1981

(Fig. 201 a-e)

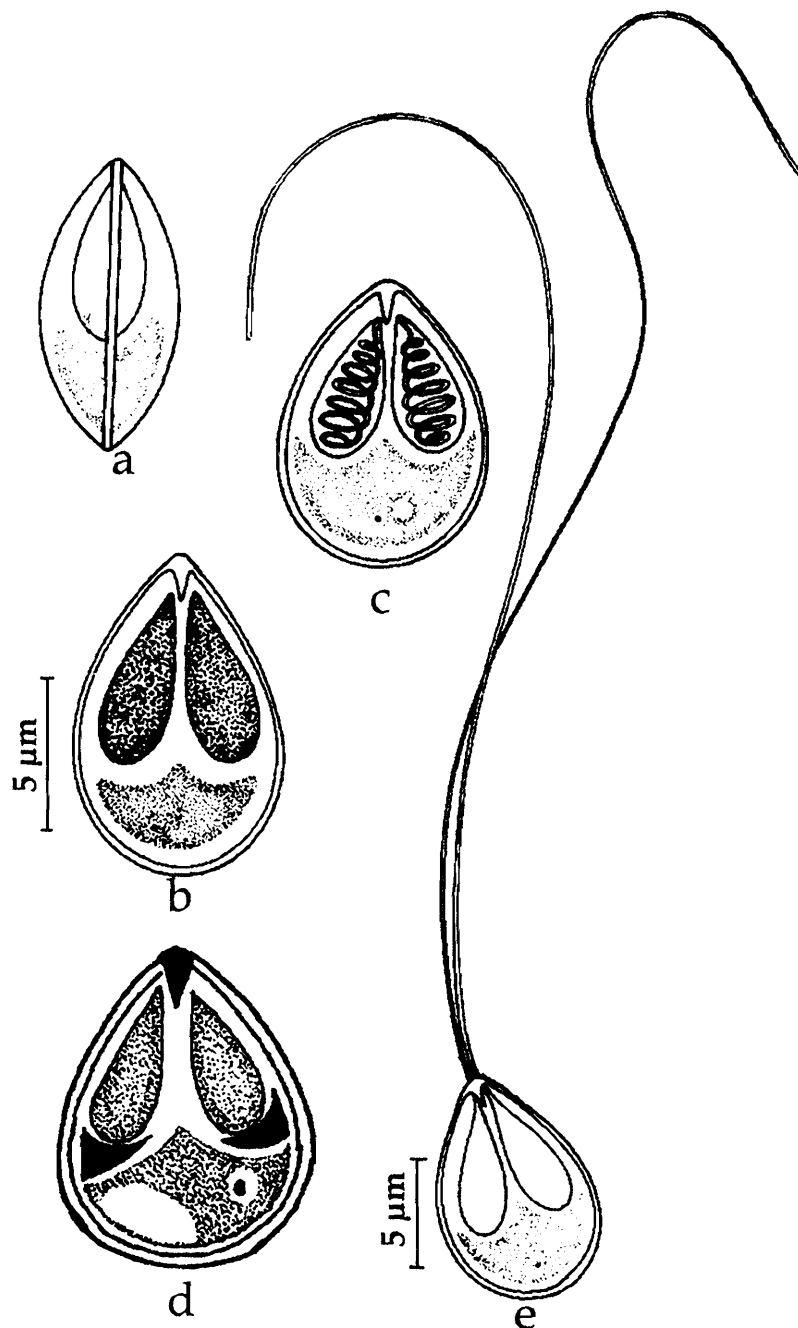


Fig. 201. *Myxobolus venkateshi* : a. Fresh spore sutural view, b & c. Spore valvular view, d. Spore stained with Giemsa, e. Spore with extruded polar filament

Diagnosis : Spores histozoic, egg-shaped, narrow anteriorly with a small protuberance in valvular view; shell valves smooth, symmetrical; polar capsules pyriform, equal, convergent; intercapsular process long, sharp, pointed; sporoplasm granular, uninucleate, filling the extracapsular cavity; iodophilous vacuole present.

Size : Spore length 9.0-10.0 (9.75) μm , width 7.0- 8.0 (7.15) μm ; polar capsule length 5.0-6.0 (5.25) μm , width 2.0 μm .

Host : *Cirrhina mrigala* (Ham.) *Heteropneustes fossilis* (Bloch); **site of infection :** gills; **pathogenicity :** not recorded.

Distribution : India : Karnataka (Vanivilas sagar farm ponds), Kerala (Pulikuzhi).

Remarks : Krishna Kumar (2000) reported this species from Kerala.

202. *Myxobolus yogindrai* (Tripathi, 1952) emend. Landsberg and Lom, 1991
(Syn. *Myxobolus sphericum* Tirpathi, 1952)
(Fig. 202 a-b)

Diagnosis : Spore oval in front view, lenticular in side view; anterior end wider than the posterior end; valves moderately thick, smooth and symmetrical; sutural ridge prominent with four thickenings along its posterior margin; sutural line indistinct; polar capsules spherical, equal and convergent; iodophilous vacuole oval, prominent, 2.0-2.7 μm in diameter.

Size : Spore length 9-9.5 μm , width 7.2 μm ; polar capsule 2.8-3.6 μm diameter.

Host : *Cirrhina mrigala* (Ham); **site of infection** : inner side of the scales; **pathogenicity** : not recorded.

Distribution : India : West Bengal (North 24 Parganas district).

Remarks : Landsberg and Lom, 1991 while reviewing the genus *Myxobolus* renamed *Myxobolus sphericum* Tripathi, 1952 as *M. yogindrai* since the name *Myxobolus sphericum* is preoccupied.

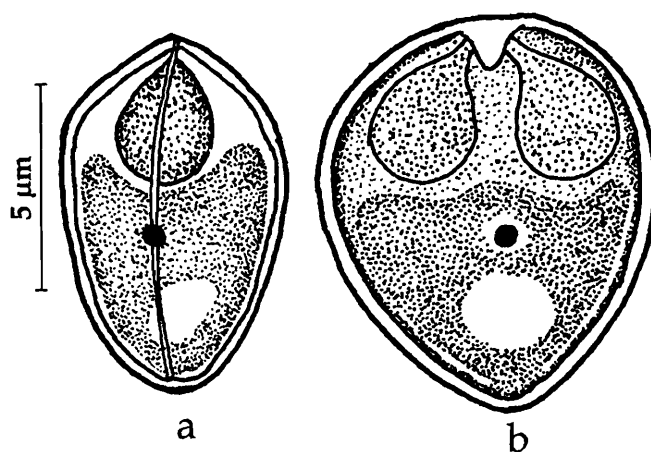


Fig. 202. *Myxobolus yogindrai* : a. Fresh spore sutural view, b. Spore valvular view

203. *Myxobolus* sp. Padma Dorothy and Kalavati, 1992b
(Fig. 203 a-c)

Diagnosis : Spores broadly oval, enveloped in a thin indistinct mucous sheath forming 5-6 bluntly pointed posterior processes, the two peripheral processes thicker than the central ones; valves thick, smooth; sutural line broad, straight; polar capsules 2, oval or pyriform, equal convergent; polar filaments forming 5-6 coils while inside the capsule, thin and uniform when extended; sporoplasm homogenous, granular and occupying the posterior part of the spore.

Size : Spore length 6.9-8.6 (7.74) μm , width 5.6-6.5 (6.02) μm ; polar capsule

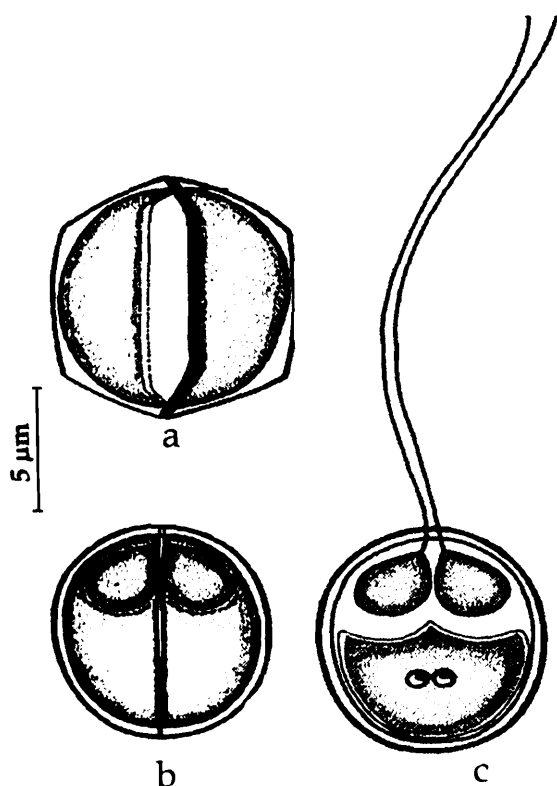


Fig. 203. *Myxobolus* sp. : a. Fresh spore sutural view, b. Spore valvular view, c. Spore with extruded polar filament

length 2.6-3.5 (3.32) μm , width 1.7-2.6 (2.06) μm ; polar filament length 25.6-28.8 (26.4) μm .

Host : *Liza macrolepis*, *Mugil cephalus*; *site of infection* : intestine; *pathogenicity* : not recorded

Distribution : India : Andhra Pradesh (Visakhapatnam harbour).

Remarks : Padma Dorothy and Kalavati (1992b) reported this as unnamed species and could not assign a specific name for want of some more information

Genus *Henneguya* Thelohan, 1892

Diagnosis : As in the key.

Remarks : There has been considerable confusion regarding the identification of the genera *Henneguya* Thelohan, 1892 and *Unicauda* Davis, 1944. Gupta and Khera (1987) reviewed these two genera and synonymised *Unicauda ophicephali* Tripathi, 1952 with *Hynenguya ophicephali* Chakravarty, 1939 and transferred *U. basiri* Bhatt and Siddiqui, 1964, *U. bicornuata* Ray Chaudhuri and Chakravarty, 1970, *U. bengalensis* Ray Chaudhuri and Chakravarty, 1970, *U. chaudhuryi* Bajpai and Haldar, 1982 and *U. ritae* Bajpai and Haldar, 1982 to the genus *Hennegeguya* since caudal appendage of *Unicauda* is not an extension of shell valves and composed of different material. Another species viz., *Henneguya jubili* Qardi, 1969 which was recorded from the gills of freshwater fish, *Notopterus notopterus* from Hyderabad city, Andhra Pradesh by Qardi (1969) in the abstract book "Progress in Protozoology" published by the 3rd Int. Congr. Protozool., p. 241, is considered as "*nomen nudum*" and hence not included.

Key to the species

1. Caudal prolongation bifurcated 4
2. Caudal prolongation undivided throughout 5
3. Caudal process of different configuration 6
- 4.1. Polar capsules equal
 - 4.1.1 Spore oval with rounded ends; anterior extremity narrow; valves smooth, thin symmetrical; polar capsules elongated, pyriform with a duct; spore 9.28-9.99 (9.72) μm x 4.0-4.78 (4.5) μm *H. ganapatiae*

- 4.1.2 Spore oval, ends rounded, covered with a mucous coat; valves symmetrical, thin, smooth; polar capsule, pyriform; spore 36.8–40.0 (37.6) μm x 3.2–3.6 (3.24) μm
H. megalopsi
- 4.1.3 Spore compressed along the sutural line; caudal processes 'U'-shaped; polar capsules pyriform; spore 55.0–55.0 μm x 3.2–4.0 μm*H. waltirensis*
- 4.1.4 Spore compressed with round anterior end; valves smooth with a characteristic thickening running along the middle of the spore; polar capsules pyriform; spore 10.0 –12.0 μm x 6.0 – 8.5 μm *H. otolithi*
- 4.1.5 Spore ovoid; caudal processes originate from two flap-like structures; valves smooth; polar capsules pyriform with a distinct neck; spore 47.0–60.0 μm x 7.0–8.0 μm *H. tachysuri*
- 4.1.6 Spore oblong; anterior end round, valves smooth; polar capsules pyriform; spore 18.0–25.0 (20.25) μm x 3.0–5.0 (3.85) μm *H. nandi*
- 4.1.7 Spore pyriform; valves thin symmetrical; polar capsule pyriform; spore 9.0–10.8 μm x 4.0–4.78 μm*H. latesi*
- 4.1.8 Spore oval, compressed parallel to sutural plane, anterior end attenuated; polar capsules pyriform; spore 20.0–30.6 (23.6) μm x 2.1–3.0 (2.6) μm
..... *H. zahoori*
- 4.1.9 Spore body elongate or oval; anterior extremity bluntly rounded; valves smooth, uniform; polar capsules pyriform; spore 24.4–36.7 (31.2) μm x 3.3–8.1(5.5) μm
H. rubicundi
- 4.1.10 Spore pyriform, elongated; polar capsules with a transverse band; spore 35.8–53.8 (46.3) μm x 13.0–18.7 (16.14) μm*H. mystasi*
- 4.2. Polar capsule unequal
- 4.2.1 Spore oblong, anterior end round; valves smooth, symmetrical; polar capsules pyriform; spore 17.6–19.3 (18.5) μm x 5.5–6.6 (6.4) μm *H. namae*
- 4.2.2 Spore elongated, ellipsoidal or lanceolate, anterior end fusiform, pointed, posterior end flat; polar capsules elongate; one pyriform, other with long duct appearing like a golf stick; spore 11.5–13.0 μm x 4.5– 5.0 (3.75) μm
.....*H. notopterae*
- 4.2.3 Spore more or less ovoidal or oblongate; anterior end broad; valve symmetrical; polar capsules pyriform; spore 41.5–52.5 μm x 6.18–7.2 μm *H. ophicephali*

- 4.2.4 Spore elongated or oval, anterior end round; valves smooth; polar capsules pyriform; spore 9.24–12.32 (11.0) μm x 4.62–5.39 (4.62) μm *H. qadrii*
- 4.2.5 Spore elongate, anterior end narrow; valves thin, smooth and uniform; polar capsules pyriform, terminal, large capsule often curved.....*H. singhi*
- 5.1 Polar capsule equal
- 5.1.1 Spore body oblongate with gradually pointed anterior end; valves symmetrical, smooth; polar capsules pyriform; spore 26.4-29.15 (28.41) μm x 2.75-3.85 (3.29) μm ; caudal appendage length 11.55–13.75 (12.61) μm *H. bengalensis*
- 5.1.2 Spore oblongate, anterior extremity more or less rounded; polar capsules pyriform; spore 26.3-33.2 (30.0) μm x 3.3-4.1 (3.7) μm ; caudal process length 14.5-20.0 (17.7) μm *H. chaudhuryi*
- 5.1.3 Spore fusiform anterior end slightly curved, blunt; valve symmetrical, thin, smooth ; polar capsule tubular; spore 27.0–40.0 (32.33) μm x 3.0-4.0(3.75) μm
H. mystusia
- 5.1.4 Spore hyaline, broadly oval; valve smooth and thin; polar capsule oval to pyriform with short neck; spore 14.4–19.2 (16.83) μm x 8.0–11.2 (9.77) μm
.....*H. renalis*
- 5.1.5 Spore oblongate with pointed anterior end; polar capsule pyriform; spore 39.9-44.8 (42.4) μm x 5.0-5.8 (5.2) μm *H. ritae*
- 5.2 Polar capsule unequal
- 5.2.1 Spore pyriform; valves moderately thick, smooth, larger polar capsules pyriform, smaller capsule ovoid, convergent, opening to a side from the long axis; spore 47.0–60.0 μm x 6.0-8.0 μm *H. thermalis*
- 6.1 Spore body oblongate, anterior end extremely rounded; polar capsules pyriform; spore 26.4-29.15 μm x 2.75-3.89 μm *H. bicornuata*
- 6.2 Spore elongated, main body of the spore oblongate with rounded anterior end, caudal prolongation bifurcated after some distance and curved characteristically at their distal end in the form of two unequal arms of the 'U'; spore 20-25.5 (21.9) μm x 3.3–5.0(4.3) μm *H. bleekeri*

204. *Henneguya basari* (Bhatt and Siddiqui, 1964) emend.
Gupta and Khera, 1987
(Syn. *Unicauda basari* Bhatt and Siddiqui, 1964)
(Fig. 204)

Diagnosis : Cysts oval, opaque white, 0.5 mm - 1.0 x 0.3 mm in size with well developed cyst membrane; spore oval, compressed parallel to the sutural plane; posterior end drawn out into a single undivided caudal appendage; spore valves smooth, symmetrical; sutural line faint; polar capsules 2, pyriform, equal, occupying less than half of the length of the spore; sporoplasm uni or binucleate occupying the entire extracapsular spore cavity, iodophilus vacuole present.

Size : Spore length (total including caudal appendage) 25.6–39.2 (34.3) μm ; width 3.2–4.4 (3.7) μm ; caudal appendage length 10.0–20.3 (15.3) μm ; polar capsule length 5.0–7.4 (6.3) μm ; width 1.4–2.0 (1.7) μm .

Host : *Ophicephalus punctatus*; **site of infection** : pharyngeal epithelium; **pathogenicity** : not apparent.

Distribution : India : Uttar Pradesh (Aligarh).

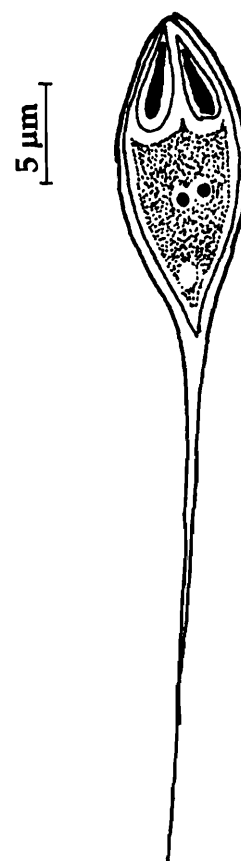


Fig. 204. *Henneguya basari*
: Spore valvular view

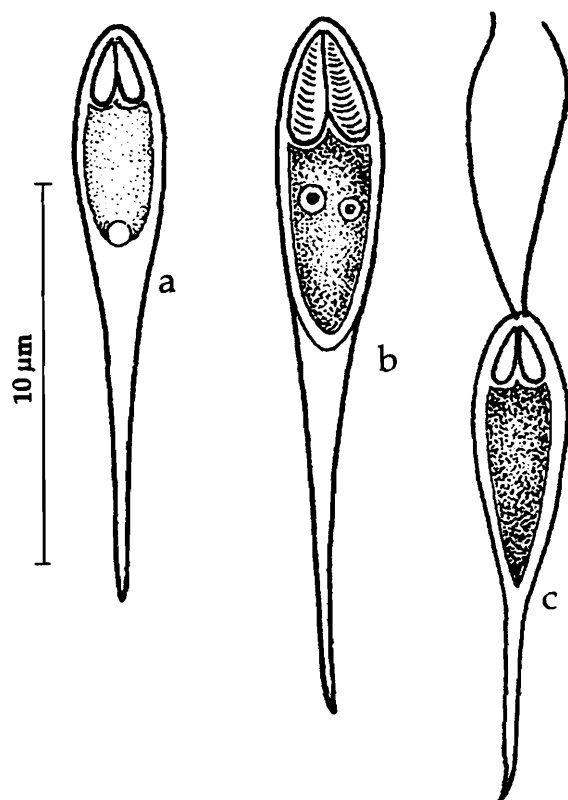


Fig. 205. *Henneguya bengalensis* : a. Fresh spore valvular view, b. Spore stained with Giemsa, c. Spore with extruded polar filament

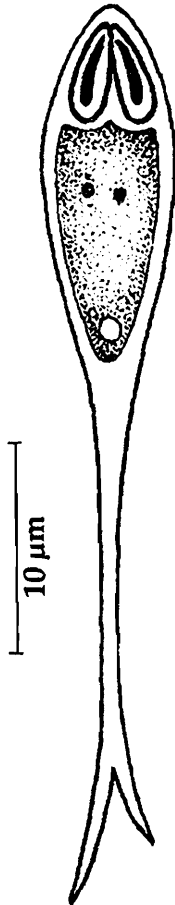
205. *Henneguya bengalensis* (Ray Chaudhuri and Chakravarty, 1970) emend.
Gupta and Khera, 1987
(Syn. *Unicauda bengalensis* Ray Chaudhuri and Chakravarty, 1970)
(Fig. 205 a-c)

Diagnosis : Cysts oval, whitish in colour, 1.0 to 1.25 mm in diameter; spore body oblongate, with gradually pointed anterior end, continued posteriorly into a long caudal prolongation; valves symmetrical, smooth; polar capsules, two, pyriform, equal, situated at the anterior end of the spore body; coiled polar filament distinct in each capsule; sporoplasm binucleate, granular, filling the extracapsular region; iodophilous vacuole round.

Size : Spore length 26.4-29.15 (28.41) μm , width 2.75-3.85 (3.29) μm ; caudal appendage length 11.55-13.75 (12.61) μm ; polar capsule length 3.3-3.56 (3.53) μm , width 1.1-1.38 (1.21) μm ; polar filament length 18.0-27.0 (21.75) μm .

Host : *Channa* (= *Ophicephalus*) *punctatus* (Bloch); *site of infection* : buccal cavity; *pathogenicity* : not recorded.

Distribution : India : West Bengal (North 24-Parganas district).



206. *Henneguya bicornuata* (Ray Chaudhuri and Chakravarty, 1970) emend. Gupta and Khera, 1987 (Syn. *Unicauda bicornuata* Ray Chaudhuri and Chakravarty, 1970) (Fig. 206)

Diagnosis : Cyst oval milky white, 1.2 to 1.5 mm in diameter; spore body oblongate, anterior end extremely rounded, posterior portion gradually tapering and continued into a long caudal prolongation undivided for a distance but forked at its extreme end; polar capsules two, equal, pyriform and situated at the anterior end; polar filament distinct in each capsule; sporoplasm round; iodophilous vacuole round.

Size : Spore length 26.4-29.15 μm , width 2.75-3.89 μm ; caudal appendage length 11.55-13.75 μm ; polar capsule length 3.3-3.56 μm , width 1.1-1.38 μm .

Host : *Ophicephalus punctatus* (Bloch); *site of infection* : branchial epithelium; *pathogenicity* : not apparent.

Distribution : India : West Bengal (Calcutta district).

Fig. 206. *Henneguya bicornuata* : Spore valvular view

207. *Henneguya bleekeri* Haldar and Mukherjee, 1985 (Fig. 207 a-b)

Diagnosis : Cyst white, oval to rounded 1.5 mm x 1.0 mm; spore elongated, main body of the spore oblongate with rounded anterior end, lenticular in side view; caudal prolongation bifurcated after some distance and curved characteristically at their distal end in the form of two unequal arms of the 'U'; sutural line straight; polar capsules, two, equal; polar filament forming 6-8 coils while inside the capsule; sporoplasm filling the entire extracapsular cavity; iodophilous vacuole present.

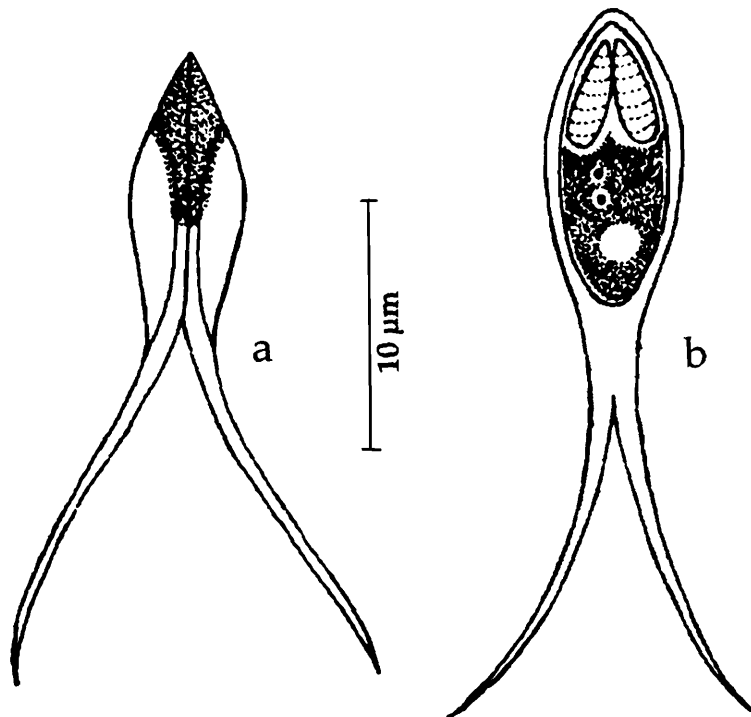


Fig. 207. *Hennaguya bleekeri* : Spore valvular view, b. Spore stained with Giemsa

Size : Spore total length 20-25.5 (21.9) μm , width 3.3-5.0 (4.3) μm ; caudal process length 10.1-15.5 (13.0) μm ; polar capsule length 3.3-4.4 (3.6) μm , width 1.1-2.2 (1.7) μm .

Host : *Mystus bleekeri* (Day); *site of infection* : kidney; *pathogenicity* : not apparent.

Distribution : India : West Bengal (Nadia district).

208. *Hennaguya chaudhuryi* (Bajpai and Haldar, 1982) emend. Gupta and Khera, 1987 (Syn. *Unicauda chaudhuryi* Bajpai and Haldar, 1982a)

(Fig. 208 a-c)

Diagnosis : Spore oblongate, anterior extremity more or less rounded, posterior end extended as an undivided caudal process; polar capsules two, pyriform, identical and convergent anteriorly, with 6-7 coils of polar filament; sporoplasm granular, binucleate not extending into caudal process; iodophilous vacuole present.

Size : Spore length 26.3-33.2 (30.0) μm , width 3.3-4.1 (3.7) μm ; caudal process length 14.5-20.0 (17.7) μm ; polar capsule length 5.0 - 7.5 (6.0) μm , width 1.6 μm .

Host : *Channa* (= *Ophicephalus*) *punctatus* Bloch; *site of infection* : gill filaments; *pathogenicity* : not apparent.

Distribution : India : West Bengal (Nadia district).

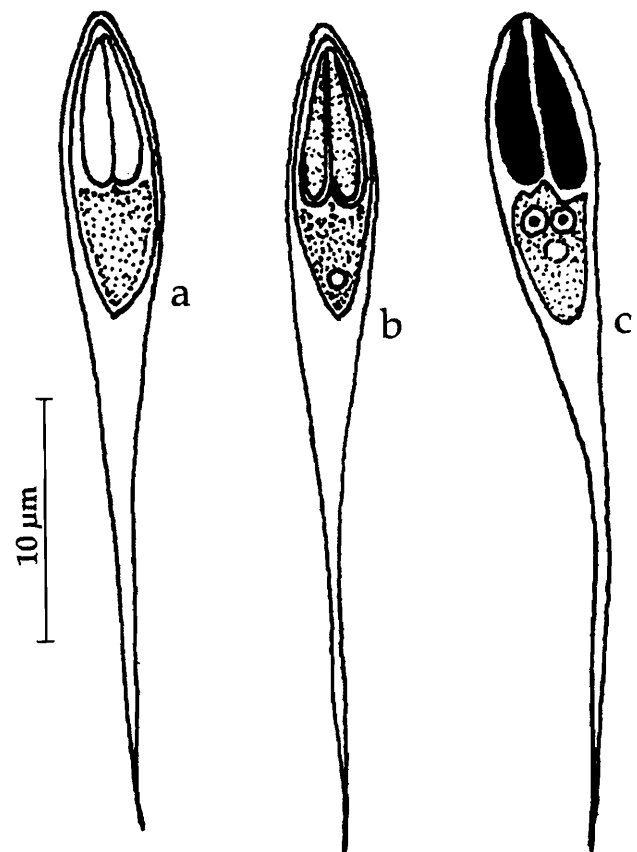


Fig. 208. *Hennaguya chaudhuryi* : a & b. Fresh spores valvular view, c. Spore stained with Giemsa

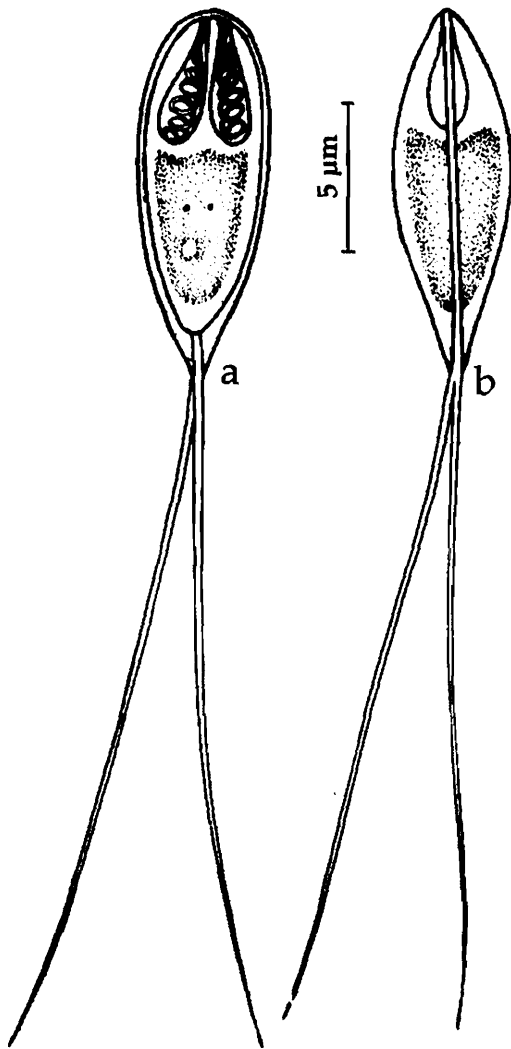


Fig. 209. *Henneguya ganapatiae* : a. Fresh spore valvular view, b. Spore sutural view

210. *Henneguya latesi* Tripathi, 1952
(Fig. 210 a-b)

Diagnosis : Cyst small with mature spore; spore pyriform in front view, fusiform in sutural view; shell valve thin and symmetrical, with two very thin prolongations posteriorly; polar capsule pyriform, slightly convergent; sporoplasm granular and filling most of the extracapsular cavity; iodophilous vacuole present.

Size : Spore body length 9.0-10.8 µm, width 4.0-4.78 (4.5) µm; caudal processes length 17.2-25.0 µm; polar capsule length 3.6 µm, width 2.0 µm.

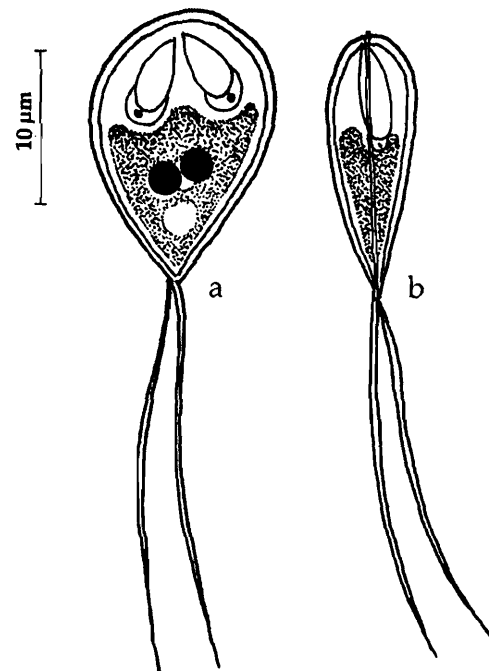


Fig. 210. *Henneguya latesi* : a. Fresh spore valvular view, b. Spore sutural view

209. *Henneguya ganapatiae* Qadri, 1970
(Fig. 209 a-b)

Diagnosis : Spores ovoid with round, narrow anterior extremity; posterior end drawn out into thin, flexible, slightly curved caudal processes; valves smooth, thin symmetrical; polar capsules equal, elongated, convergent, pyriform with a duct; sporoplasm homogenous, occupying the entire extracapsular spore cavity but not extending into intercapsular space; iodophilous vacuole large.

Size : Spore body length 9.28-9.99 (9.72) µm, width 4.0-4.78 (4.5) µm; caudal processes length 22-25 (22.25) µm; polar capsule length 3.21-2.57 (3.32) µm, width 1.4 -1.78 (1.64) µm.

Host : *Notopterus notopterus*; **site of infection :** gills contents; **pathogenicity :** not apparent.

Distribution : India : Andhra Pradesh (Lake near Hyderabad city).

Host : *Lates calcarifer* (Bloch.); *site of infection* : gills; *pathogenicity* : not apparent.

Distribution : India : West Bengal (North 24-Parganas district).

211. *Hennaguya megalopsi* Kalavati, Venkataeswara Rao, Vaidehi, 1991
(Fig. 211 a-c)

Diagnosis : Coelozoic, spore oval with rounded ends in valvular view; covered with a mucous coat; posterior end drawn out into a bifurcated caudal extension; when spores coming in contact with water the two caudal prolongations divaricated with a fine mucous extension between the divaricated processes; valves symmetrical, thin, smooth; sutural line thin, straight; polar capsule two, equal, pyriform, parallel, terminal; sporoplasm oval, iodophilous vacuole absent.

Size : Spore total length 36.8–40.0 (37.6) μm ; spore body length 11.2–12.8 (12.4) μm , width 3.2–3.6 (3.24) μm , thickness 2.5–3.0 (2.87) μm ; length of the caudal process 25.6–37.2 (34.2) μm ; polar capsule length 4.4 μm , width 0.8–1.0 (0.8) μm ; polar filament length 12.0–18.0 (15.86) μm .

Host : *Megalops cyprinoides*. (Ham.); *site of Infection* : Gall bladder; *pathogenicity* : not recorded.

Distribution : India : Orissa (Chilka Lake).

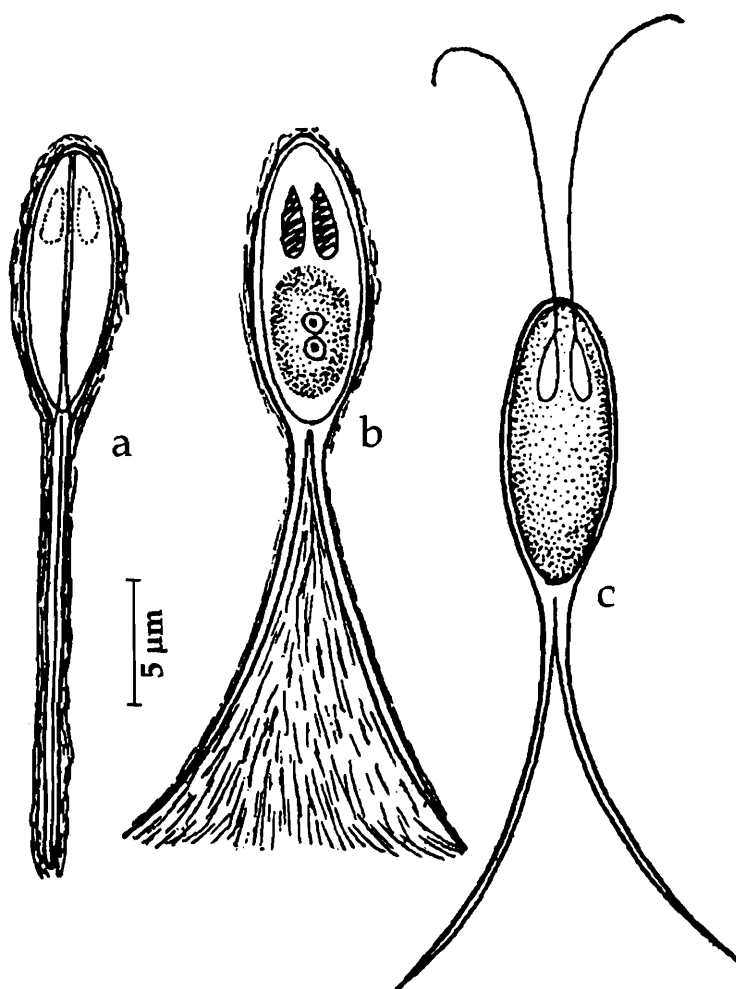


Fig. 211. *Hennaguya megalopsi* : a. Fresh spore sutural view, b. Spore valvular view, c. Spore with extruded polar filament

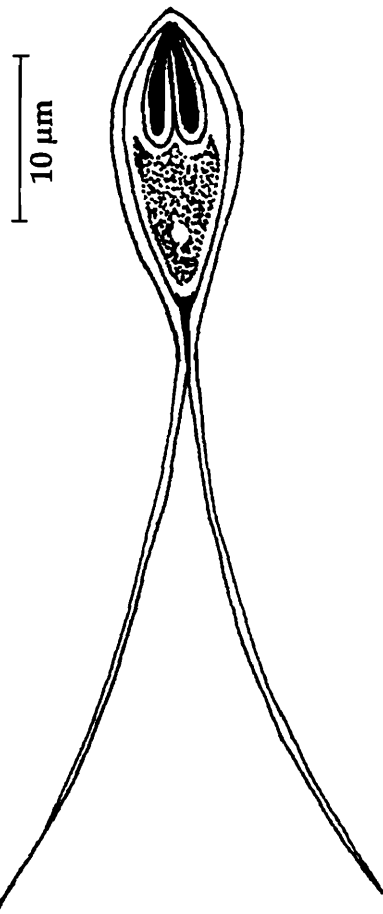


Fig. 212. *Henneguya mystasi* : a. Fresh spore valvular view

212. *Henneguya mystasi* Haldar, Samal and Mukhopadhyay, 1997 (Fig. 212)

Diagnosis : Spore body pyriform and elongated, broadest in the middle narrowing to ends, posterior end gradually tapering into a long bifurcated caudal processes; spore valves smooth, thin; sutural line straight; polar capsules 2, equal, pyriform, with transverse bands; sporoplasm finely granular, binucleate filling the entire extracapsular spore cavity.

Size : Spore total length 35.8 -53.8 (46.3) μm ; spore body length 13.0 -18.7 (16.14) μm , width 1.6-4.0 (2.92) μm ; length of caudal process 19.5-37.4 (29.85) μm ; polar capsule length 4.0-4.9 (4.36) μm , width 1.6-3.2 (1.92) μm .

Host : *Mystus gulio* (Ham.); **site of infection** : gills; **pathogenicity** : not apparent.

Distribution : India, Orissa (Chilka Lake).

213. *Henneguya mystusia* Sarkar, 1985b (Fig. 213 a-c)

Diagnosis : Cyst small, creamy-white, oval, 0.2 mm x 0.1 mm, polysporous; spore fusiform in valvular view, anterior end slightly curved, blunt, obovate in sutural view; posterior end tapering, caudal prolongations long, fine; valves symmetrical, thin, smooth; sutural line thin slightly curved; polar capsule two, equal, tubular; polar filament not distinct; sporoplasm granular, binucleate filling the entire extracapsular spore cavity; iodophilous vacuole spherical.

Size : Spore total length 27.0-40.0 (32.33) μm ; spore body length 12.0-15.0 (13.0) μm , width 3.0- 4.0 (3.75) μm ,

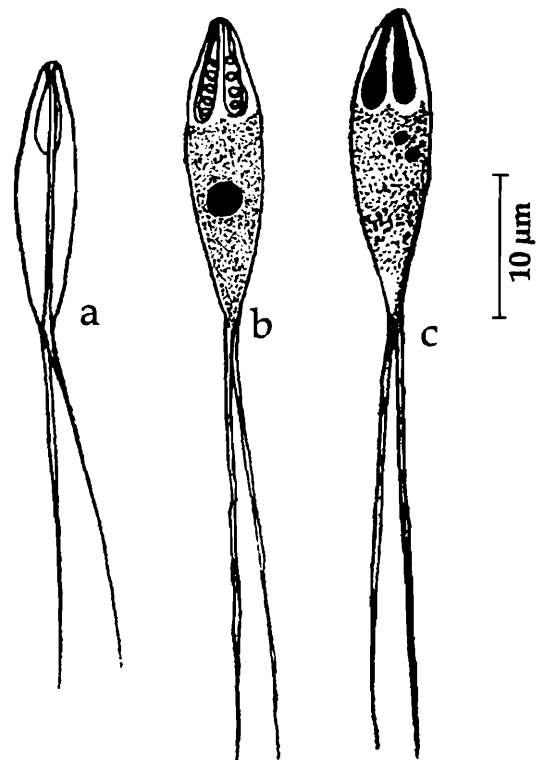


Fig. 213. *Henneguya mystusia* : a. Fresh spore valvular view, b & c. Spore stained with Giemsa

thickness 2.5–3.0 (2.87) μm ; length of the caudal process 17.0–25.0 (19.33) μm ; polar capsule length 5.0–6.0 (5.04) μm , width 1.0–1.3 (1.2) μm .

Host : *Mystus* sp. (Ham.); *site of infection* : gill filaments; *pathogenicity* : Krishna kumar (2002) noticed dilatation of capillaries of primary gill lamellae, atrophy of secondary gill lamellae evidently causing functional disruption. Rupture of the cyst resulted in haemorrhage.

Distribution : India : West Bengal (Chinsurah, Hugli district); Kerala (Pulikuzhi)

Remarks : Krishnakumar (2000) described this species from Kerala infecting *Aplocheilus lineatus*.

214. *Henneguya namae* Haldar, Das and Sharma, 1983
(Fig. 214 a-d)

Diagnosis : Cyst small, creamy white, oval, 180.0–220.0 μm x 150.0–190.0 μm in size; polysporous; spore body oblong, anterior end round, posterior end gradually tapering into a long bifurcated, devaricated caudal process; spore valves smooth, symmetrical, thick sutural ridge, prominent; polar capsules 2, unequal, pyriform, on either side of the median line; polar filament forming 9–10 coils inside the large capsule and 8–9 coils in smaller capsule; sporoplasm finely granular, binucleate filling the entire extracapsular spore cavity; iodophilous vacuole present.

Size : Spore body length 17.6–19.3 (18.5) μm , width 5.5–6.6 (6.4) μm , thickness 4.4–5.0 (4.8) μm ; length of caudal process 17.6–18.7 (18.5) μm ; polar capsule (large) length 5.5–6.0 (5.8) μm , width 1.1 μm ; polar capsule (small) length 4.4–5.0 (4.9) μm , width 1.1 μm ; polar filament length 15–20 μm .

Host : *Ambassis nama* (Ham & Buch); *site of infection* : gills and heart; *pathogenicity* : not apparent.

Distribution : India, West Bengal (Krishnanagar)

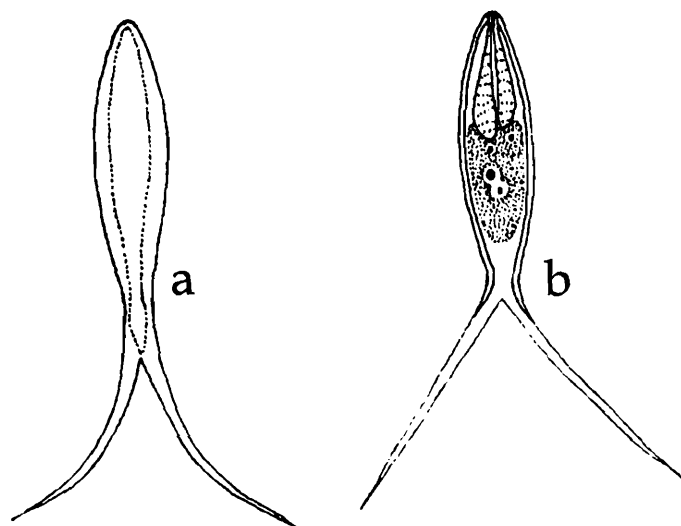


Fig. 214. *Henneguya namae* : a. Fresh spore valvular view, b & c. Spore stained with Giemsa, d. Spore with extruded polar filament

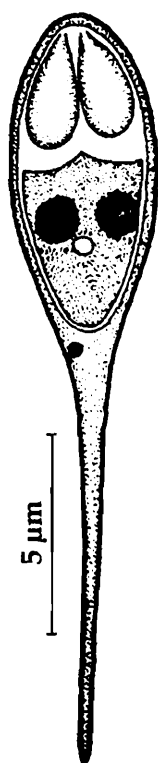

Fig. 215. *Henneguya nandi* : a.
Fresh spore valvular view

215. *Henneguya nandi* Gupta and Khera, 1987
(Fig. 215)

Diagnosis : Cysts opaque white, round, 0.399–0.450 mm x 0.342–0.402 mm in size, spore body oblong, anterior end round, posterior end gradually tapering into 2 long sometimes bifurcated caudal process; shell valves smooth; polar capsules 2, equal, pyriform, at the anterior end; sporoplasm finely granular, binucleate filling the entire extracapsular spore cavity; iodophilous vacuole present.

Size : Spore total length 18.0 – 25.0 (20.23) μm ; spore body length 9.0–11.0 (9.98) μm , width 3.0–5.0 (3.85) μm ; length of caudal process 9.0–15.0 (10.25) μm ; polar capsule length 3.2–4.0 μm (3.56), width 1.4–2.0 (1.645) μm ; polar filament length 15–20 μm .

Host : *Nandus nandus* (Hamilton); **site of infection** : gills and heart; **pathogenicity** : not apparent.

Distribution : India : Punjab (Ludhian and Harike).

216. *Henneguya notoapterae* Qadri, 1965
(Fig. 216 a-b)

Diagnosis : Spores elongated, ellipsoidal or lanceolate with long divided caudal processes; anterior end fusiform, pointed, posterior end flattened; sutural ridge fine; polar capsules elongate, unequal, one pyriform and the other is with long duct appearing like a golf stick; sporoplasm homogenous, iodophilous vacuole round, located in the posterior half of the spore.

Size : Spore body length 11.5–13.00 μm ; width 4.5–5.0 (3.75) μm ; length of the caudal process 40.5–42.0 μm ; polar capsule (large) length 5.0–5.5 μm , width 1.0–1.5 μm ; polar capsule (small) length 3.5–4.5 μm , width 1.0–1.25 μm .

Host : *Notopterus notoapterus*; **site of infection** : gills; **pathogenicity** : not apparent.

Distribution : India : Andhra Pradesh : (local fish market, Hyderabad city).

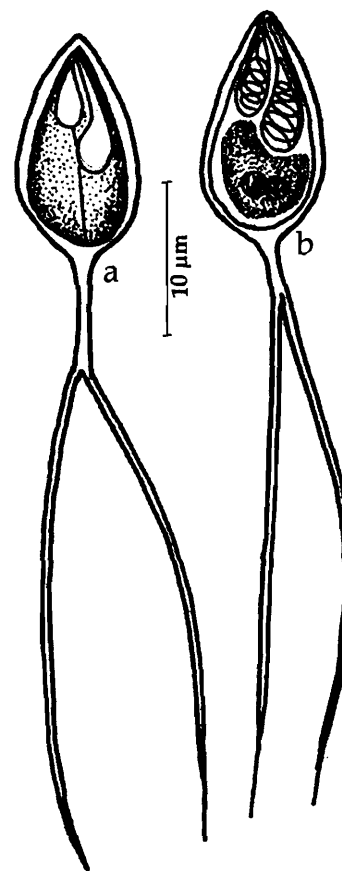


Fig. 216. *Henneguya notoapterae* : a.
Fresh spore's valvular view, b. Spore
stained with Giemsa

217. *Henneguya ophicephali* Chakravarty, 1939
(Syn. *Unicauda ophicephali* Tripathi, 1952)
(Fig. 217 a-d)

Diagnosis : Cysts spherical or oval, 2 mm in diameter; polysporous; spore more or less ovoidal or oblongate; anterior end broader and rounded, posterior end tapering and prolonged as a bifurcated caudal process and divaricated in spores from the gills and relatively approximated in those from the muscles; shell valves symmetrical; sutural ridge prominent; polar capsules pyriform, unequal; iodophilous vacuole 2.06 μm in diameter.

Size : Spore total length 41.5-52.5 μm , width 6.18-7.2 μm ; length of caudal process 26.0-32.0 μm ; polar capsule (large) length 6.18-9.27 μm , width 2.06-3.0 μm ; polar capsule (small) length 5.15-8.24 μm , width 2.06-3.0 μm ; polar filament (long) length 26-32 μm , polar filament (short) 26.0-32.0 μm .

Host : *Ophicephalus punctatus* (Bloch) and *Ophicephalus gachua* (Ham); **site of infection** : gills and muscles; **pathogenicity** : not apparent.

Distribution : India : West Bengal (Calcutta and North 24 - Parganas districts).

Remarks : Tripathi (1952) while describing *Unicauda ophicephali* from *Ophicephalus gachua* considered that *Henneguya ophicephali* described earlier by Chakravarty (1939) is similar and therefore transferred this species to genus *Unicauda* abolishing the species *H. ophicephali*. Later Gupta and Khera (1987) reexamined the descriptions of both the species and concluded that both of them belong to genus *Henneguya* since the caudal processes are extensions of the spore valves. Therefore, they abolished the species *Unicauda ophicephali* Tripathi, 1952 retaining *Henneguya ophicephali* Chakravarty, 1939. We agree with Gupta and Khera (1987) because the formation of caudal processes as extensions of spore valves is a distinctive feature of genus *Henneguya*.

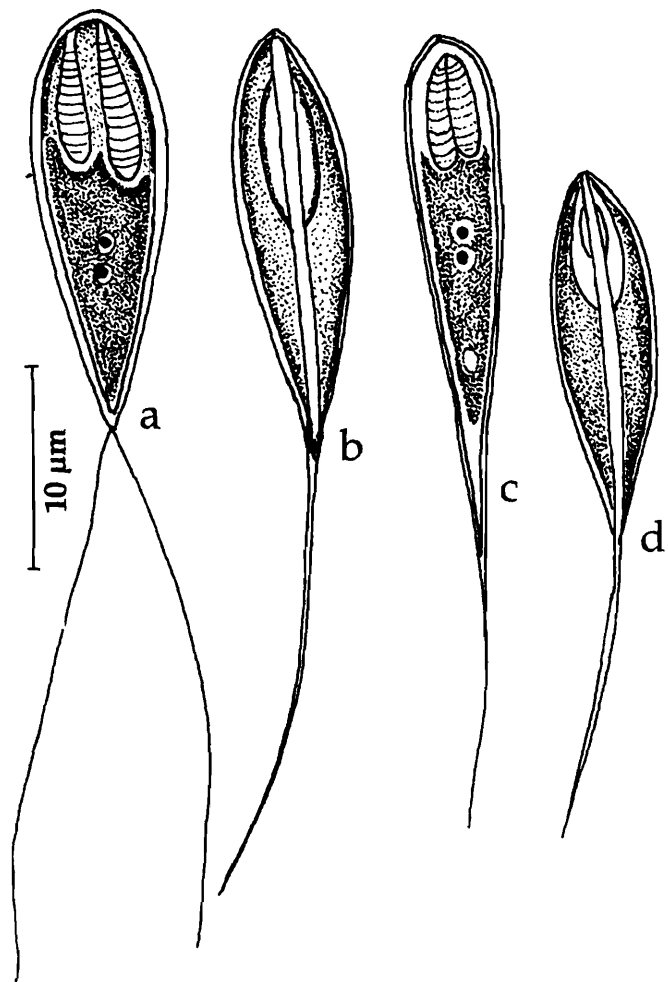


Fig. 217. *Henneguya ophicephali* : a. Fresh spores valvular view, b. Spore stained with Giemsa, c&d. Spores showing size variation

218. *Henneguya otolithi* Ganapati, 1941
(Fig. 218 a-c)

Diagnosis : Trophozoites round or ovoid; spore oval, compressed with round anterior end in valvular view, spindle-shaped in sutural view; spore valves prolonged as finely tapering processes; valves smooth with a characteristic thickening running along the middle of the spore; polar capsules 2, equal, pyriform, one on either side of the sutural line and opening independently; polar filament forming 5-6 coils while inside the capsule, uniformly thin when extended; sporoplasm finely granular; iodophilous vacuole present.

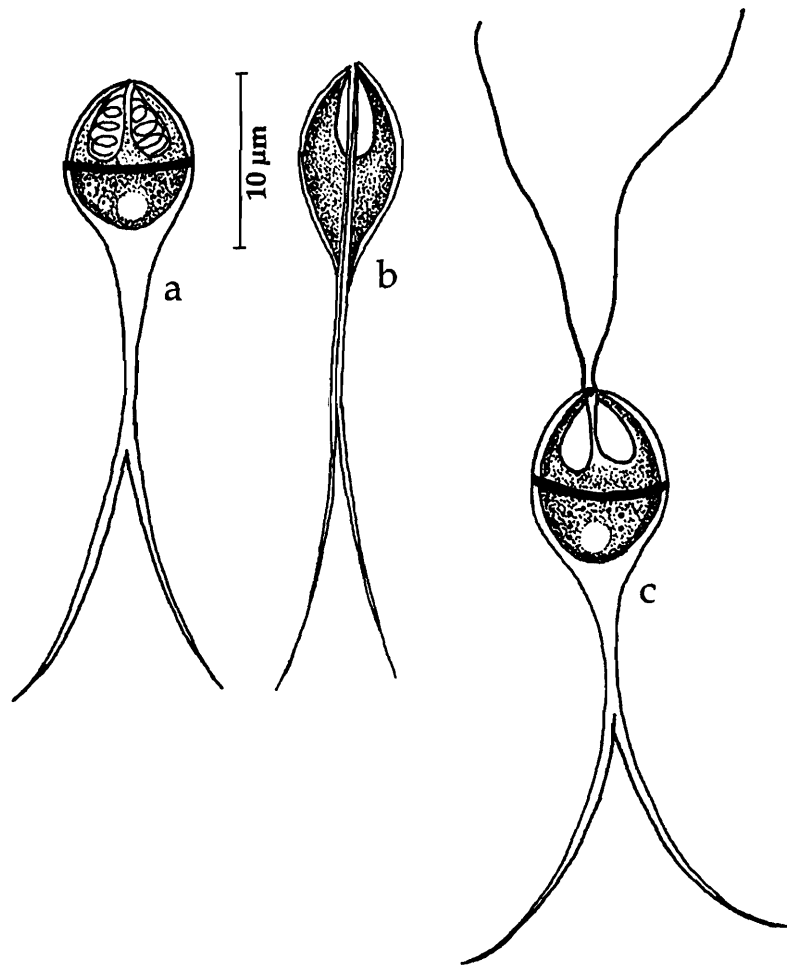


Fig. 218. *Hennaguya otolithi* : a. Fresh spore sutural view, b. Spore valvular view, c. Spore with extruded polar filament

Size : Spore body length 10.0–12.0 μm , width 6.0–8.5 μm ; length of caudal process 35.0–40.0 μm ; polar capsule length 3.0–4.0 μm , width 2.0–2.5 μm ; polar filament length 15–20 μm .

Host : *Otolithus ruber*, *O. maculatus*; **site of infection :** Bulbous arteriosus; **pathogenicity :** Infected heart corroded in appearance. Destruction of the muscle fiber and associated fibroblast infiltration at the site of infection also reported.

Distribution : India ; Tamilnadu (Chennai).

219. *Henneguya quadrii* Lalitha Kumari, 1965
(Fig. 219 a-c)

Diagnosis : Trophozoites round or ovoid; spore elongated or oval; anterior end round; shell valves smooth, prolonged as bifurcated caudal process; sutural ridge broad, prominent; polar capsules 2, unequal, pyriform, one on either side of the sutural line and opening independently through a small duct; polar filament forming 9 coils while inside the capsule, uniformly thin, unequal when extended; sporoplasm binnucleate, finely granular extending only up to the base of the polar capsule, iodophilous vacuole present.

Size : Spore body length 9.24 –12.32 (11.0) μm , width 4.62–5.39 (4.62) μm ; length of caudal process 6.16–14.3 (9.81) μm ; polar capsule (large) length 4.62–6.16 (5.25) μm , width 1.15–1.82 (1.54) μm ; polar capsule (small) length 3.85–4.62 (4.48) μm , width 1.15–1.92 (1.54) μm ; polar filament (long) length 41.85–53.13 (45.4) μm , polar filament (short) 28.0–46.25 (34.54) μm .

Host : *Ophicephalus gachua*; **site of infection** : intestine; **pathogenicity** : not apparent.

Distribution : India : Andhra Pradesh (Hyderabad district).

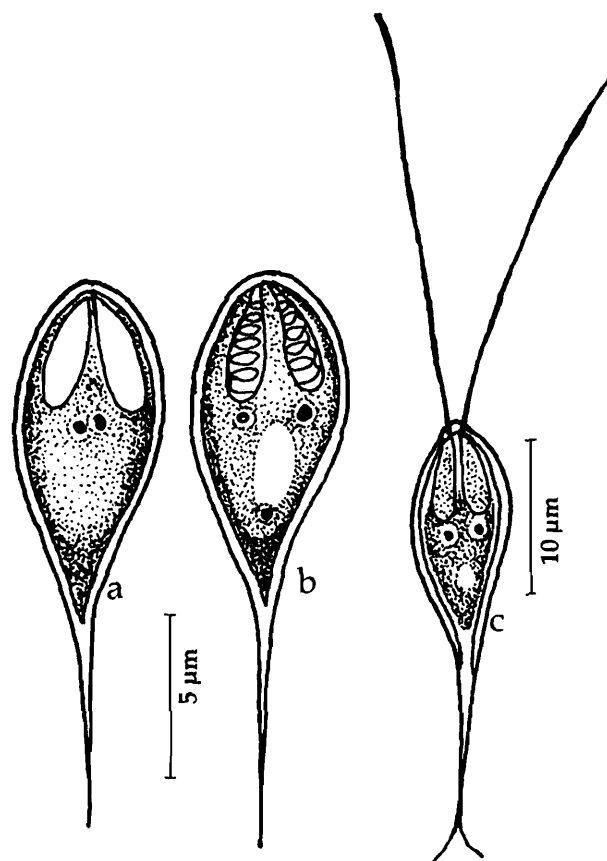


Fig. 219. *Henneguya quadrii* : a. Fresh spore sutural view, b. Spore valvular view, c. Spore with extruded polar filament

220. *Henneguya renalis* Sarkar, Mazumdar and Pramanik, 1985
(Fig. 220 a-c)

Diagnosis : Spore histozoic, hyaline, almost pyriform in sutural view, broadly oval in valvular view; caudal appendage short and fine; shell valve smooth and thin; suture lightly bent and thin; polar capsule two, equal, oval to pyriform with short neck; polar filament forming 3-4 coils while inside the capsule; iodophilous vacuole present.

Size : Spore body length 14.4–19.2 (16.83) μm , width 8.0–11.2 (9.77) μm ; caudal process 4.8–12.8 (7.9) μm ; polar capsule length 4.6–7.6 (5.74) μm , width 2.5–5.06 (4.26) μm .

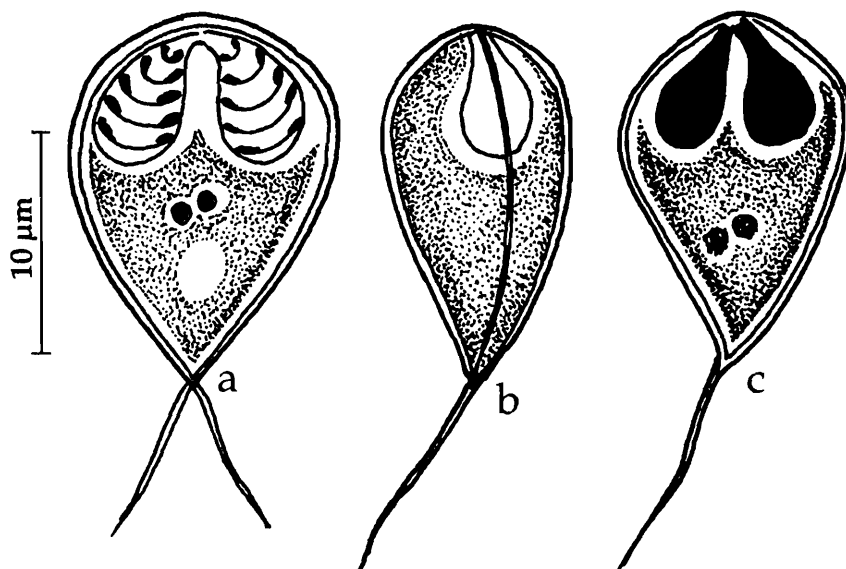


Fig. 220. *Hennaguya renalis* : a. Spore stained with Giemsa, b. Fresh spore sutural view, c. Spore treated with iodine

Host : *Channa marulius* Ham; *site of infection* : kidney; *pathogenicity* : not apparent.

Distribution : India : West Bengal (Murshidabad district).

221. *Hennaguya ritae* (Bajpai and Haldar, 1982)
emend. Gupta and Khera, 1987
(Syn. *Unicauda ritae* Bajpai and Haldar, 1982b)
(Fig. 221 a-b)

Diagnosis : Spore oblongate, anterior end pointed, posterior end prolonged undividedly; sutural line distinct; polar capsule two, pyriform, equal; polar filament making 6 to 7 coils while inside the capsule, extruded filament long and thin; sporoplasm lanceolate, binucleate, almost filling the extracapsular space; iodophilous vacuole present.

Size : Spore total length 39.9-44.8 (42.4) μm , width 5.0-5.8 (5.2) μm ; caudal process length 27.2-31.5 (29.4) μm ; polar capsule length 5.0-5.8 (5.3) μm , width 1.7-2.5 (1.9) μm ; polar filament length 16.7-23.2 μm .

Host : *Rita rita* Ham; *site of infection* : branchial filament; *pathogenicity* : not apparent.

Distribution : India : West Bengal (Hugli district).

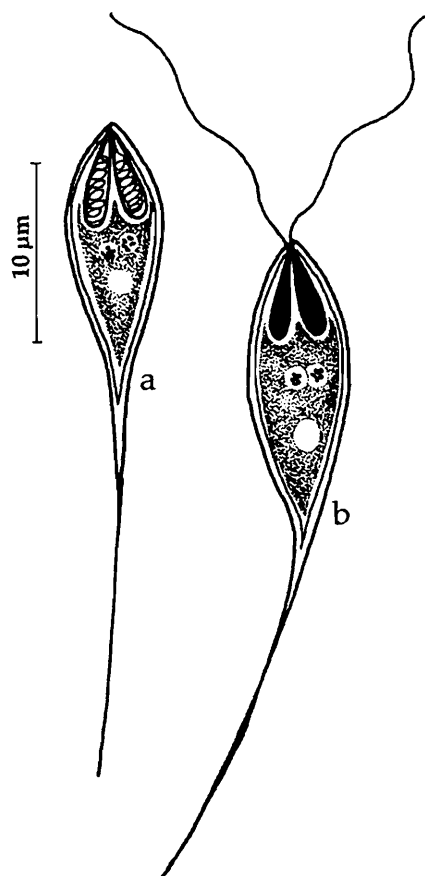


Fig. 221. *Hennaguya ritae* : a. Fresh spore valvular view, b. Spore with extruded polar filament

222. *Henneguya rubicundi* Haldar and Mukherjee, 1985

(Fig. 222 a-b)

Diagnosis : Cyst creamy-yellowish, oval, tumour-like, 2 mm x 1.5 mm; spore body elongate oval in front view; anterior extremity bluntly rounded, posterior extremity narrow and prolonged as the caudal appendage; shell valves smooth, uniform; sutural ridge distinct, straight; sutural line indistinct; polar capsules, two, equal, pyriform with 6-8 coils of polar filament inside; sporoplasm binucleate, almost filling the entire extracapsular space; iodophilous vacuole distinct.

Size : Spore total length 24.4–36.7 (31.2) μm , spore width 3.3–8.1(5.5) μm ; caudal process length 13.3–24.5 (19.7) μm ; polar capsule length 3.3–5.1 (3.7) μm , width 2.2–3.0(2.3) μm .

Host : *Gobioides rubicundus* (Bloch); **site of infection** : dorsal and ventral fins; **pathogenicity** : not apparent.

Distribution : India : West Bengal (Nadia district).

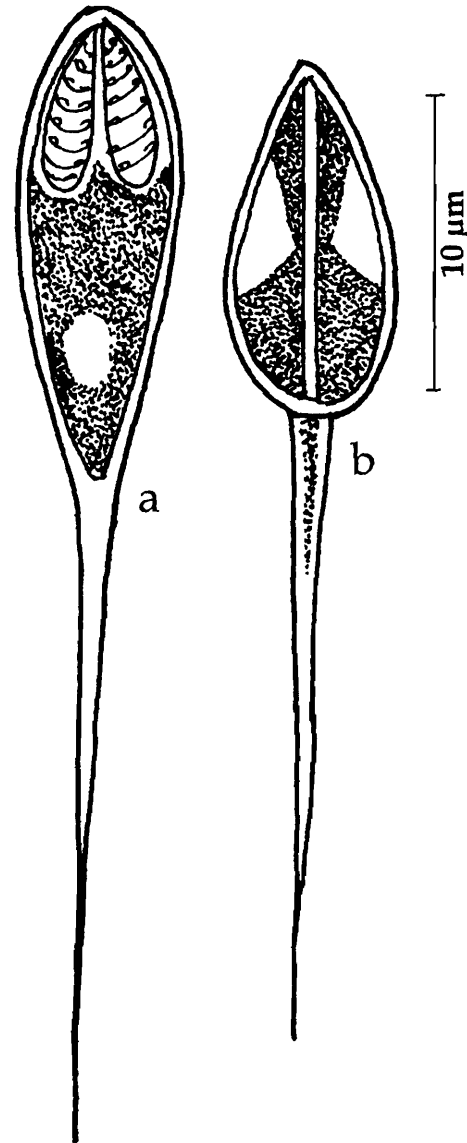


Fig. 222. *Henneguya rubicundi* : a. Fresh spore valvular view, b. Spore sutural view

223. *Henneguya singhi* Lalitha Kumari, 1969

(Fig. 223 a-b)

Diagnosis : Spore body elongate, oval with narrow anterior end; caudal appendage bifurcated into two processes at a distance from the posterior end; spore valves thin, smooth, uniform; sutural ridge not seen; polar capsules 2, unequal, pyriform, terminal, large capsule often curved; polar filaments unequal, forming 4-5 coils within the capsule, thin and long when fully extended; sporoplasm finely granular and homogenous; iodophilous vacuole small.

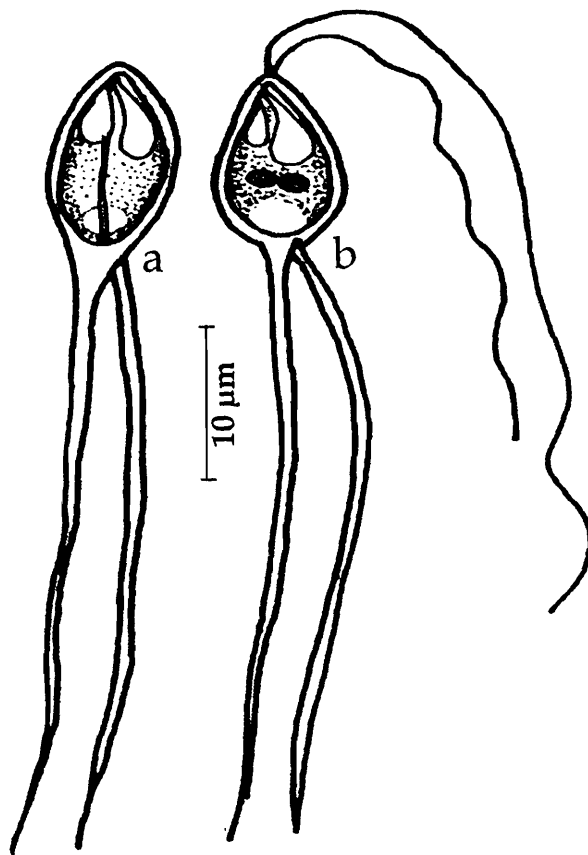


Fig. 223. *Hennaguya singhi* : a. Fresh spore valvular view, b. Spore with extruded polar filament

Size : Spore body length 11.1–13.6 (12.3) μm , width 3.9–5.7 (4.4) μm ; caudal process length 30.0–48.0 (39.0) μm , polar capsule (large) length 4.8–6.4 (5.7) μm , width 0.8–1.4 (1.1) μm ; polar capsule (small) length 3.5–5.5 (4.1) μm , width 1.4–2.0 (1.6) μm ; polar filament length, long 26.0–38.5 (33.5) μm , short 7.0–16.5 (10.1) μm .

Host : *Notopterus osmanii* ;
site of infection : gill filaments;
pathogenicity : not apparent.

Distribution : India : Andhra Pradesh (Hyderabad city).

224. *Hennaguya tachysuri* Menon, 1986
(Fig. 224 a-b)

Diagnosis : Cyst opaque white, round or oval, 1.0 to 3.0 mm in diameter; spore body ovoid in valvular view; anterior end broad, rounded, posterior portion attenuated and continued into two narrow, equal, flexible caudal processes originating from two flap-like structures; valves smooth; sutural ridge straight; polar capsules two, equal, pyriform each with a distinct neck, parallel, situated at the anterior end; polar filament forming 3-5 coils while inside the capsule; sporoplasm homogenous; iodophilous vacuole absent or present in some spores.

Size : Spore length total 47.0 -60.0 μm ; spore body length 12.0-15.0 μm , width 7.0-

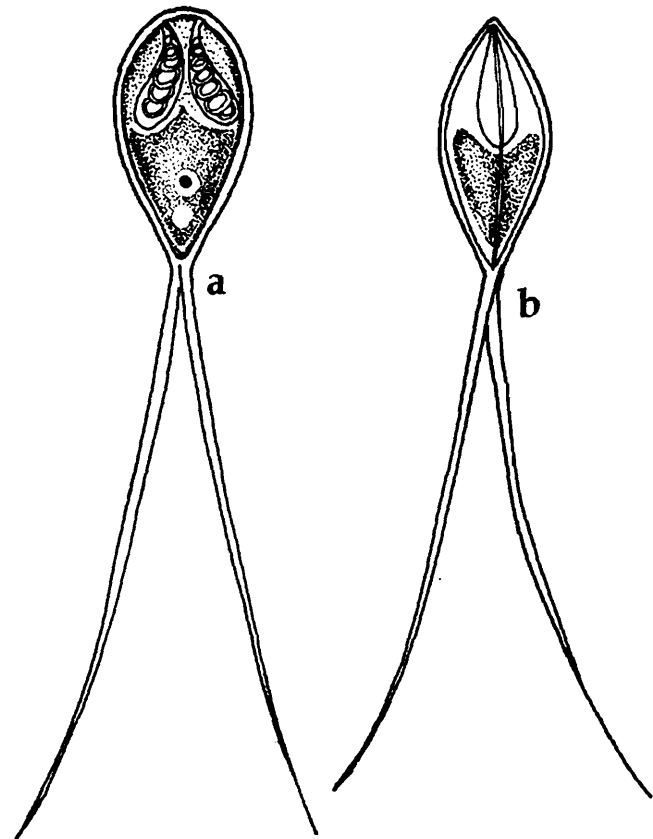


Fig. 224. *Hennaguya tachysuri* : a. Fresh spore valvular view, b. Spore sutural view

8.0 μm , thickness 5.0 -6.0 μm ; length of caudal process 35.0-44.0 μm ; polar capsule length 6.0 – 7.0 μm , width 2.0-3.0 μm .

Host : *Ophicephalus punctatus* (Bloch); *site of infection* : branchial epithelium; *pathogenicity* : not apparent.

Distribution : India : West Bengal (Calcutta district).

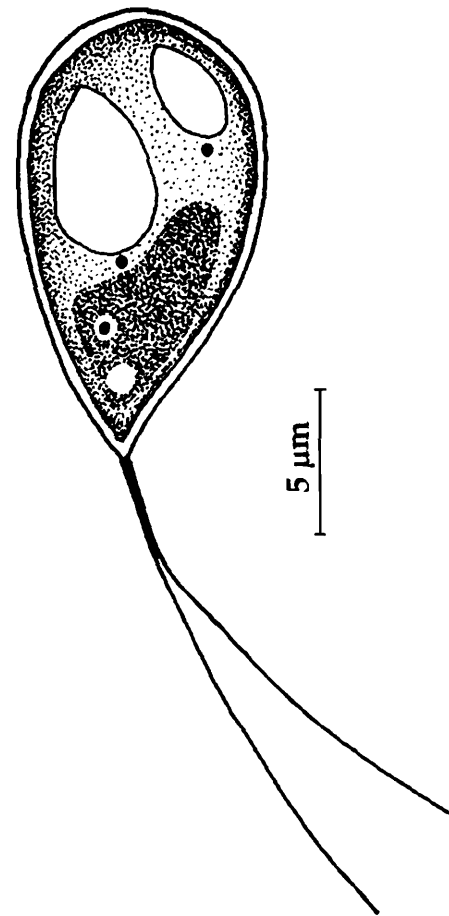
225. *Henneguya thermalis* Seenappa, Manohar and Prabhu 1981
(Fig. 225)

Diagnosis : Spore body pyriform in valvular view; anterior end broad, rounded, posterior portion pointed; caudal processes bifurcated; valves moderately thick, smooth; sutural ridge distinct; polar capsules two, unequal; larger capsule pyriform; smaller capsule ovoid, convergent, opening to a side from the long axis; sporoplasm triangular occupying the entire extracapsular spore cavity; iodophilous vacuole absent or sometimes present.

Size : Spore length total 47.0 -60.0 μm ; spore body length 12.0-13.2 μm , width 6.0-8.0 μm , thickness 5.0 μm ; length of caudal process 11.0-13.0 mm; polar capsule (large) length 4.0–5.0 μm , width 2.0-3.0 μm ; polar capsule (small) length 3.0 – 4.0 μm .

Host : *Lepidocephalichthys thermalis* (Hamilton); *site of infection* : brain tissue; *pathogenicity* : not recorded.

Distribution : India : Karnataka : **Fig. 225.** *Hennaguya theramalis* : a. Fresh spore valvular view
(Honnenahalli, Chitradurga district).



226. *Henneguya waltirensis* Narasimhamurti and Kalavati, 1975
(Fig. 226 a-c)

Diagnosis : Trophozoites translucent, 50 – 120 μm in size, variable in shape; spore oval, compressed along the sutural line; spore valves prolonged as 2 characteristic 'U'-shaped processes; polar capsules 2, equal, pyriform, one on either side of the sutural line, opening independently; polar filament forming 6 –7 coils while inside the capsule; polar filaments uniformly thin when extended; sporoplasm hyaline; iodophilous vacuole seen in fresh material.

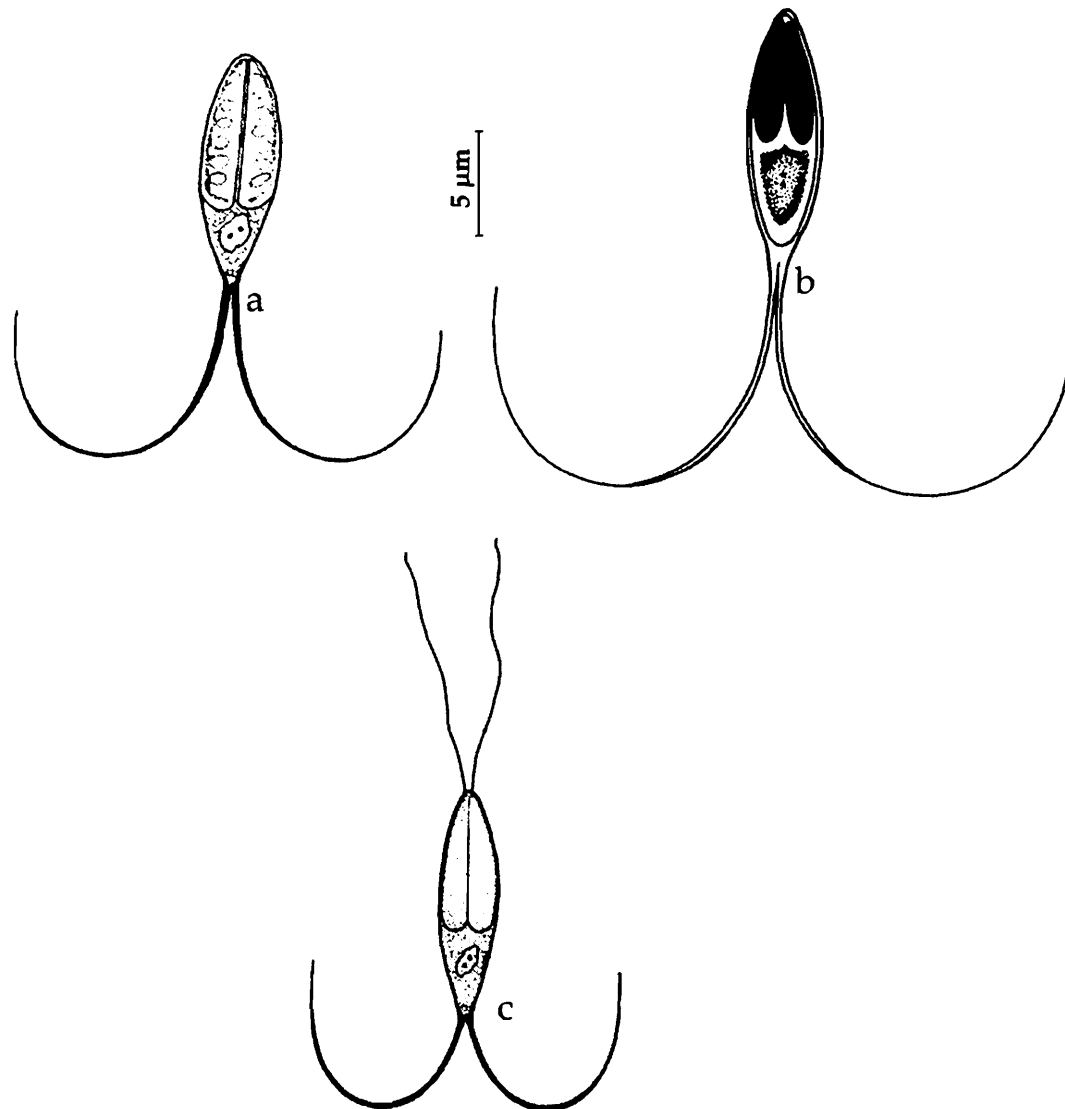


Fig. 226. *Hennaguya waltirens* : a. Spore stained with Giemsa, b. Spore treated with iodine, c. Spore with extruded polar filament

Size : Spore length total 55.0–55.0 µm; spore body length 14.6–15.5 µm, width 3.2–4.0 µm; length of caudal process 40.0–50.0 µm; polar capsule length 10.0–12.0 µm, width 1.6–2.5 µm; polar filament length 15–20 µm.

Host : *Channa (Ophicephalus) punctatus*; **site of infection :** gill filaments; **pathogenicity :** in early stages, parasite induces hypertrophy of the gill epithelium and vacuolization of the cell cytoplasm, degenerative changes associated with accumulation of macrophages and haemorrhage of capillaries evident at the later stages.

Distribution : India : Andhra Pradesh (Anakapalli and Visakhapatnam, Visakhapatnam district. Vizianagaram, Vizianagaram district), Kerala (Veli lake).

Remarks : Krishnakumar (2000) reported this species from Kerala infecting *Channa striatus*. Narasimhamurti and Kalavati, (1984) observed seasonal variations in the prevalence of infection with this parasite. Maximum prevalence was recorded in winter (22.4%) and minimum in summer months.

227. *Henneguya zahoori* Bhatt and Siddiqui, 1964
(Fig. 227)

Diagnosis : Cysts minute, spherical, whitish, opaque, 0.5 mm in diameter; spore body biconvex, compressed parallel to sutural plane, anterior end attenuated, posterior end extended into a bifurcated caudal process; polar capsules 2, equal, pyriform; polar filaments uniformly thin when extended, sporoplasm finely granular, uni or binucleate; iodophilous vacuole present

Size : Spore length total 20.0–30.6 (23.6) μm ; spore body length 8.0–12.0 (9.6) μm , width 2.1–3.0 (2.6) μm ; length of caudal process 12.0–18.6 (13.9) μm ; polar capsule length 4.9–6.7 (5.8) μm , width 0.7–1.1 (0.9) μm .

Host : *Channa (Ophicephalus) punctatus*; **site of infection** : gill filaments; **pathogenicity** : not recorded.

Distribution : India : Uttar Pradesh (Aligarh)

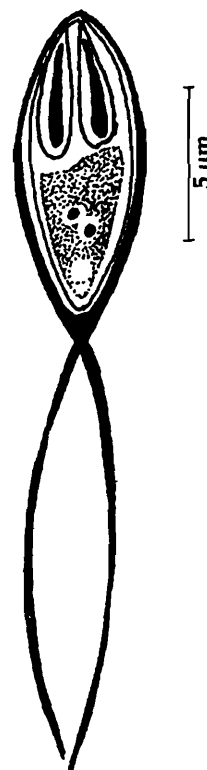


Fig. 227. *Hennaguya zahoori* : spore stained with Giemsa

Genus *Neohenneguya* Tripathi, 1952

Diagnosis : As in the key.

228. *Neohenneguya tetraradiata* Tripathi, 1952
(Fig. 228 a-b)

Diagnosis : Cyst 0.5 mm in diameter; trophozoite irregular in shape; spore fusiform with two long thin prolongation at either end; shell valve thin, smooth and slightly unequal in size; sutural line thin, sutural ridge not distinct; polar capsule spherical, polar filament long and thin; iodophilous vacuole present.

Size : Spore length 16.2–21.6 μm ; width 5.4 μm ; caudal process 63.0–72.0 μm ; polar capsule 2.0–2.7 μm in diameter.

Host : *Odontamblyopus rubicundus* (Ham.); **site of infection** : gills; **pathogenicity** : not recorded.

Distribution : India : West Bengal (Hooghly river).

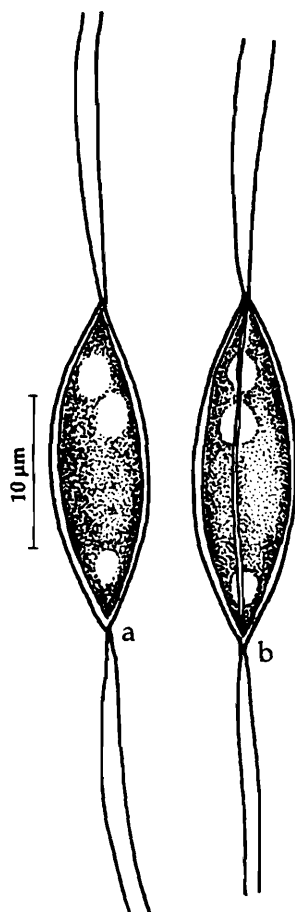


Fig. 228. *Neohennaguya tetraradiata*
: a. Fresh spore valvular view,
b. Spore sutural view

Genus *Thelohanellus* Kudo, 1933

Diagnosis : As in the key.

Key to the species

1. Spore similar in size 3
2. Spore dissimilar, occurring in two distinct size groups simultaneously
..... *T. jiroveci*
- 3.1 Spores oval
 - 3.1.1 Shell valves thin and smooth; polar capsule oval with anterior end drawn into a small duct; spore 9.0-10.8 μm x 7.2 μm *T. calbasui*
 - 3.1.2 Anterior end bluntly pointed and posterior end rounded; valve thick; polar capsule pyriform; spore 19.26-21.40 μm x 10.70-12.48 μm *T. catlae*
 - 3.1.3. Anterior end with a knob-like projection; sides more or less parallel; polar capsule oval; spore 10.8-12.0 μm x 6.3-7.2 μm *T. mrigalae*
 - 3.1.4. Anterior end narrow, flat at the tip, posterior end rounded; valves smooth, with two or three parietal folds at the antero-lateral region; polar capsule large, oval; spore 10.75-12.04 (11.18) μm x 8.6-10.32 (9.46) μm *T. parastromataei*
- 3.2 Spore elongated.
 - 3.2.1. Anterior end thin, truncated, posterior end rounded, slightly flattened; polar capsule pyriform with thin neck; spore 16.2-17.5 μm x 5.4 μm
..... *T. gangeticus*
 - 3.2.2. Anterior end narrow, flat at the tip, posterior end rounded; valves thick, uniform with 4-5 parietal folds; polar capsule broad, oval; one capsule with distinct neck; spore 12.1-16.0 (13.0) μm x 7.9-9.5 (8.2) μm *T. potaili*
 - 3.2.3. Anteriorly spores narrow, elongate, tapering and rounded posteriorly; valve uniform, smooth; polar capsule elongated oval without duct; spore 11.42-12.85 (12.53) μm x 6.42-7.14 (6.91) μm *T. shortii*
 - 3.2.4. Anterior end slightly acuminate and posterior end rounded; valves smooth, thick, polar capsule pyriform; spore 13.0-15.0 (14.05) μm x 5.0-6.5 (5.87) μm
..... *T. sudevi*
- 3.3. Spore egg-shaped/pyriform
 - 3.3.1 Spore egg-shaped, anterior end bluntly pointed, posterior end round; valves thick, smooth; polar capsule flask-shaped with distinct neck; spore 11.0-12.0 μm x 6.0-7.5 μm *T. boggoti*

- 3.3.2. Spore egg-shaped or pyriform; anterior end narrow, flat at the tip, posterior end rounded; valves thin, unequal, with 8–10 striations; polar capsule oval or elongated; spore 9.3–10.3 (9.8) μm x 4.6–6.0 (5.5) μm *T. chelae*
- 3.3.3. Spore egg-shaped; anterior end more pointed than the posterior; valves smooth, thick; polar capsule, broadly ovoidal to almost spherical; spore 12.0–13.0 (12.52) μm x 8.0–8.5 (8.27) μm *T. sanjibi*
- 3.3.4. Spore pyriform, anterior end tapering, extremely blunt, posterior end wide, round; polar capsule pyriform, large, adherent to lateral valves till 3/4th length; spore 11.2–14.5 μm x 4.5–5.5 μm *T. andhrae*
- 3.3.5. Spore pyriform, anterior end pointed and posterior end rounded; valves smooth, curved at the apical region; polar capsule pyriform; spore 14.0–15.75 (14.85) μm x 4.53–7.0(5.35) μm *T. auerbachi*
- 3.3.6. Spores pyriform, anterior end narrow, posterior end round; polar capsule large, pyriform, oblique, shifted to a side; spore 11.4–13.6 (12.3) μm x 4.3–7.9 (6.2) μm *T. batae*
- 3.3.7. Spore pyriform, valves thick, with 3–4 longitudinal striations; polar capsule broadly pyriform; spore 10.0–12.0 (10.95) μm x 5.5–7.5 (6.59) μm
..... *T. bengalensis*
- 3.3.8. Spore pyriform, anterior end tapering, posterior end round, with a bulb like structure demarcated by a notch at the posterior extremity, valves moderately thick, smooth; polar capsule large pyriform with bifurcated anterior tip; spore 30.6–39.98 (34.89) μm x 7.5– 9.99 (9.21) mm..... *T. bifurcata*
- 3.3.9. Spore more or less oval, anterior end pointed, posterior end broad, round; 13.0–14.0 (13.8) μm x 8.5–9.5 (9.0) μm *T. caudatus*
- 3.3.10. Anterior end narrow, flat at the tip; valves thin, smooth; polar capsule flask-shaped; spore elongated, pyriform, 25.8–27.5 (26.7) μm x 7.74–9.46 (8.7) μm *T. chilkensis*
- 3.3.11. Anterior end narrow, posterior end rounded; valves thick, uniform with 4–6 parietal folds; polar capsule pyriform, terminal without a neck; spore 10.7–15.0 (12.4) μm x 4.3–7.1 (5.4) μm *T. chrysopomati*
- 3.3.12. Anterior end with a narrow slightly angled neck, posterior end round and thick; polar capsule pyriform; spore pyriform 12.0–13.5 (12.75) μm x 6.0–8.0 (7.12) μm *T. coeli*
- 3.3.13. Anterior end tapering, posterior end round; valves uniformly thick; polar capsule, pyriform; spore pyriform 12.1–13.2 (12.5) μm x 6.6–7.7 (7.5) μm
..... *T. ophthalmicus*

- 3.3.14. Anterior end narrow, posterior end round, one side flat and the other curved; valves thin, smooth; polar capsule, large, pear-shaped; spore pyriform 14.3–17.1 (14.7) μm x 5.0–6.0 (5.4) μm *T. qadrii*
- 3.3.15. Spore oval, 12.48–14.94 μm x 8.56 μm ; with two polar capsules and a short tail-like process *T. seni*
- 3.3.16. Spore almost pyriform; polar capsule pyriform; 31.0–41.0 μm x 10.0–15.0 μm .
..... *T. rodgi*
- 3.3.17. Anterior end pointed, posterior round; valve thick; polar capsule pyriform; spore elongately pyriform 30–33 μm x 10–13 μm *T. rohita*
- 3.3.18. Anterior end pointed, posterior round; valves smooth, thick; polar capsule pyriform, eccentrically placed; spore pyriform 8.0–11.2 (9.25) μm x 4.0–6.4 (4.85) μm *T. wallagoi*

229. *Thelohanellus andhrae* Qadri, 1962c
(Fig. 229 a-d)

Diagnosis: Spore elongated pyriform, anterior end tapering, extremely blunt, posterior end wide, round; valves thin, smooth with parietal folds at the posterior end;

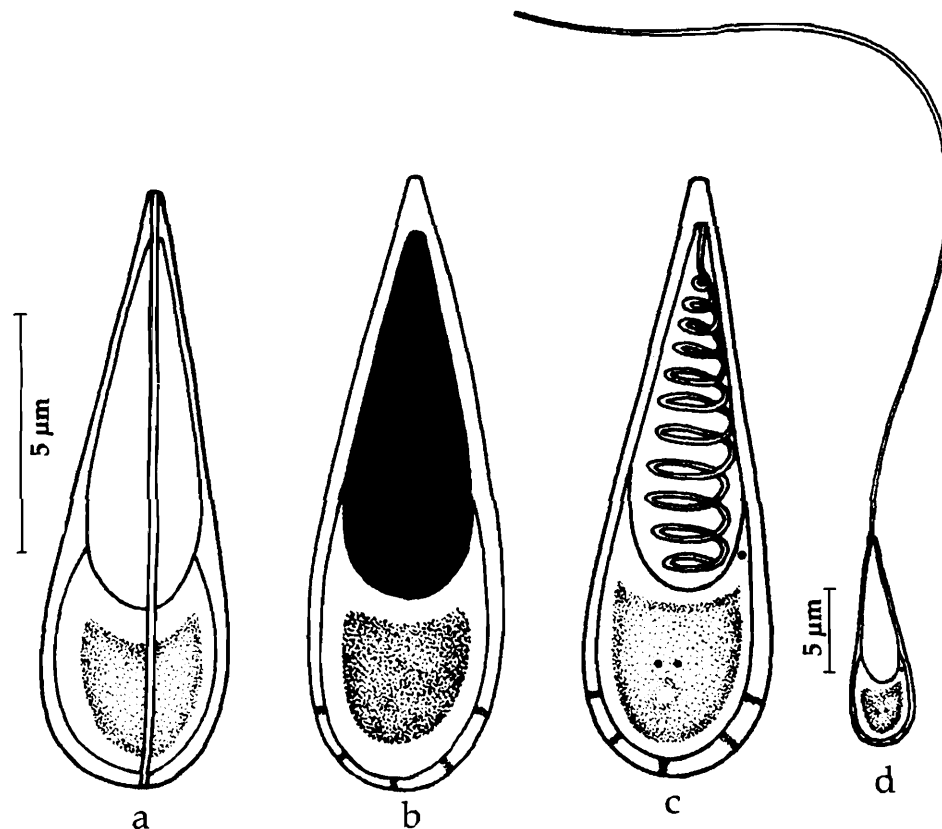


Fig. 229. *Thelohanellus andhrae*: a. Fresh spore, valvular view, b. Spore treated with iodine, c. Spore stained with Giemsa, d. Spore with extruded polar filament

sutural ridge or line not seen; polar capsule single, pyriform, large, adherent to lateral valves till 3/4th length; polar filament making 10-11 coils while inside the capsule; sporoplasm granular, forming a mass in the posterior part of the spore; polysaccharide inclusion spherical.

Size : Spore length 11.2-14.5 μm , width 4.5-5.5 μm ; polar capsule length 6.0-8.0 μm , width 2.0-2.5 μm ; polar filament length 100.0-108 μm .

Host : *Labeo fimbriatus*; **site of infection** : gills; **pathogenicity** : not apparent.

Distribution : India : Andhra Pradesh (Hyderabad city), Kerala : (PuliKuzhi).

Remarks : Krishnakumar (2000) reported this species from Kerala infecting *Puntius vittatus*.

230. *Thelohanellus auerbachii* Sarkar, 1987
(Fig. 230 a-d)

Diagnosis : Spore broadly to elongately pyriform with pointed anterior and rounded posterior ends; shell valve smooth, curved at the apical region; suture indistinct; polar capsule broadly pyriform; polar filament with 5-6 coils while inside the capsule; opening of polar capsule sub terminal; sporoplasm granular, filling the extra capsular spore cavity encircling the capsular region.

Size : Spore length 14.0-15.75 (14.85) μm , width 4.53-7.0 (5.35) μm ; polar capsule length 7.0-8.75 (8.0) μm , width 2.8-4.2 (3.75) μm ; polar filament length 51.0-85.0 μm .

Host : *Tachysurus plastystomus* (Day); **site of infection** : gall bladder; **pathogenicity** : not apparent.

Distribution : India : West Bengal (Medinipur district).

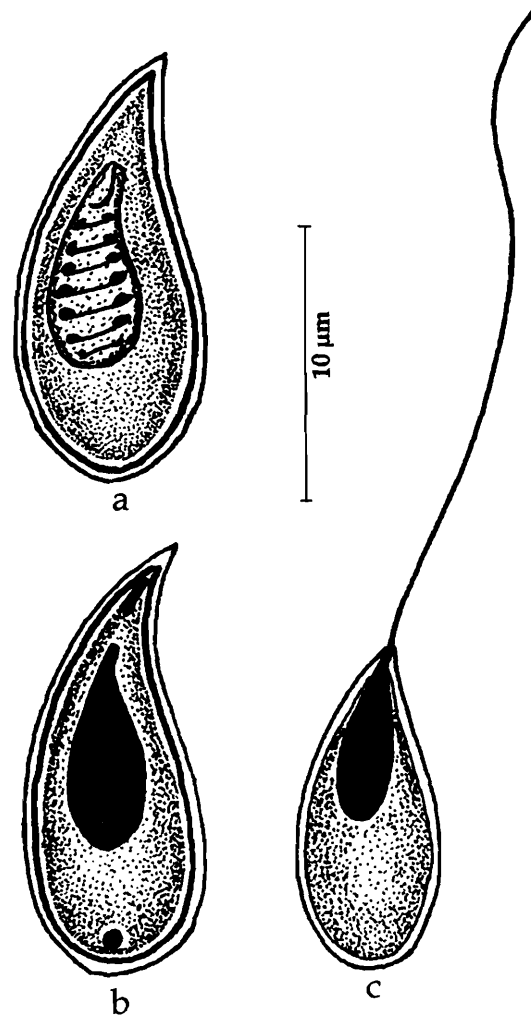


Fig. 230. *Thelohanellus auerbranchii* : a. Spore treated with Giemsa, b. Spore treated with iodine, c. Spore with extruded polar filament

231. *Thelohanellus avijiti* Basu and Haldar, 2003b
(Fig. 231 a-d)

Diagnosis : Plasmodia irregularly round, white, 100–200 μm in diameter; spore histozoic, egg-shaped to ovoidal in valvular view and lenticular in sutural view; anterior end slightly acuminated, posterior end round; valves symmetrical, thick, smooth, sutural line broad, thick, almost straight; spore encircled by a mucous envelop; polar capsule single, large, round to oval; polar filament making 6-8 coils while inside the capsule, very long and thin when extended; sporoplasm homogenous, granular, binucleate; iodophilous vacuole present in the posterior half of the sporoplasm.

Size : Spore length 13.0–14.7 (14.0) μm , width 9.1–10.2 (9.7) μm ; polar capsule length 5.6–6.4 (6.0) μm , width 3.8–4.2 (4.0) μm .

Host : *Labeo rohita*; **site of infection :** dorsal fin; **pathogenicity :** not apparent.

Distribution : India : West Bengal : (Chinsurah, Hugli district).

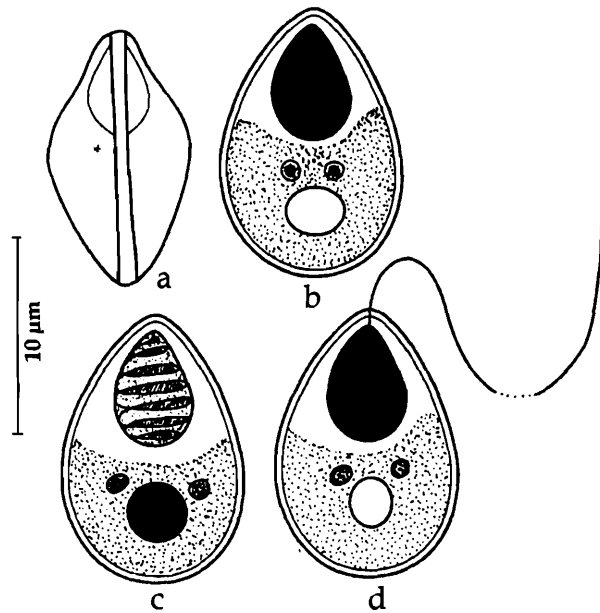


Fig. 231. *Thelohanellus avijiti* : a. Fresh spore valvular view, b. Spore treated with iodine, c. Spore stained with Giemsa, d. Spore with extruded polar filament

232. *Thelohanellus batae* Lalitha Kumari,
1969
(Fig. 232 a-c)

Diagnosis : Spores pyriform, anterior end narrow, posterior end rounded; spore valves thin, smooth and symmetrical; sutural ridge not seen; polar capsule single, large, pyriform, terminal, oblique, shifted to a side; polar filament long, whip-like; sporoplasm finely granular, homogenous, occupying the entire extracapsular space; iodophilous vacuole large, located posteriorly.

Size : Spore length 11.4– 13.6 (12.3) μm , width 4.3–7.9 (6.2) μm ; polar capsule length 6.4–8.6 (7.7) μm , width 2.9–3.6 (3.0) μm ; polar filament length 168–185 (178.3) μm .

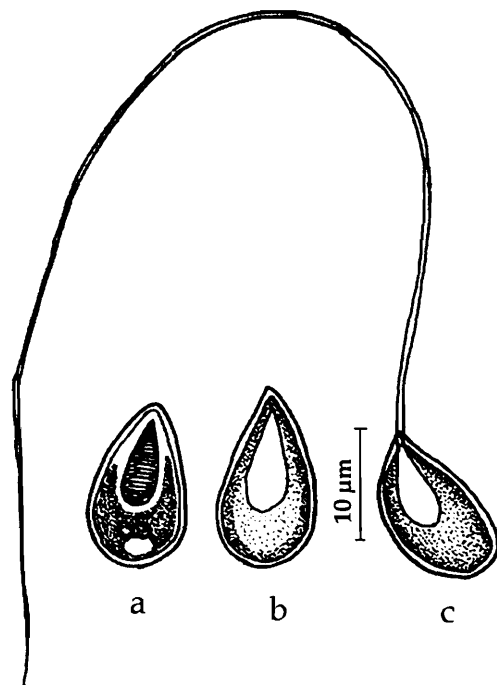


Fig. 232. *Thelohanellus batae* : a. Fresh spore valvular view, b. Spore stained with Giemsa, c. Spore with extruded polar filament

Host : *Labeo bata*; *site of infection* : gill filaments; *pathogenicity* : not apparent.

Distribution : India : Andhra Pradesh (lake near Hyderabad city).

233. *Thelohanellus bengalensis* Sarkar and Raychoudhury, 1986

(Fig. 233 a-b)

Diagnosis : Spore coelzoic, broadly pyriform to cylindroconical in valvular view, almost S-shaped in sutural view; shell valves thick, usually smooth, sometimes having 3-4 longitudinal striations; suture S-shaped and ridged; polar capsule single, broadly pyriform; polar filament forming 3-4 coils while inside the capsule, extruded filament uniformly thin; sporoplasm sickle-shaped mass, binucleate filling the extra capsular cavity ; iodophilous vacuole present.

Size : Spore length 10.0-12.0 (10.95) μm , width 5.5-7.5 (6.59) μm ; polar capsule length 3.75-7.0 (5.42) μm , width 3.0-4.5 (3.47) μm ; polar filament length 52.5 μm .

Host : *Catla catla* Ham; *site of infection* : gall bladder; *pathogenicity* : not apparent.

Distribution : India : West Bengal (Chinsurah, Hugli district).

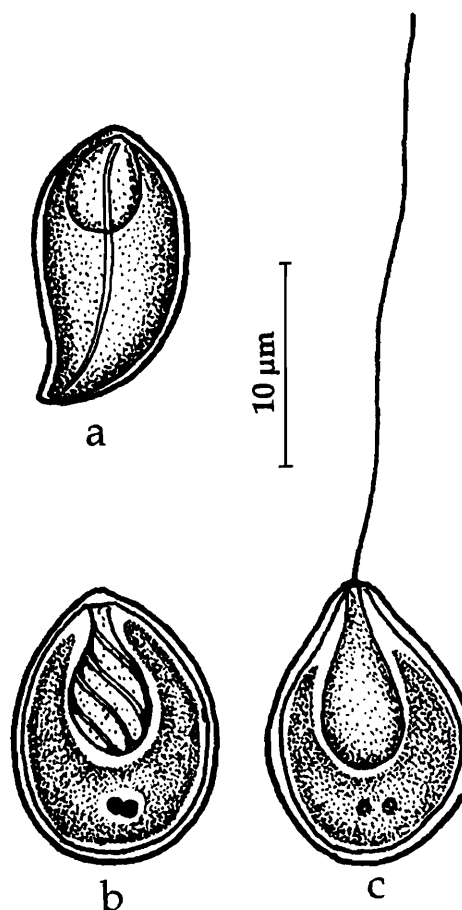


Fig. 233. *Thelohanellus bengalensis* : a. Fresh spore valvular view, b. Spore stained with Giemsa, c. Spore with extruded polar filament

234. *Thelohanellus bifurcata* Basu and Haldar, 1999

(Fig. 234 a-d)

Diagnosis : Cysts bean-shaped, creamy white, 1.3 – 1.4 mm x 0.7 -0.8 mm in size; spore histozoic, pyriform, anterior end tapering, posterior end round, with a bulb-like structure which is demarcated by a notch at the posterior extremity; valves moderately thick, smooth, sutural line distinct; spore encircled by a mucous envelop; polar capsule single, large, pyriform with bifurcated anterior tip; polar filament making 15-20 coils while inside the capsule, very long and thin when extended; sporoplasm homogenous, granular; iodophilous vacuole present.

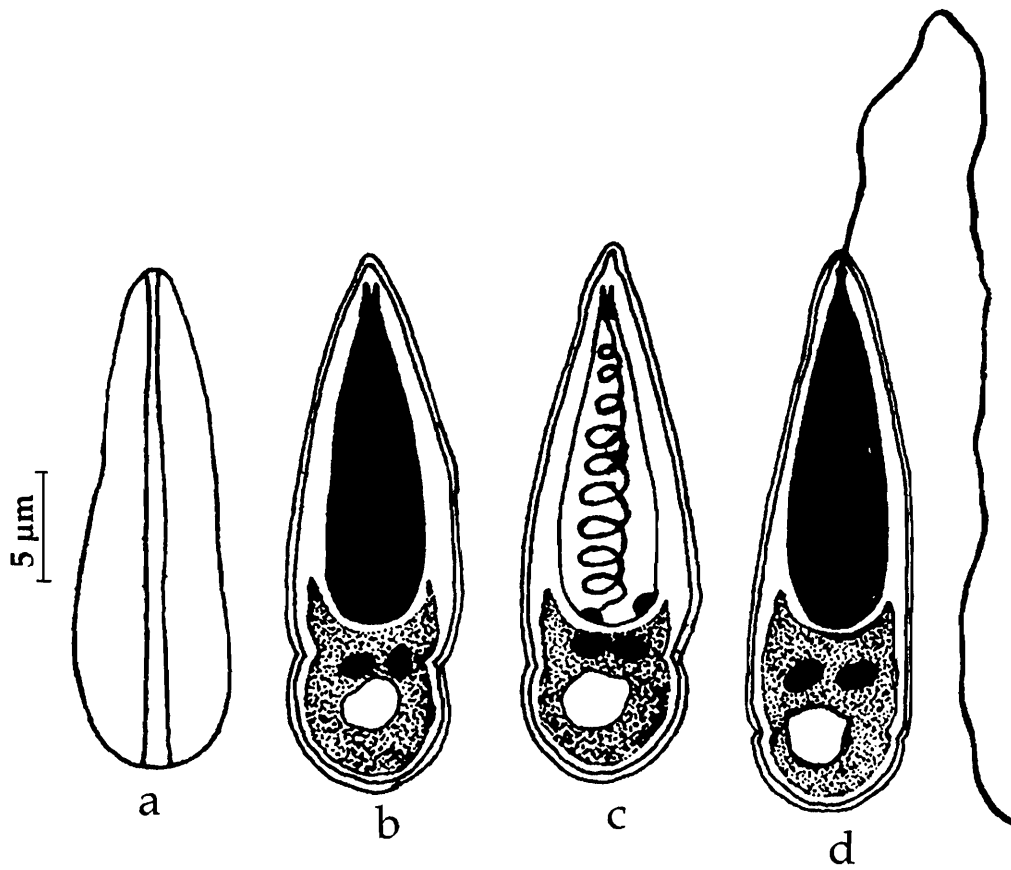


Fig. 234. *Thelohanellus bifurcata* : a. Fresh spore valvular view, b. Spore treated with iodine, c. Spore stained with Giemsa, d. Spore with extruded polar filament

Size : Spore length 30.6-39.98 (34.89) μm , width 7.5-9.99 (9.21) μm ; polar capsule length 20.4-26.72 (23.3) μm , width 6.12-7.52 (6.6) μm ; polar filament length 193.28-362.41 (270.1) μm .

Host : *Labeo rohita*-*Catla catla* hybrid; *site of infection* : gill lamellae; *pathogenicity* : not apparent.

Distribution : India : West Bengal (Ranaghat, Nadia district).

235. *Thelohanellus boggoti* Qadri, 1962d
(Fig. 235 a-c)

Diagnosis : Spore egg-shaped, anterior end bluntly pointed, posterior end round; valves thick, smooth; sutural line curved and wavy in appearance; polar capsule single, flask-shaped with distinct neck; polar filament making 10-11 coils while inside the capsule; sporoplasm finely granular; iodophilous vacuole small and variable in position.

Size : Spore length 11.0-12.0 μm , width 6.0-7.5 μm ; polar capsule length 5.5-7.0 μm , width 3.6-4.0 μm ; polar filament length 52.5 μm .

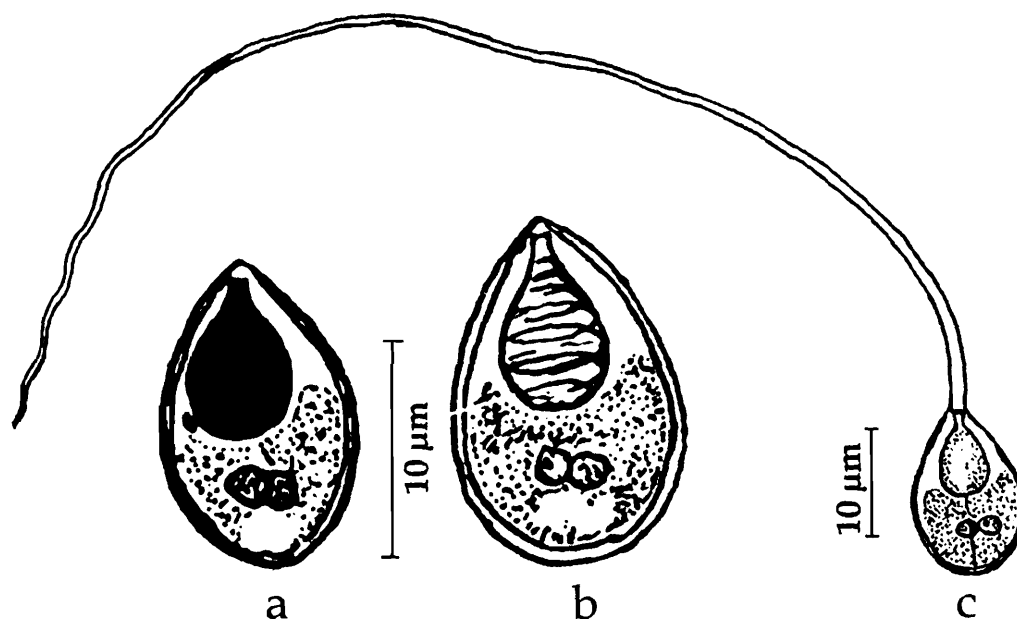


Fig. 235. *Thelohanellus boggoti* : a. Fresh spore valvular view, b. Spore stained with Giemsa, c. Spore with extruded polar filament

Host : *Labeo beggot*; *site of infection* : gills; *pathogenicity* : not apparent.

Distribution : India : Andhra Pradesh (Fish market, Hyderabad city).

236. *Thelohanellus calbasui* Tripathi, 1952
(Fig. 233 a-b)

Diagnosis : Cysts 1.5-2.0 mm in diameter; spore more or less oval, pyriform in side view; valves thin, smooth, equal; sutural line distinct, sutural ridge absent; polar capsule oval with anterior end drawn into a small duct; sporoplasm oval.

Size : Spore length 9.0-10.8 µm, width 7.2 µm; polar capsule length 5.4 µm, width 3.4 µm.

Host : *Labeo calbasu* (Ham.); *site of infection* : scale; *pathogenicity* : not apparent.

Distribution : India : West Bengal (Hugli district).

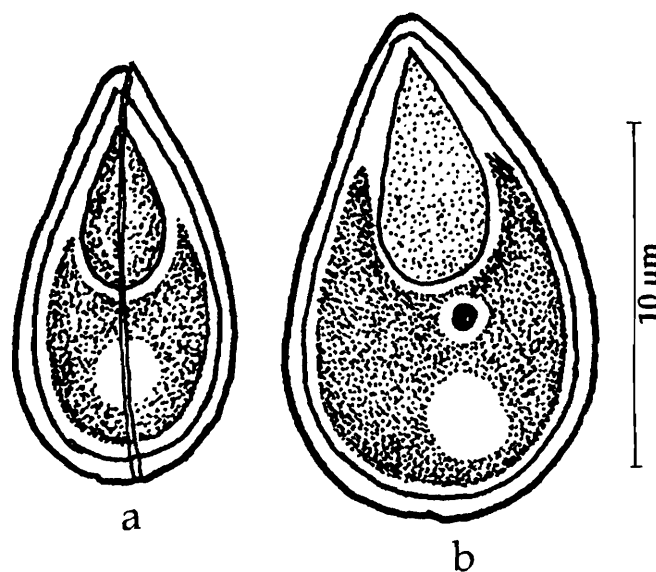


Fig. 236. *Thelohanellus calbasui* : a. Fresh spore sutural view, b. Spore valvular view

237. *Thelohanellus catlae* Chakravarty and Basu, 1948

(Fig. 2347 a-d)

Diagnosis : Cysts oval or circular in outline, 7.5 mm in diameter; spore more or less oval, with anterior end bluntly pointed and posterior end round in valvular view, more or less spindle-shaped in lateral view; shell valve thick; sutural ridge and line prominent; polar capsule pyriform occupying two-third's the length of the spore; polar filament forming 9-10 coils in the capsule, iodophilous vacuole present.

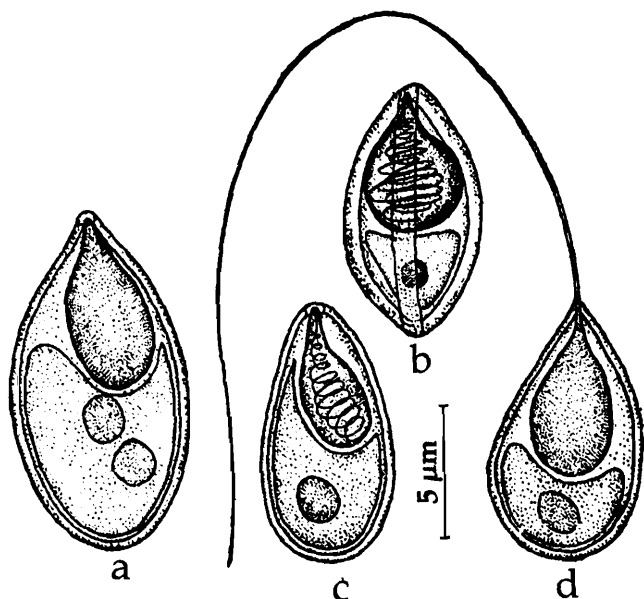


Fig. 237. *Thelohanellus catlae* : a. Fresh spore valvular view, b. Spore sutural view, c. Spore stained with Giemsa, d. Spore with extruded polar filament

Size : Spore length 19.26-21.40 µm, width 10.70-12.48 µm; polar capsule length 10.71-13.90 µm, width 39.63-11.77 µm.

Host : *Catla catla* (Ham.); **site of infection :** branchiae; **pathogenicity :** not apparent.

Distribution : India : West Bengal (North 24-Parganas district).

238. *Thelohanellus caudatus* Pagarkar and Das, 1993
(Fig. 238 a-c)

Diagnosis : Cyst oblongate, white 1.0-3.0 mm; spore more or less oval; anterior end pointed, posterior end broad, round; shell valves uniformly thick; polar capsule pyriform occupying anterior 2/3 of the spore cavity; polar filament making 6-7 coils while inside the capsule; sporoplasm granular, binucleate, nuclei closely placed; iodophilous vacuole spherical in the posterior half of sporoplasm.

Size : Spore length 13.0 – 14.0 (13.8) µm, width 8.5-9.5 (9.0) µm; polar capsule length 7.0-7.5 (7.02) µm, width 5.0-5.5 (5.07) µm.

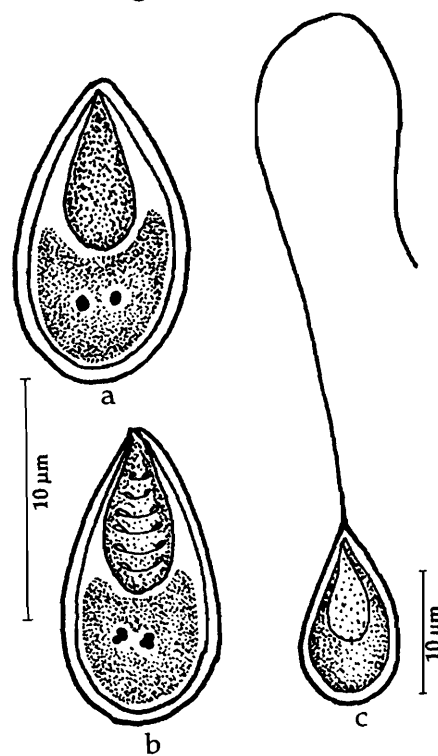


Fig. 238. *Thelohanellus caudatus* : a. Fresh spore valvular view, b. Spore stained with Giemsa, c. Spore with extruded polar filament

Host : *Labeo rohita* (Ham.); *site of infection* : between rays of caudal fin and anal fin; *pathogenicity* : not apparent.

Distribution : India : West Bengal (Sheoraphuli, Hugli district).

239. *Thelohanellus chandannagarensis* Basu and Haldar, 2003b
(Fig. 239 a-c)

Diagnosis : Plasmodia round, white, 200–230 μm in diameter; spore histozoic, pyriform in valvular view and lenticular in sutural view; anterior end bluntly pointed, posterior end round; valves symmetrical, moderately thick, smooth; suture prominent, slightly bent, ridged; polar capsule single, oval, slightly eccentric, anteriorly placed; polar filament making 8-10 coils while inside the capsule, very long and thin when extended; sporoplasm granular, binucleate; iodophilous vacuole present in the posterior half of the sporoplasm

Size : Spore length 11.3 – 13.2 (12.5) μm , width 6.3-7.1 (6.7) μm ; polar capsule length 4.6-5.4 (5.1) μm , width 2.7-3.3 (3.1) μm .

Host : *Catla catla*; *site of infection* : gill filaments; *pathogenicity* : not apparent.

Distribution : India : West Bengal : (Chandannagar, Hugli district).

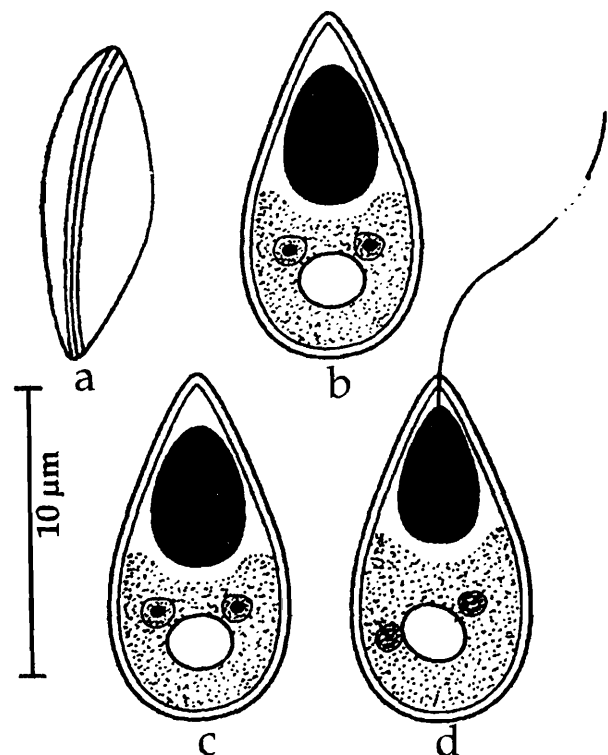


Fig. 239. *Thelohanellus chandannagarensis* : a. Fresh spore sutural view, b & c. Spores valvular view, d. Spore with extruded polar filament

240. *Thelohanellus chelae* Lalitha Kumari, 1969
(Fig. 240 a-b)

Diagnosis : Spores egg-shaped or pyriform, anterior end narrow, flat at the tip, posterior end round; valves thin, uniform, unequal, with 8 – 10 striations parallel to sutural line, converging near the ends; sutural ridge and sutural line clear, shifted to a side; polar capsule 1, oval or elongated, terminal with small neck; polar filament long; sporoplasm finely granular, homogenous occupying the space beneath the capsules; polysaccharide inclusion large, located centrally.

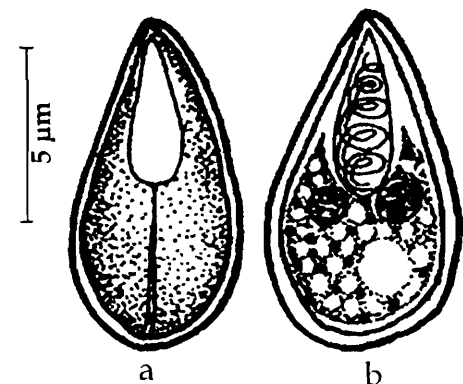


Fig. 240. *Thelohanellus chelae* : a. Fresh spore valvular view, b. Spore stained with Giemsa

Size : Spore length 9.3–10.3 (9.8) μm , width 4.6–6.0 (5.5) μm ; polar capsule length 4.0–5.7 (4.9) μm , width 2.5–3.0 (2.8) μm ; polar filament length 41.0–45.0 (43.0) μm .

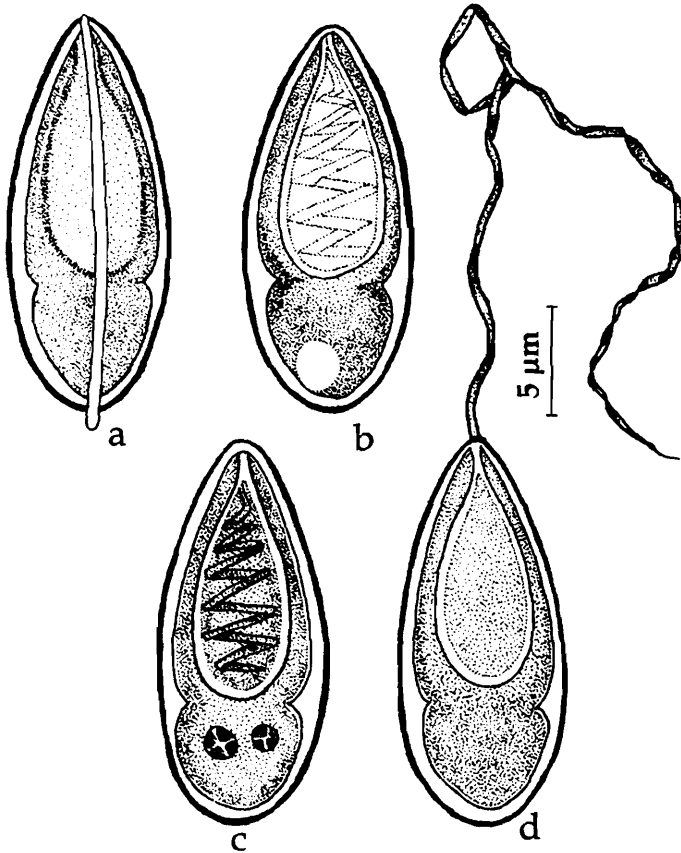
Host : *Chela bacaila*; *site of infection* : gall bladder; *pathogenicity* : not apparent.

Distribution : India : Andhra Pradesh : (Hyderabad city).

241. *Thelohanellus chilkinsis* Kalavati and Vaidehi, 1991a

(Fig. 241 a-d)

Diagnosis : Trophozoites large oval, milky white 2.0–5.0 mm x 0.5–1.0 mm; spores elongate pyriform, anterior end narrow, flat at the tip, posterior end rounded; valves thin, smooth, inner wall of the spore with a distinct constriction at posterior 1/3rd,



formed by 2 indentations on either side; sutural ridge straight extending like a spine at the posterior end; polar capsule 1, flask-shaped, subterminal with small neck, opening 2–3 μm below the anterior tip; polar filament appearing folded while inside the capsule, long, ribbon-like when extended; sporoplasm binucleate, finely granular, homogenous occupying the entire extracapsular area; polysaccharide inclusion large, located centrally.

Size : Spore length 25.8–27.5 (26.7) μm , width 7.74– 9.46 (8.7) μm ; polar capsule length 15.5–19.0 (17.54) μm , width 6.02–7.74 (7.01) μm ; polar filament length 90.0–100.0 (98.0) μm .

Host : *Labeo rohita*; *site of infection* : gall bladder; *pathogenicity* : not apparent.

Distribution : India : Orissa (Chilka Lake).

Fig. 241. *Thelohanellus chilkinsis* : a. Fresh spore sutural view, b. Spore valvular view, c. Spore stained with Giemsa

242. *Thelohanellus chrysopomati* Lalitha Kumari, 1969
(Fig. 242 a-c)

Diagnosis : Spores pyriform, anterior end narrow, posterior end rounded; valves thick, uniform with 4–6 parietal folds in the posterior region; sutural ridge prominent and extending beyond the valvular periphery; polar capsule single, pyriform, terminal without a neck; polar filament forming 9–10 spring-like coils while inside the capsule, long, whip-like, when fully extended; sporoplasm finely granular and homogenous; iodophilous vacuole present.

Size : Spore length 10.7–15.0 (12.4) μm , width 4.3–7.1 (5.4) μm ; polar capsule length 5.7–9.0 (6.5) μm , width 2.1–3.8 (2.7) μm ; polar filament length 79–102 (104.1) μm .

Host : *Barbus chrysopoma*; **site of infection** : Gill contents; **pathogenicity** : not apparent.

Distribution : India : Andhra Pradesh : (Hyderabad city).

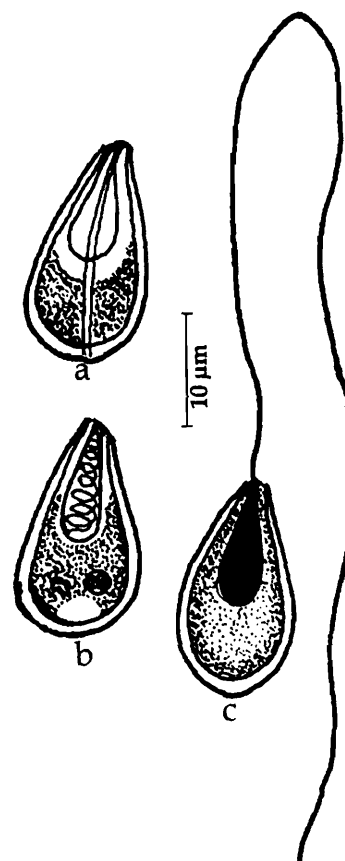


Fig. 242. *Thelohanellus chrysopomati* : a. Fresh spore valvular view, b. Spore stained with Giemsa, c. Spore with extruded polar filament

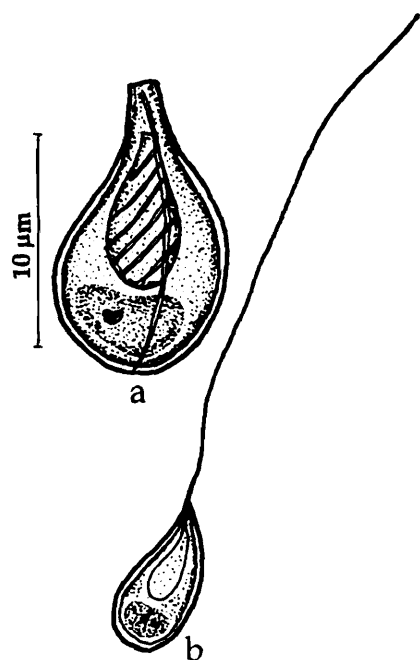


Fig. 243. *Thelohanellus coeli* : a. Spore stained with Giemsa, b. Spore with extruded polar filament

243. *Thelohanellus coeli* Sarkar and Mazumder, 1983a
(Fig. 243 a-b)

Diagnosis : Spores pyriform, thick-walled, posterior end round, anterior end with a narrow slightly angled neck, upper surface with a median longitudinal ridge, polar capsule single, pyriform, situated at the centre and having 6–8 coils of polar filaments.

Size : Spore length 12.0–13.5 (12.75) μm , width 6.0–8.0 (7.12) μm ; polar capsule length 6.0–8.0 (7.13) μm , width 3.0–3.8 (3.2) μm ; polar filament length 50.0 μm .

Host : *Tachysurus tenuispinis* (Day); **site of infection** : gall bladder; **pathogenicity** : not apparent.

Distribution : India : West Bengal (Bay of Bengal).

244. *Thelohanellus endodermitus*
Mukhopadhyay and Haldar, 2004
(Fig. 244 a-d)

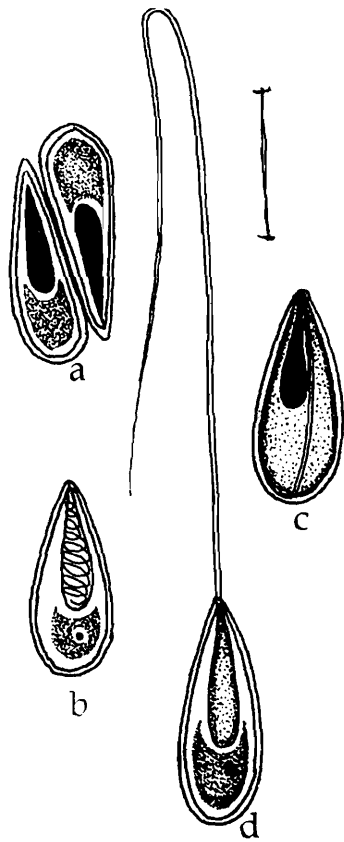


Fig. 244. *Thelohanellus endodermitus* : a. Disporous pansporoblast, b. Spore stained with Giemsa, c. Fresh spore valvular view, d. Spore with extruded polar filament

Diagnosis : Plasmodia oblong, smoky white, 1.0–1.8 mm x 0.9 mm in size; spore transparent, pyriform, anterior end narrow sharply pointed, posterior end broad, round; polar capsule single, pyriform, situated at the anterior tip; polar filament making 8-12 coils while inside the capsule, very long and thin when extended; sporoplasm finely granular, crescentic, binucleate; iodophilous vacuole absent.

Size : Spore length 12.24 –15.3 (13.66) μm , width 4.59-6.12 (5.35) μm ; polar capsule length 6.12–8.16 (7.14) μm , width 2.55-3.06 (3.0) μm ; polar filament length 71.4-159.12 (132.14) μm .

Host : *Labeo rohita*; **site of infection** : under surface of scales; **pathogenicity** : not apparent.

Distribution : India : West Bengal : (Kalyani, Nadia district).

245. *Thelohanellus gangeticus* Tripathi, 1952
(Fig. 245 a-d)

Diagnosis : Spore elongated, thin; anterior end truncated, posterior end slightly flattened with rounded ends in valvular view, pyriform in side view; sutural ridge present, sutural line indistinct; polar capsule pyriform with thin neck; sporoplasm filling nearly half of the extra-capsular cavity; iodophilous vacuole small.

Size : Spore length 16.2-17.5 μm , width 5.4 μm ; polar capsule length 7.2 μm , width 2.5 μm .

Host : *Chela bacaila* (Ham.); **site of infection** : muscles; **pathogenicity** : not apparent.

Distribution : India : West Bengal (North 24-Parganas district), Kerala (Pulikuzhi).

Remarks : Krishnakumar (2000) reported this species from Kerala infecting the brain tissue of *Puntius vittatus*.

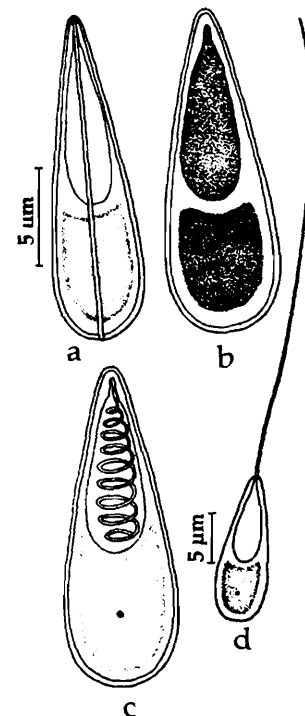


Fig. 245. *Thelohanellus gangeticus* : a. Fresh spore valvular view, b. Spore treated with iodine, c. Spore stained with Giemsa, d. Spore with extruded polar filament

246. *Thelohanellus jiroveci* Kundu and Haldar, 1981
(Fig. 246 a-g)

Diagnosis : Cyst large, oval, creamy-white, 1.5-2.0 mm x 0.5 mm; spores two types, macrospores and microspores occurring simultaneously within the single cyst; macrospores pyriform in valvular view, spindle-shaped in lateral view, anterior end gradually pointed, posterior end round; valves moderately thick; sutural line distinct; polar capsule single, pyriform, with 10-12 coils of polar filament inside, extruded filament exceedingly long; sporoplasm crescentic, binucleate; iodophilous vacuole large, more or less round; microspores slightly lenticular in sutural view, smaller in size, sutural line faintly marked.

Size : Macrospore : spore length 31.0-36.1 (35.0) μm , width 11.1-13.8 (13.0) μm ; polar capsule length 15.5-19.9 (18.4) μm , width 5.5-7.7 (7.0) μm ; polar filament length 194.2-222.0 (214.8) μm

Microspore : Spore length 15.5-17.7 (16.3) μm , width 6.1-8.3 (6.8) μm ; polar capsule length 7.2-7.7 (7.3) μm , width 3.8 - 4.4 (4.1) μm ; polar filament length 66.6-77.7 (74.1) μm .

Host : *Labeo bata* (Ham.);
site of infection : branchiae;
pathogenicity : not apparent.

Distribution : India : West Bengal (Nadia district).

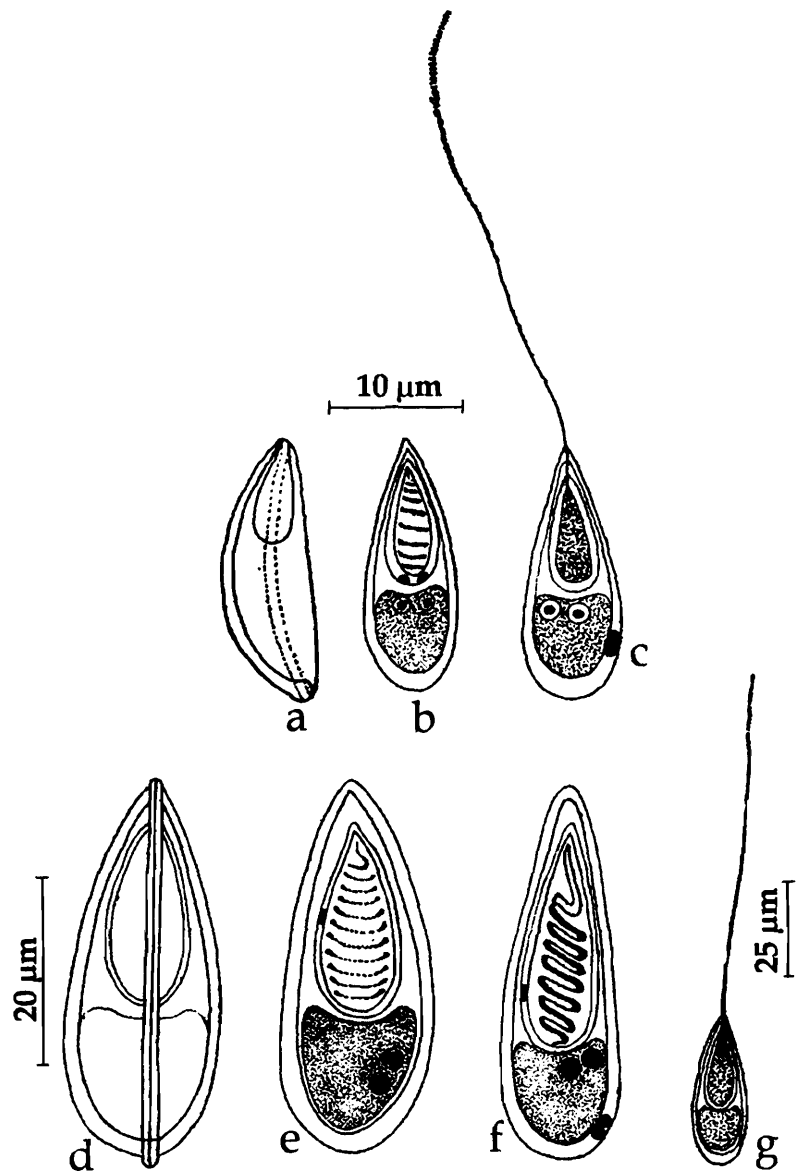


Fig. 246. *Thelohanellus jiroveci* : a-c. Microspores, d. Macrospores

247. *Thelohanellus mrigalae* Tripathi, 1952

(Fig. 247 a-b)

Diagnosis : Cyst 0.75 mm in diameter; spore oval in front view, pyriform in sutural view; lateral sides more or less parallel, with a slight knob-like projection at the anterior end; shell valve thick symmetrical, smooth, sutural line prominent; polar capsule single, oval, occupying nearly half of the spore cavity; sporoplasm filling nearly the whole of the extra capsular cavity; iodophilous vacuole present.

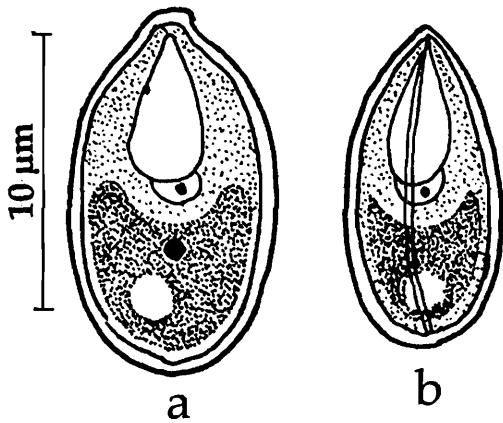


Fig. 247. *Thelohanellus mrigalae*
: a. Fresh spore sutural view,
b. Spore valvular view

Size : Spore length 10.8-12.0 μm ; width 6.3-7.2 μm ; polar capsule length 5.4-7.2 μm ; width 3.6-5.0 μm .

Host : *Cirrhinus mrigala* (Ham.); **site of infection** : skin on the head; **pathogenicity** : not apparent.

Distribution : India : West Bengal (exact locality not mentioned).

248. *Thelohanellus narasimhamurtius* Sarkar, 1994

(Fig. 248 a-c)

Diagnosis : Cysts very small round or ellipsoid 48 μm x 100 μm ; spores narrow, elongately pyriform, anterior end blunt, posterior end rounded; shell valves asymmetrical, one side flat, the other convex, moderately thick; sutural thin, bent in the middle; polar capsule single, lanceolate occupying 2/3 rd of the spore cavity; polar filament forming many fine closely set coils; sporoplasm hemispherical, binucleate; iodophilous vacuole small, spherical.

Size : Spore length 9.0-10.0 (9.65) μm , width 2.3-3.5 (3.3) μm ; polar capsule length 6.0-7.0 (6.58) μm , width 2.0-2.5 (2.2) μm .

Host : *Amblypharyngodon mola* (Ham.); **site of infection** : inter lamellae of gill filaments; **pathogenicity** : necrosis of the interlamellar tissue noticed.

Distribution : India : West Bengal (Villeges of Hugli district).

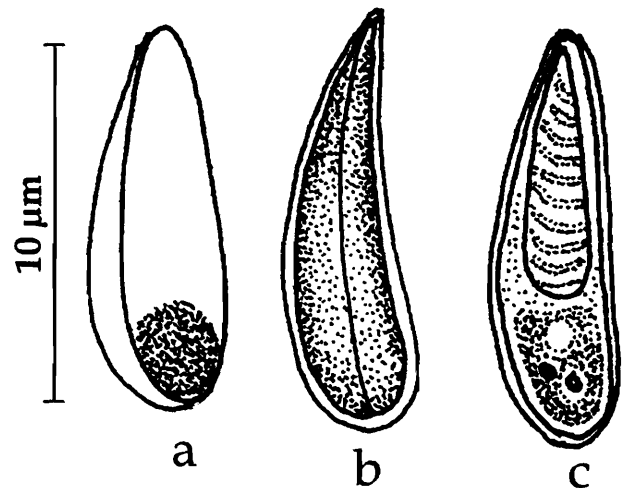


Fig. 248. *Thelohanellus narasimhamurtius* : a. Fresh spore valvular view, b. Spore sutural view, c. Spore stained with Giemsa

249. *Thelohanellus ophthalmicus* Haldar, Das and Sharma, 1983

(Fig. 249 a-d)

Diagnosis : Cyst rounded, white-coloured, 310-390 μm in diameter; spores pyriform, anterior end tapering, posterior end rounded; shell valve symmetrical, uniformly thick; sutural ridge prominent; polar capsule single, pyriform with 6-7 coils of polar filament; sporoplasm cup-shaped; iodophilous vacuole spherical.

Size : Spore length 12.1-13.2 (12.5) μm , width 6.6-7.7 (7.5) μm ; polar capsule length 5.5-6.6 (6.5) μm , width 2.8-3.3 (3.2) μm ; polar filament length 27.5-50.6 μm

Host : *Catla catla* (Ham.); **site of infection** : internal musculature and sclera of eye; **pathogenicity** : not apparent.

Distribution : India : West Bengal (Nadia district); Kerala : (Veli Lake, Poonthura backwaters).

Remarks : Krishnakumar (2000) reported this species from Kerala infecting *Glossogobius giuris*.

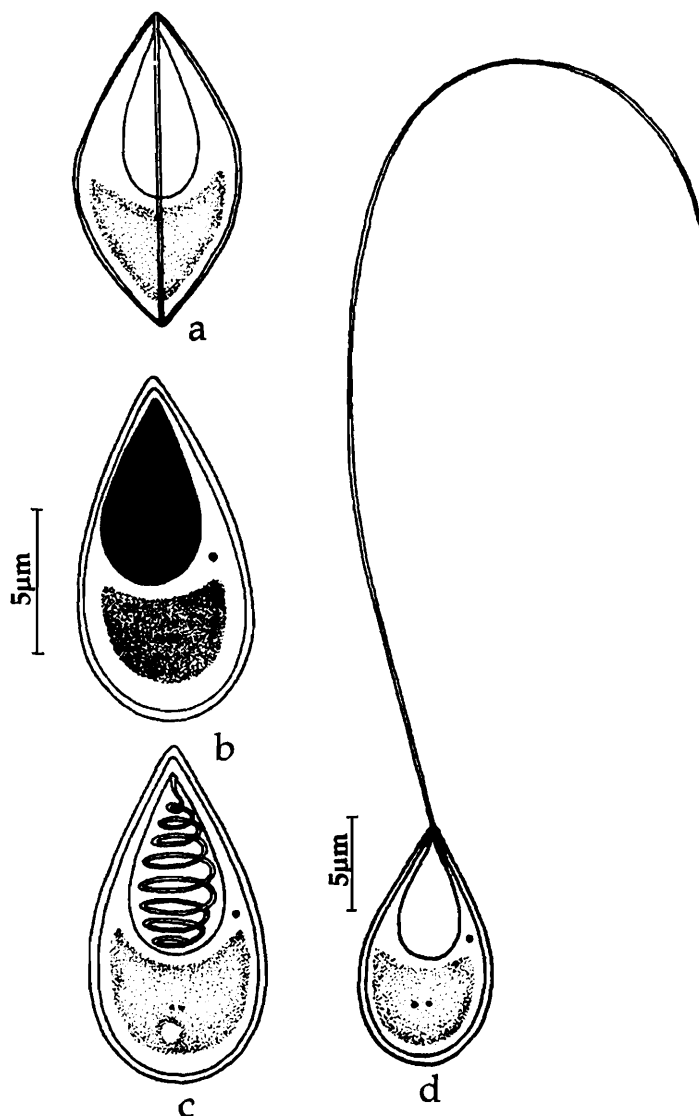


Fig. 249. *Thelohanellus ophthalmicus* : a. Fresh spore valvular view, b. Spore treated with iodine, c. Spore stained with Giemsa, c. Spore with extruded polar filament

250. *Thelohanellus orissae* Haldar, Samal, and Mukhopadhyay, 1997

(Fig. 250 a-e)

Diagnosis : Spores exist in two distinct types; macrospore pyriform, anterior end tapering, posterior end round; shell valve thick; sutural line prominent; polar capsule single, pyriform; polar filament exceedingly long and uniform when extruded; sporoplasm granular, crescentic; iodophilous vacuole spherical; microspores similar in structure, smaller in size

Size : Macrospores length 11.4-16.3 (13.85) μm , width 3.2-6.5 (4.8) μm ; polar capsule length 4.0-8.1 (6.34) μm , width 1.6-3.2 (2.36) μm ; polar filament length 40.7-

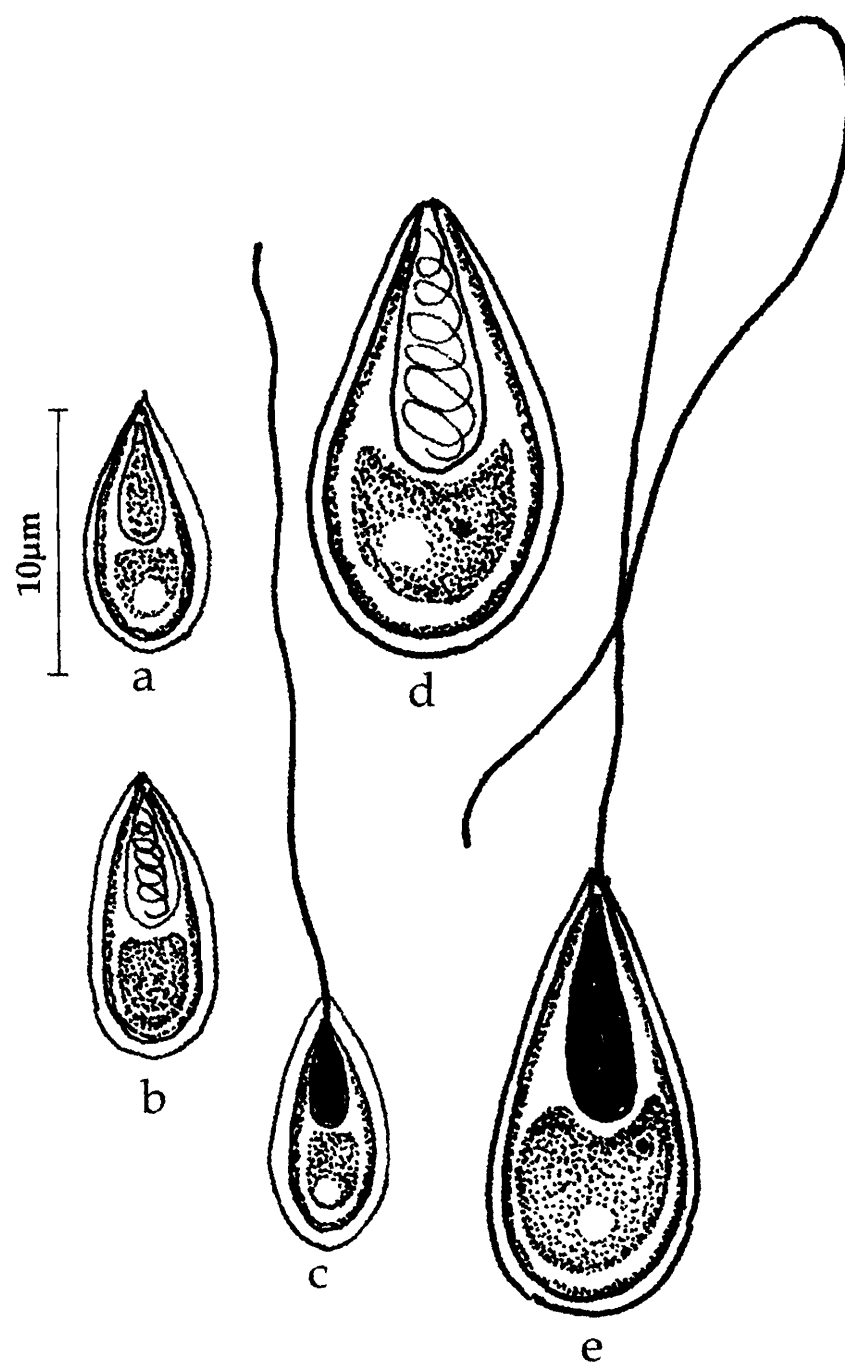


Fig. 250. *Thelohanellus orissae* : a-c. microspore, d-e. Microspore

155.0 (92.44) µm; microspores length 6.0 -9.0 (7.29) µm, width 2.5-4.5 (3.11) µm; polar capsule length 3.0-4.6 (3.72) µm, width 1.0-3.2 (2.32) µm; polar filament length 42.0-63.0 (54.72) µm.

Host : *Cirrhinus mrigala* (Ham.); *site of infection* : gills; *pathogenicity* : not apparent.

Distribution : India : Orissa (Jobra dam, Mahanadi).

251. *Thelohanellus parastromataei* Narasimhamurti, Kalavati,
Anuradha and Padma Dorothy, 1990
(Fig. 251 a-c)

Diagnosis : Coelozoic; spores oval or pyriform, anterior end narrow, flat at the tip, posterior end round; shell valves smooth, with two or three parietal folds at the antero-lateral region; sutural line thin, straight, beaded in appearance; polar capsule single, large, oval, occupying almost the entire spore cavity; polar filament showing characteristic double rows of coiling; sporoplasm finely granular, homogenous, occupying the entire extracapsular space; iodophilous vacuole elongate displaced to a side.

Size : Spore length 10.75-12.04 (11.18) μm , width 8.6-10.32 (9.46) μm ; polar capsule length 7.74-9.03 (8.6) μm , width 6.45-7.31 (6.88) μm ; polar filament length 78.26-85.41 (81.7) μm .

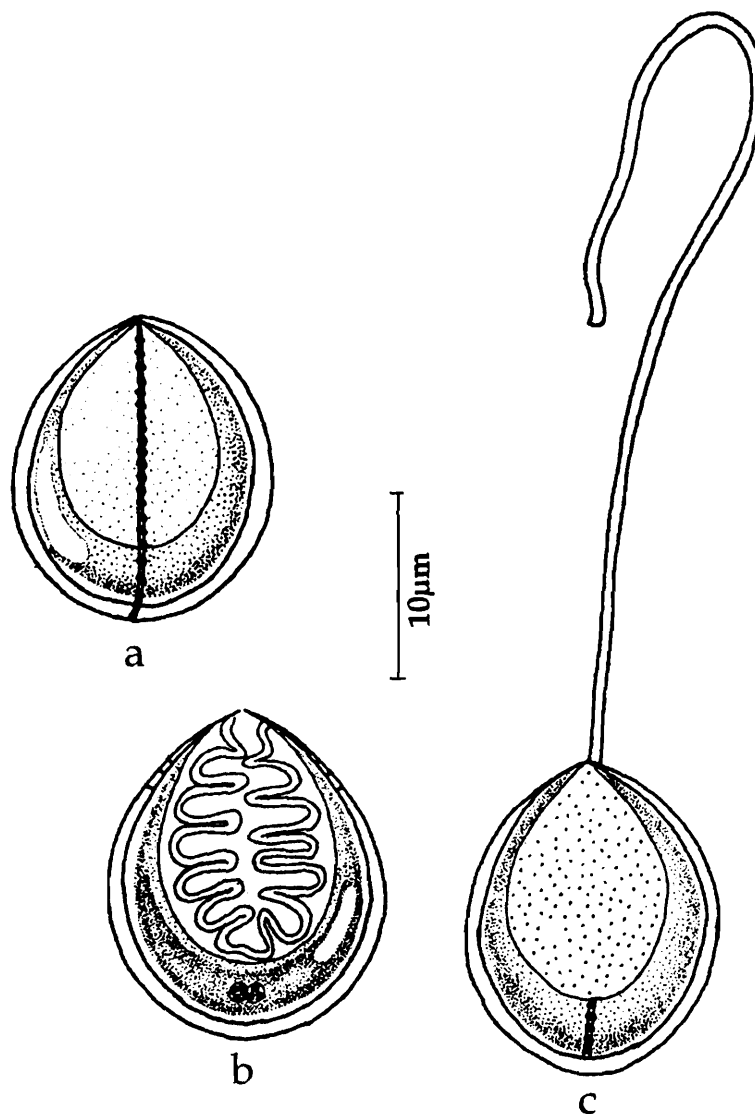


Fig. 251. *Thelohanellus parastromataei* : a. Fresh spore valvular view, b. Spore stained with Giemsa, c. Spore with extruded polar filament

Host : *Parastromataeus niger*; *site of infection* : gall bladder; *pathogenicity* : not apparent.

Distribution : India : Orissa coast (Bay of Bengal).

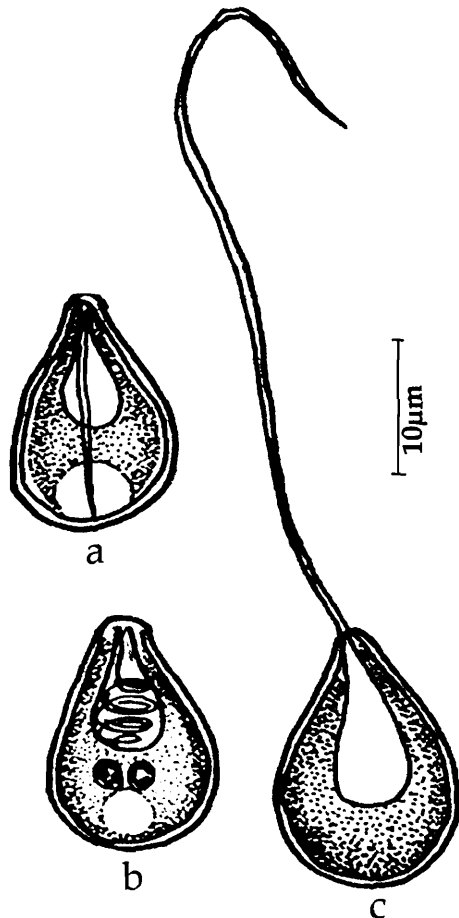


Fig. 252. *Thelohanellus potaili* : a. Fresh spore valvular view, b. Spore stained with Giemsa, c. Spore with extruded polar filament

252. *Thelohanellus potaili* Lalitha Kumari, 1969
(Fig. 252 a-c)

Diagnosis : Trophozoites creamy white, 1.0-1.5 mm in diameter; pansporoblasts mono- or disporous; spores elongate, oval in valvular view, ellipsoidal in sutural view; anterior end narrow, flat at the tip, posterior end rounded; shell valves thick, uniform with 4-5 parietal folds at the posterior region; sutural ridge prominent slightly curved, shifted to a side; sutural line clear; polar capsule single, broad, oval, terminal with distinct neck; polar filament long; sporoplasm finely granular, homogenous, occupying the entire extracapsular space; iodophilous vacuole large.

Size : Spore length 12.1-16.0 (13.0) μm , width 7.9-9.5 (8.2) μm ; polar capsule length 5.0-8.0 (5.9) μm , width 3.6-5.7 (4.3) μm ; polar filament length 60-71 (65.7) μm .

Host : *Labeo potail*; *site of infection* : fins; *pathogenicity* : not apparent.

Distribution : India : Andhra Pradesh : (Hyderabad city).

253. *Thelohanellus pyriformis* Thelohan, 1892
(Fig. 253)

Diagnosis : Spores tear drop-shaped in valvular and slightly bent in sutural view; anterior end narrow, posterior end rounded; covered with thick mucous envelope; polar capsule single, large, pyriform; polar filament forming 6 coils while inside the capsule; sporoplasm finely granular, homogenous, occupying the entire extracapsular space; iodophilous vacuole large, located centrally.

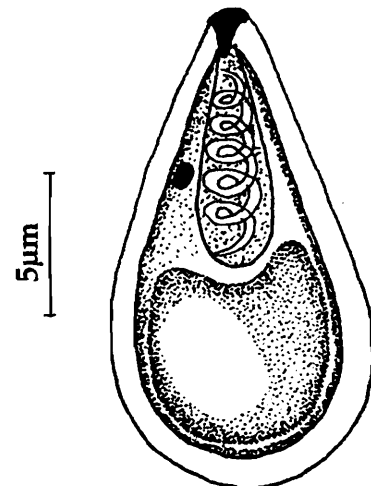


Fig. 253. *Thelohanellus pyriformis* : a. Fresh spore valvular view

Size : Spore length 16.0–23.0 μm , width 6.0–8.0 μm ; polar capsule length 8.2 μm , width 4.2 μm .

Host : *Tinca tinca*, *Rutilus rutilus*, *Abramis brama*, *Leuciscus idus*; major carps, minor carps and murrels; **site of infection :** gills; **pathogenicity :** massive hypertrophy of the endothelial cells.

Distribution : India : Haryana (Sonapet). *Elsewhere :* Europe, South East Asia.

Remarks : Ram *et al.* (1984) reported the occurrence of this species in major carps, minor carps and murrells in India.

254. *Thelohanellus qadrii* Lalitha Kumari, 1969

(Fig. 254 a-c)

Diagnosis : Spores large, pyriform in valvular view and arched in sutural view; anterior end narrow, posterior end rounded, one side flat and the other curved; spore valves thin, uniform, smooth, slightly asymmetrical; sutural line shifted to a side; polar capsule single, large, pear-shaped, terminal with broad rounded posterior region and a constriction in the middle region; polar filament forming 13 – 18 coils while inside the capsule, long, whip-like when extended; sporoplasm finely granular, homogenous, occupying the entire extracapsular space; iodophilous vacuole large, located centrally.

Size : Spore length 14.3–17.1 (14.7) μm , width 5.0–6.0 (5.4) μm ; polar capsule length 7.5–8.6 (8.2) μm , width 2.9–3.9 (3.8) μm ; polar filament length 115–204.5 (184.1) μm .

Host : *Labeo potail*; **site of infection :** gill filaments; **pathogenicity :** not apparent.

Distribution : India : Andhra Pradesh : (Hyderabad city).

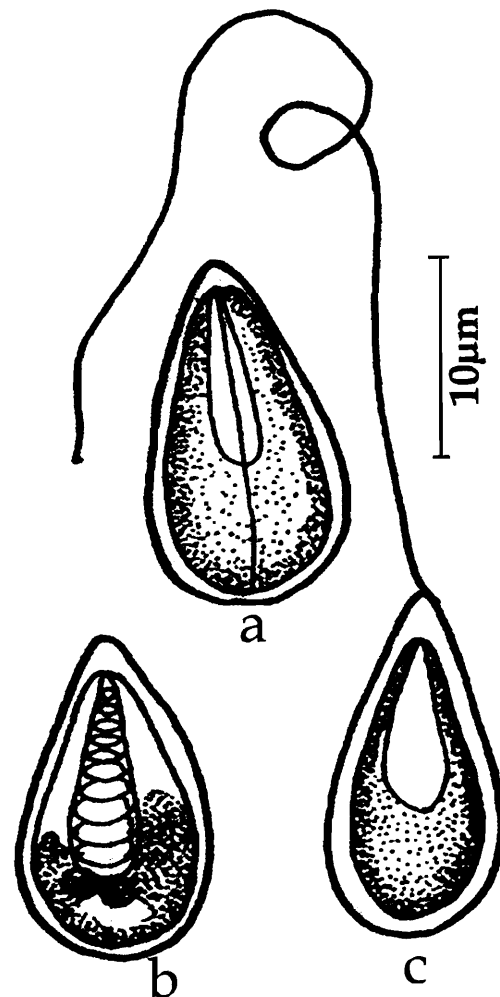


Fig. 254. *Thelohanellus qadrii* : a. Fresh spore valvular view, b. Spore stained with Giemsa, c. Spore with extruded polar filament

255. *Thelohanellus rodgi* Hagargi, Kundu and Haldar, 1970

Diagnosis : Spore almost pyriform; polar capsule pyriform, with coiled polar filament; sporoplasm binucleate; iodophilous vacuole 4-5 μm in diameter.

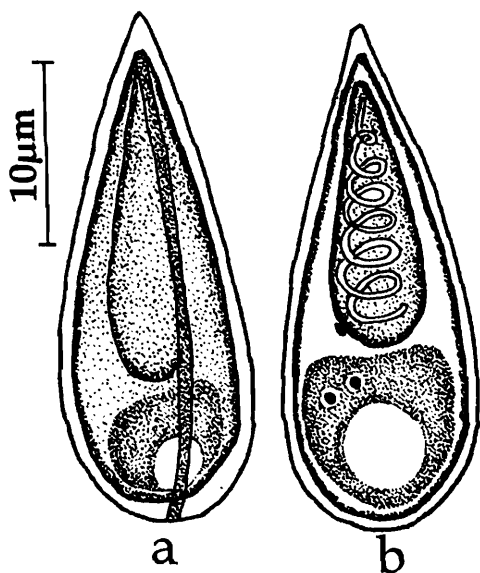
Size : Spore length 31.0-41.0 μm , width 10.0-15.0 μm ; polar capsule length 15.0-20.0 μm , width 7.0-8.0 μm .

Host : *Labeo calbasu* (Ham.); *site of infection* : gills; *pathogenicity* : not apparent.

Distribution : India : West Bengal (exact locality not known).

256. *Thelohanellus rohita* (Southwell and Prashad, 1918) emend. Chakravarty, 1943
(Syn. *Myxobolus rohita*, Southwell and Prashad, 1918)

(Fig. 255 a-b)



Diagnosis : Cysts opaque white, spherical or oval, 45-150 μm in largest diameter; spore elongately pyriform in front view with acutely pointed anterior and rounded posterior extremities; shell valve thick; sutural ridge very prominent; polar capsule elongately pyriform, provided with a highly coiled filament; iodophilous vacuole spherical.

Size : Spore length 30.0-33.0 μm , width 10.0-13.0 μm ; polar capsule length 16-20 μm , width 7.8-24 μm . polar filament 206 μm in length.

Host : *Labeo rohita* (Ham.), *Labeo bata*; *site of infection* : gills; *pathogenicity* : not apparent.

Distribution : India : West Bengal (North 24-Parganas district). *Elsewhere* : Bangladesh.

Fig. 255. *Thelohanellus rohita* :
a. Fresh spore sutural view,
b. Spore valvular view

257. *Thelohanellus sanjibi* Sarkar and Ghosh, 1990

(Fig. 256 a-d)

Distribution : Cyst small, oval to spherical, 100-200 μm in diameter; spores histozoic, egg-shaped to ovoidal in valvular view, lenticular in sutural view; anterior end more pointed than the posterior end; shell valve smooth, symmetrical, thick-walled; suture slightly curved, ridged; polar capsule single, broadly ovoidal to almost spherical,

opening anteriorly through a very short neck; polar filament forming 4-5 coils while inside the capsule; sporoplasm homogeneous filling the extracapsular cavity; iodophilous vacuole spherical.

Size : Spore length 12.0-13.0 (12.52) μm , width 8.0-8.5 (8.27) μm ; polar capsule length 4.0-5.0 (4.52) μm , width 3.5-4.5 (4.0) μm .

Host : *Mystus gulio* (Ham.); *site of infection* : kidney; *pathogenicity* : not apparent.

Distribution : India : West Bengal (Chinsurah, Hugli district).

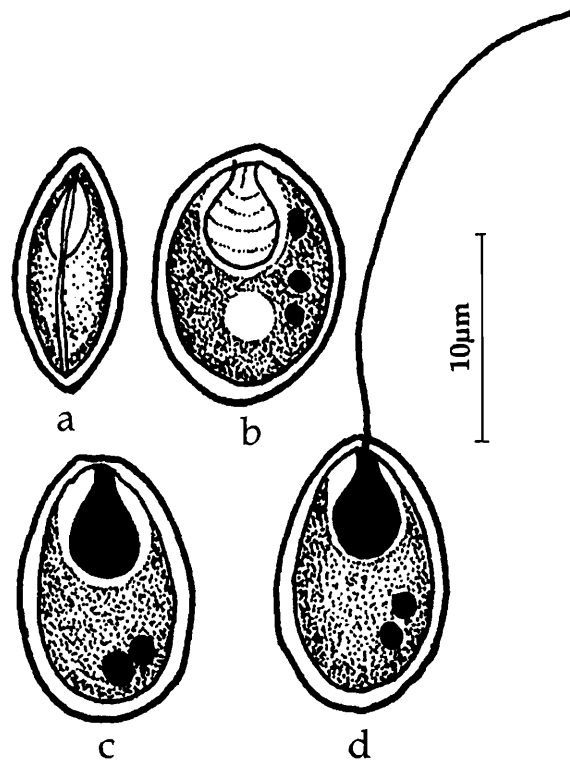


Fig. 256. *Thelohanellus sanjibi* : a. Fresh spore valvular view, b. Spore treated with iodine, c. Spore stained with Giemsa, d. Spore with extruded polar filament

258. *Thelohanellus seni* (Southwell and Prasad, 1918) emend. Chakravarty and Basu, 1948 (Syn. *Myxobolus seni*, Southwell and Prasad, 1918) (Fig. 257 a-b)

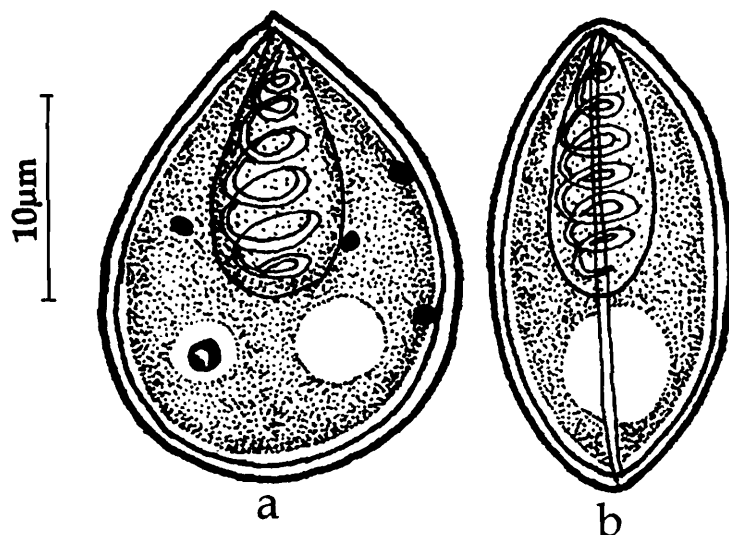


Fig. 257. *Thelohanellus seni* : a. Fresh spore valvular view, b. Spore sutural view

Diagnosis : Cysts roughly oval or lenticular, up to 1.1 mm; spore with two polar capsules and a short tail-like process; iodophilous vacuole present.

Size : Spore length 12.48-14.94 μm , width 8.56 μm ; polar capsule length 6.42 μm , width 4.52 μm .

Host : *Catla catla* (Ham.); *site of infection* : branchiae; *pathogenicity* : not apparent.

Distribution : India : West Bengal (Calcutta and North 24-Parganas district).

259. *Thelohanellus shortii* Qadri,
1967

(Fig. 258 a-c)

Diagnosis : Trophozoites small, pansporoblast mono or disporous; spores narrow, elongate, oval, pyriform or pear-shaped, tapering anteriorly, broad in the middle, round posteriorly; valves uniform, smooth; sutural ridge wide, slightly curved; polar capsule elongated, oval without duct; polar filaments making 3-4 fine loose coils while inside the capsule, wavy, thick when extruded; sporoplasm homogeneous, granular, occupying the space behind the polar capsule; polysaccharide inclusion small, posterior.

Size : Spore length 11.42-12.85 (12.53) μm , width 6.42-7.14 (6.91) μm ; polar capsule length 6.42-7.95 (7.07) μm , width 3.5-4.28 (4.2) μm ; polar filament length 38.42- 47.48 (42.95) μm .

Host : *Labeo fimbriatus*; *site of infection* : fins; *pathogenicity* : not apparent.

Distribution : India : Andhra Pradesh (Hyderabad city).

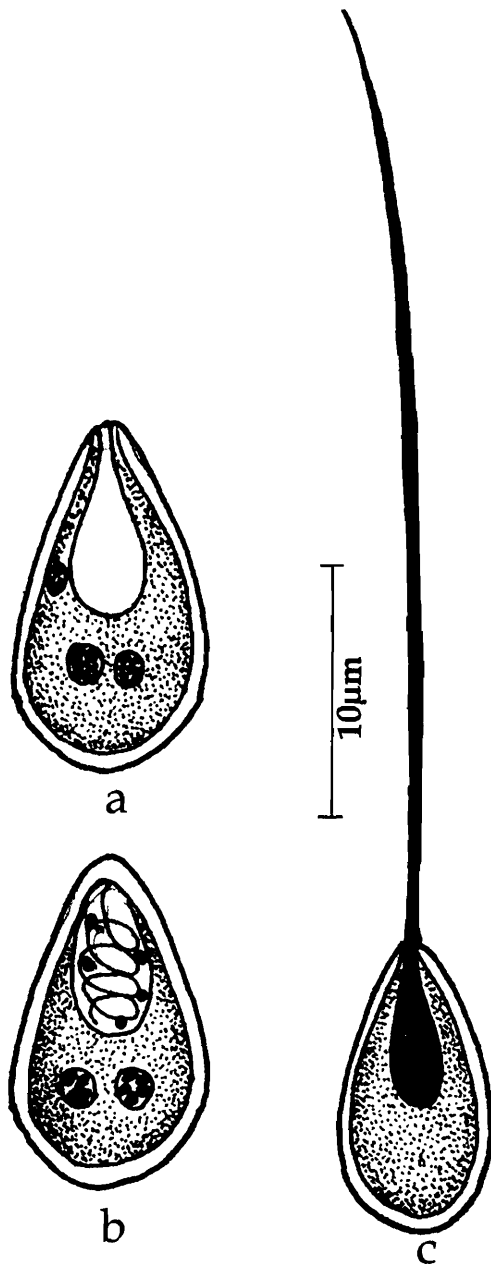


Fig. 258. *Thelohanellus sortii* : a. Fresh spore valvular view, b. Spore stained with Giemsa, c. Spore with extruded polar filament

260. *Thelohanellus sudevi* Sarkar and Ghosh, 1990
(Fig. 259 a-d)

Diagnosis : Cyst small oval to spherical, 100-200 μm ; spore histozoic, elongately ellipsoidal in valvular view and lenticular in sutural view; anterior end slightly acuminate, posterior end rounded; shell valves two, smooth, symmetrical, thick-walled; suture broad, thick and almost straight with no ridge; polar capsule single, pyriform; polar

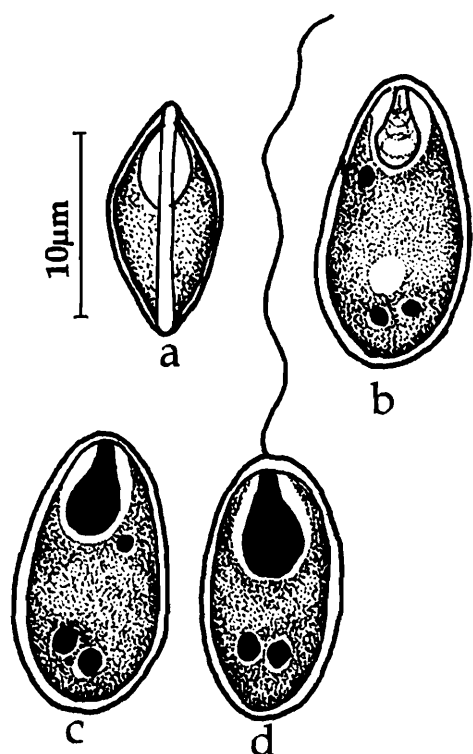


Fig. 259. *Thelohanellus sudevi* : a. Fresh spore valvular view, b. Spore treated with iodine, c. Spore stained with Giemsa, d. Spore with extruded polar filament

filament making 4-5 coils while inside the capsule, sporoplasm binucleate, homogenous, filling the large extracapsular cavity; iodophilous vacuole small.

Size : Spore length 13.0-15.0 (14.05) μm , width 5.0-6.5 (5.87) μm ; polar capsule length 4.75-6.0 (5.17) μm , width 2.0- 3.0 (2.65) μm ; polar filament length 38.42-47.48 (42.95) μm .

Host : *Amblypharyngodon mola* Ham; *site of infection* : kidney; *pathogenicity* : not apparent.

Distribution : India : West Bengal (Chinasurah, Hugli district).

261. *Thelohanellus wallagoi* Sarkar, 1985a

(Fig. 260 a-d)

Diagnosis : Spore pyriform in valvular view and lenticular in sutural view, anterior end pointed and posterior end rounded; shell valves two, smooth, symmetrical and thick, suture slightly curved; polar capsule single, pyriform, anterior, eccentrically placed; polar filament forming 4-5 coils inside the capsule, sporoplasm binucleate, homogenous, filling the large extracapsular cavity; iodophilous vacuole absent.

Size : Spore length 8.0-11.2 (9.25) μm , width 4.0-6.4 (4.85) μm ; polar capsule length 4.5-6.4 (5.47) μm , width 2.5-3.0 (2.71) μm ; polar filament length 20 μm .

Host : *Wallago attu* Bleeker; *site of infection* : gall bladder; *pathogenicity* : not apparent.

Distribution : India : West Bengal (East bank of Padma River).

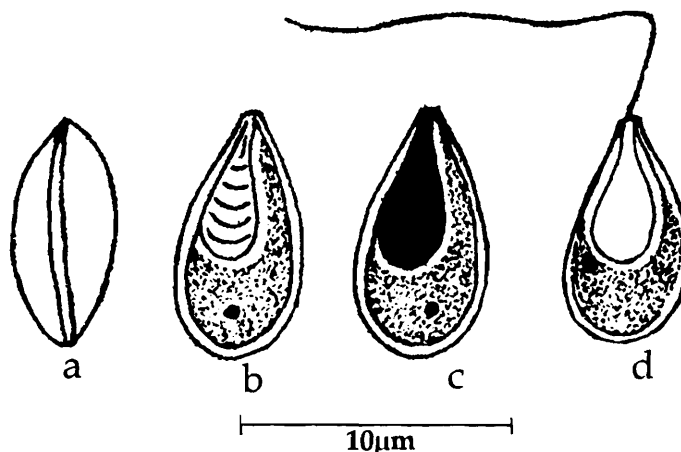


Fig. 260. *Thelohanellus wallagoi* : a. Fresh spore valvular view, b. Spore treated with iodine, c. Spore stained with Giemsa, d. Spore with extruded polar filament

Genus *Unicauda* Davis, 1944

Diagnosis : As in the key.

Remarks : The distinctive feature of the Genus *Unicauda* is the presence of a caudal appendage which is not an extension of the spore body (Lom and Noble, 1984). The species identification of the genus *Unicauda* Davis has a perplexed taxonomic history and many descriptions are moved in and out of this genus. Davis (1944) transferred as many as 10 species of *Henneguya* to the genus *Unicauda*. Later Gupta and Khera (1987) transferred 8 species of *Unicauda* described till then from India to the genus *Henneguya* leaving behind *U. andhrae* as the only valid species to which he added *U. armati*. Cone and Melody (2000) while reviewing the genus *Unicauda* considered all the species transferred earlier by Gupta and Khera (1987) to the genus *Henneguya* including *U. andhrae* and *U. armati* as members of genus *Unicauda* but with questionable taxonomic identity. We, however, reviewed the species and propose to retain *U. andhrae*, *U. aplocheili* and *U. armati* as valid species of *Unicauda* since the authors mentioned that the tail is not an extension of the spore valve and is different from the spore body. In the three species *U. irregularis*, *U. minuta*, *U. theraponi* added later by Haldar *et al.* (1997) the generic identity remains questionable since the authors described the caudal appendage as single uniramous extension of the spore valves posteriorly. Nevertheless we retained these species in the genus *Unicauda* giving priority to the author's identification even though requiring re-examination later.

Key to the species

1. Polar capsules equal 2
 1. 1 Spore oval or pyriform; polar capsules pyriform, equal, terminal; spore 38.4-47.3 (42.5) μm x 4.0-5.4 (4.9) μm *U. andhrae*
 - 1.2 Spore oval; caudal appendage attached to spore body postero-laterally; spore valves smooth; sutural line faint; polar capsules pyriform, equal; spore 7.5 – 9.0 (8.4) μm x 5.6-7.0 (5.71) μm *U. armati*
 - 1.3 Spore pyriform; anterior end pointed, posterior end round; spore valves thin, smooth; polar capsules elongated, equal, closely placed, overlapping each other at the anterior tip; spore 16.8-18.2 (16.912) μm x 5.6–7.0 (5.712) μm
..... *U. aplocheili*
 - 1.4 Spore body broadly elongated; caudal appendage single, undivided; polar capsules equal, pyriform; spore 8.1–13.0 (9.35) μm x 3.2–5.7 (4.14) μm *U. minuta*
 - 1.5 Spore body pyriform; caudal appendage single, undivided; polar capsules equal, pyriform; spore 14.6–22.8 (19.76) μm x 4.0–8.1 (5.5) μm *U. theraponi*

2. Polar capsules unequal

- 2.1 Spore oblongate, spore body pyriform caudal appendage single, undivided; polar capsules unequal, pyriform; spore 24.0–39.1 (27.99) μm x 9.7–19.5 (13.3) μm ..
 *U. irregularis*

262. *Unicauda andhrae* Kalavati and Narasimhamurti, 1981
 (Fig. 261 a-b)

Diagnosis : Trophozoite disporous; spores oval or pyriform; caudal appendage single undivided not an extension of the spore valves; anterior end of caudal appendage broad and concave into which the posterior part of the spore body fitted; spore valves smooth; sutural line fine; polar capsules 2, pyriform, equal, terminal, opening independently on either side of sutural line; polar filament making 4-5 coils while inside the capsule; sporoplasm occupying the entire extracapsular spore cavity; iodophilous vacuole small and spherical.

Size : Spore length 38.4-47.3 (42.5) μm , width 4.0-5.4 (4.9) μm ; caudal appendage length 20.8 – 24.5 (22.8) μm ; polar capsule length 5.0-6.4 (5.9) μm , width 1.0-1.6 (1.2) μm ; polar filament length 25.4-30.4 (28.2) μm .

Host : *Channa* (= *Ophicephalus*) *gachua*; **site of infection :** gills; **pathogenicity :** not apparent.

Distribution : India : Andhra Pradesh (Ananthgiri, Visakhapatnam district).

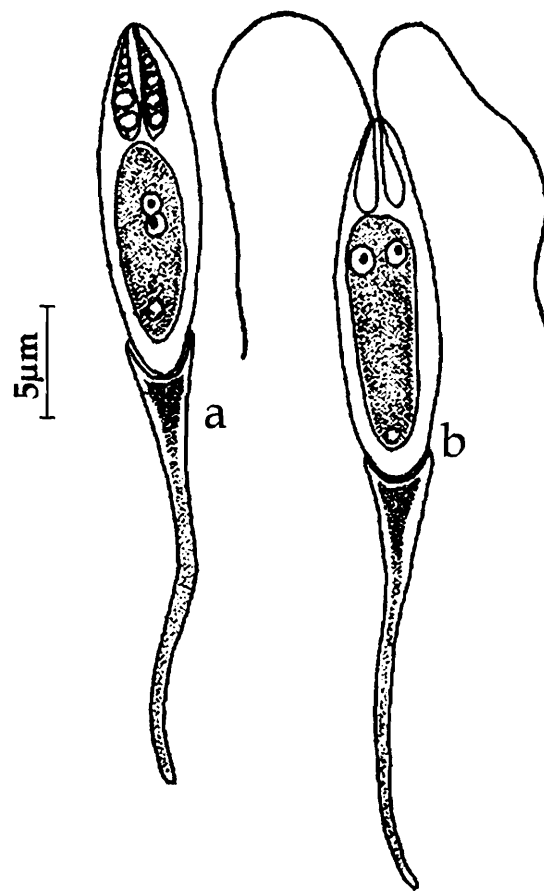


Fig. 261. *Unicauda andhrae* : a. Spore stained with Giemsa, b. Spore with extruded polar filaments

263. *Unicauda aplocheili* Kalavati, Venkataeswara Rao and Vaidehi, 1991
 (Fig. 262 a-c)

Diagnosis : Trophozoite disporous; spores pyriform, ends pointed, caudal appendage single undivided, distinct, not an extension of the spore valves; anterior end of caudal appendage cup-like deeply stained depression into which the posterior part of the spore body fitted into, distal end of the appendage pointed and refractile; spore valves thin, smooth; sutural line faint; polar capsules 2, elongated, equal, closely placed, overlapping

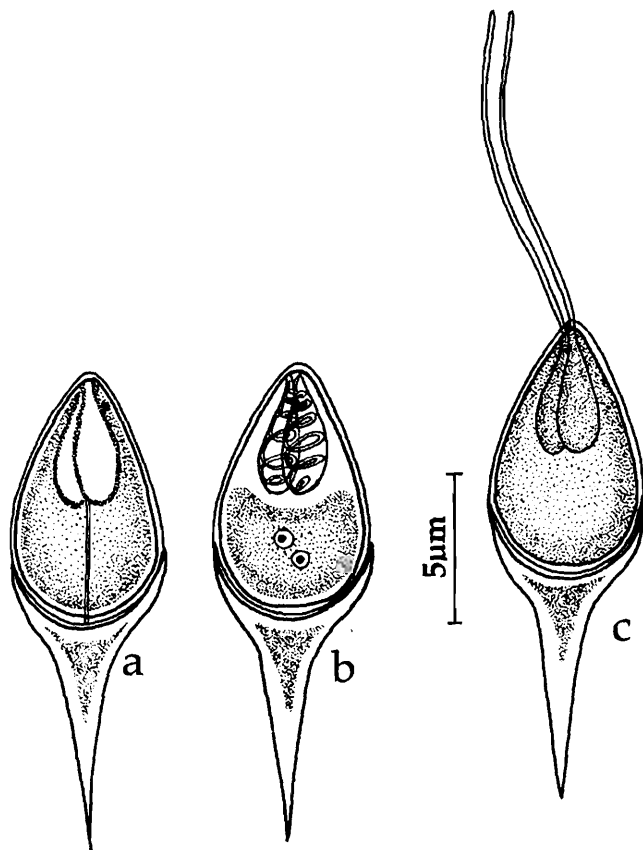


Fig. 262. *Unicauda aplocheili* : a. Fresh spore valvular view, b. Spore stained with Giemsa, c. Spore with extruded polar filament

each other at the anterior tip, polar filament making 4-5 coils while inside the capsule; sporoplasm uni or binucleate occupying the entire extracapsular spore cavity, iodophilous vacuole small and spherical.

Size : Spore total length 16.8-18.2 (16.912) μm ; spore body length 9.8-11.2 (10.3) μm ; width 5.6-7.0 (5.712) μm ; caudal appendage length 5.6-8.4 (7.5) μm ; polar capsule length 5.0-6.4 (5.9) μm ; width 1.2-1.6 (1.4) μm ; polar filament length 16.0-21.2 (18.6) μm .

Host : *Aplocheilus panchax*; *site of infection* : scales and skin; *pathogenicity* : ulcerated skin with sloughed pockets.

Distribution : India : Orissa (Chilka Lake).

264. *Unicauda armati* Gupta and Khera, 1987
(Fig. 263)

Diagnosis : Cysts light yellow, almost round, 0.510 mm x 0.391 mm in size; spore oval in valvular view; one side more convex than the other; caudal appendage single undivided, attached to spore body postero-laterally, not an extension of the spore valves; spore valves smooth; sutural line faint; polar capsules 2, pyriform, equal, occupying less than half of the spore; sporoplasm binucleate occupying the entire extracapsular spore cavity.

Size : Spore body length 7.5-9.0 (8.4) μm , width 5.6-7.0 (5.71); caudal appendage length 8.0-15.0 (11.46) μm ; polar capsule length 2.0-3.0 (2.66) μm ; width 1.5-2.0 (1.6) μm , polar filament length 12.0-17.0 μm .

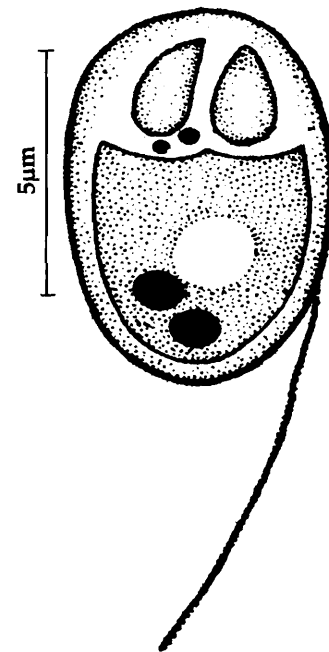


Fig. 263. *Unicauda armati* : Spore stained with Giemsa

Host : *Mastacembalus armatus*; *site of infection* : gills; *pathogenicity* : not apparent.

Distribution : India : Punjab (Nangal and Ferozpur).

265. *Unicauda irregularis* Haldar, Samal and Mukhopadhyay, 1997
(Fig. 264 a-b)

Diagnosis : Spores oblongate, spore body pyriform; anterior end pointed, posterior end round, caudal appendage single undivided; shell valves thin, smooth; polar capsules 2, unequal, pyriform; sporoplasm granular, occupying the entire extracapsular spore cavity; iodophilous vacuole present

Size : Spore total length 24.0–39.1 (27.99) μm ; spore body length 9.7–19.5 (13.3) μm , width 4.9–6.5 (5.05) μm ; caudal appendage length 9.8–22.8(14.79) μm ; polar capsule length 4.0–6.5 (5.02) μm , width 1.6–4.0 (2.28) μm .

Host : *Mystus vittatus* (Bloch); *site of infection* : body muscles; *pathogenicity* : not apparent.

Distribution : India : Orissa (Cuttack).

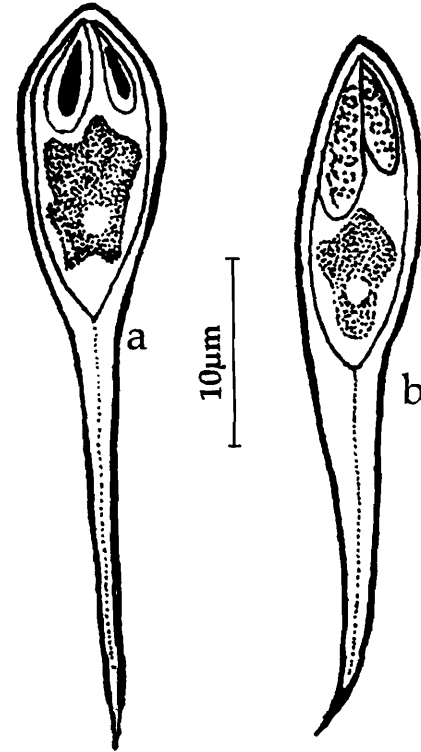


Fig. 264. *Unicauda irregularis* : a & b.
Fresh spores valvular view

266. *Unicauda minuta* Haldar, Samal and Mukhopadhyay, 1997
(Fig. 265 a-b)

Diagnosis : Spore body broadly elongated; anterior end pointed, posterior end round; caudal appendage single undivided; shell valves thin, smooth; polar capsules 2, equal, pyriform; sporoplasm granular, binucleate, occupying the entire extracapsular spore cavity; large iodophilous vacuole present

Size : Spore total length 16.3–26.0 (20.86) μm ; spore body length 8.1–13.0 (9.35) μm , width 3.2–5.7 (4.14); caudal appendage length 6.5–16.3 (11.4); polar capsule length 1.6–4.9 (3.88) μm , width 1.6–3.5 (2.15) μm .

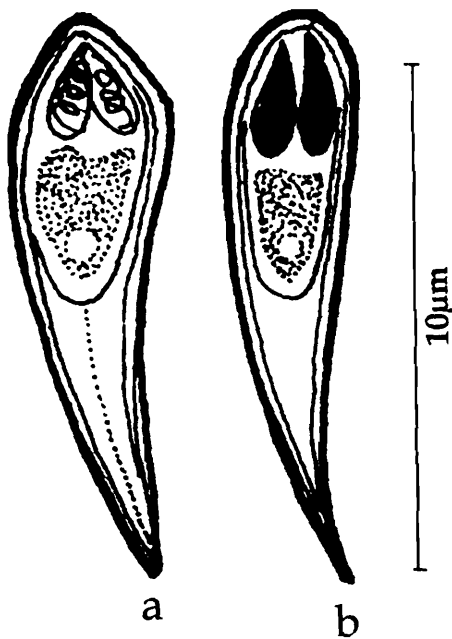
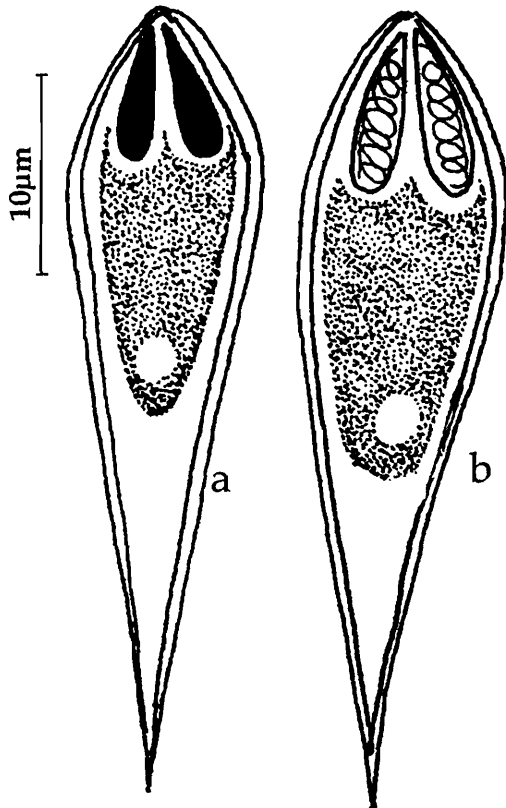


Fig. 265. *Unicauda minuta* : a & b.
Fresh spores valvular view

Host : *Etroplus suratensis* (Bloch); *site of infection* : gills; *pathogenicity* : not apparent.

Distribution : India : Orissa (Gangadharpur, Rambha district).

267. *Unicauda theraponi* Haldar, Samal and Mukhopadhyay, 1997
(Fig. 266 a-b)



Diagnosis : Spore body pyriform with slightly pointed anterior; single undivided caudal appendage; shell valves thin, smooth; polar capsules 2, equal, pyriform; sporoplasm granular, binucleate, crescentic occupying the entire extracapsular spore cavity; iodophilous vacuole present.

Size : Spore total length 27.7–39.1 (32.31) μm ; spore body length 14.6–22.8 (19.76) μm , width 4.0–8.1 (5.5) μm ; caudal appendage length 8.1–19.5 (12.85) μm ; polar capsule length 4.9–8.1 (6.18) μm , width 1.6–3.2 (2.52) μm .

Host : *Therapon jarbua* (Bleeker); *site of infection* : gills; *pathogenicity* : not apparent.

Distribution : India : Orissa (Balugoan, Chilka Lake).

Fig. 266. *Unicauda theraponi* : a & b. Fresh spores valvular view

Genus *Phlogospora* Qadri, 1962b

Diagnosis : As in the key.

Key to the species

1. Spore bunsen-flame-like, single valve, spore body fitting into cup-like depression of the tail-like appendage, polar capsule 1 *P. mysti*
2. Spore pyriform, valves 2 smooth, symmetrical, polar capsule 1 *P. oculatus*

268. *Phlogospora mysti* Qadri, 1962b
(Fig. 267 a-b)

Diagnosis : Spore bunsen-flame-like; anterior end pointed and posterior end rounded; spore body enveloped by a thin membrane; shell composed of single valve, uniform, smooth; no sutural line; posterior portion with a tail-like appendage bifurcating as thin long filamentous part, anterior end of the appendage broad with cup-like depression into which the spore body fitted; polar capsule single, elongated, bottle-shaped, subterminal; polar filament making 10-11 coils while inside the capsule, base of the filament showing a pinhead-like structure in the capsule; sporoplasm dense, granular, binucleate, not extending into caudal fold; iodophilous vacuole spherical or oval near the posterior end.

Size : Spore total length 35.0-42.0 μm ; spore body length 14-18.0 μm , width 3.5-5.0 μm ; caudal appendage 21-24.0 μm ; polar capsule length 7.0-9.0 μm , width 1.7-2.5 μm ; polar filament length 65.0-70.0 μm .

Host : *Mystus bleekeri*; **site of infection** : gills; **pathogenicity** : not apparent.

Distribution : India : Andhra Pradesh (Hyderabad city fish market).

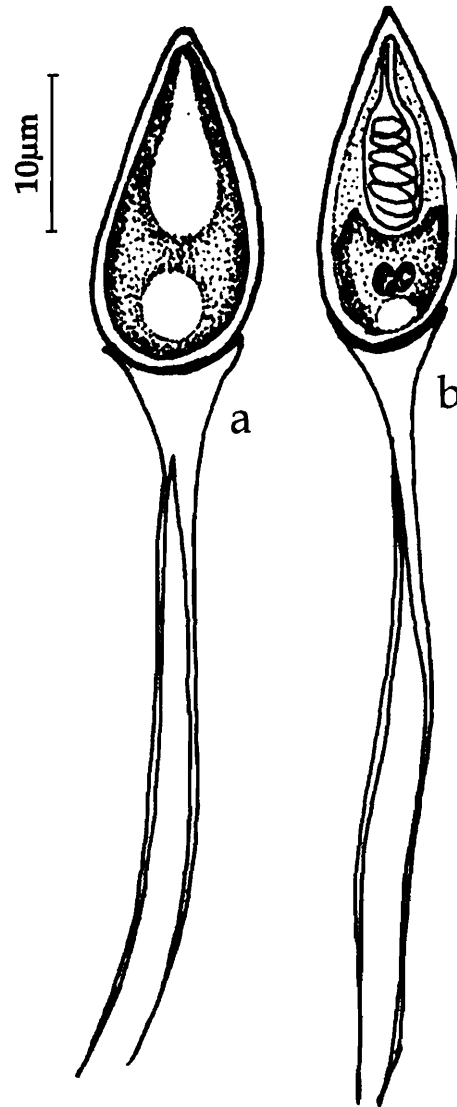


Fig. 267. *Phlogospora mysti* : a. Fresh spore valvular view, b. Spore stained with Giemsa

269. *Phlogospora oculatus* Susha and Janardanan, 1995
(Fig. 268 a-c)

Diagnosis : Cysts round to oval, milky white, translucent to opaque, 126.46-150.8 μm ; spore pyriform, widest at the middle tapering anteriorly, rounded posteriorly; caudal process long, tapering, bifurcated, fitted at the posterior end of the spore; shell valves smooth, symmetrical; sutural line straight; polar capsule single, oval; polar filament making 10-13 coils while inside the capsule; base of the filament with pinhead-like body; sporoplasm finely granular, filling the extracapsular spore cavity; iodophilous vacuole present.

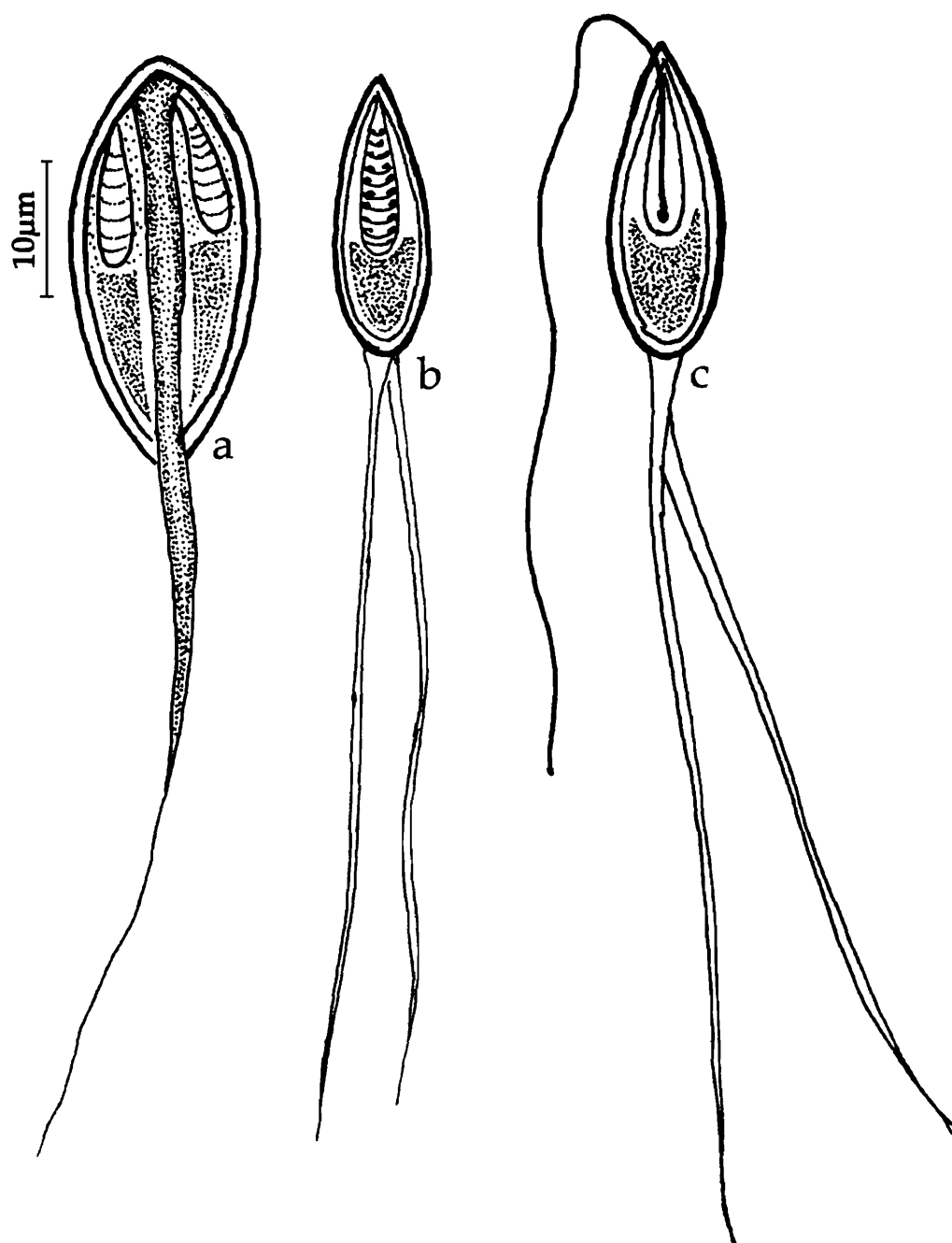


Fig. 268. *Phlogospora oculatus* : a. Fresh spore sutural view, b. Spore valvular view, c. Spore stained with Giemsa

Size : Spore total length 45.0 -90.75 (65.7) μm ; spore body length 13.5-24.0 (18.47) μm , width 2.7-3.45 (3.07) μm ; caudal appendage 30.77-68.25 (50.9) μm ; polar capsule length 7.5-13.2 (9.58) μm , width 1.5-3.1 (2.39) μm ; polar filament length 43.5-79.65 (54.3) μm .

Host : *Mystus oculatus*; *site of infection* : gill filaments; *pathogenicity* : not apparent.

Distribution : India : Kerala (Trisur district).

Order MULTIVALVULIDA Schulman, 1959

Key to the families

1. Spore with three shell valves and 3 polar capsules Family TRILOSPORIDAE
2. Spores with four shell valves each containing one polar capsule
..... Family KUDOIDAE

Family TRILOSPORIDAE Schulman, 1959

Diagnosis : As in the key.

Genus *Unicapsula* Davis, 1924

Diagnosis : Spores subspherical with three unequal shell valves; one small valve covering a single spherical polar capsule; two larger, bilaterally symmetrically arranged valves containing capsular rudiments difficult to distinguish under light microscope; two uninucleate sporoplasms one enveloping the other; trophozoites large, polysporous; no pansporoblast formation; histozoic in muscles of marine fish.

Key to the species

1. Spore spherical, valves asymmetrical, smooth, sutural line sinuous polar capsule single, spherical; spore 5.98-6.9 (6.43) μm *U. chirocentrusi*
2. Spore trilocular, valves asymmetrical, 2 valves round, one large, flat, smooth; polar capsule single, spherical, eccentrically placed; spore 10.0-14.4 μm x 9.0-11.0 μm *U. maxima*

270. *Unicapsula chirocentrusi* Sarkar, 1984b

(Fig. 269 a-b)

Diagnosis : Trophozoites not seen; spores histozoic, spherical; valves asymmetrical, smooth; sutural line sinuous but indistinct; polar capsule single, spherical; polar filament making 2-3 turns while inside the capsule; sporoplasms two, lenticular; no iodophilous vacuole.

Size : Spore diameter 5.98-6.9 (6.43) μm , polar capsule 3.2-3.8 μm in diameter.

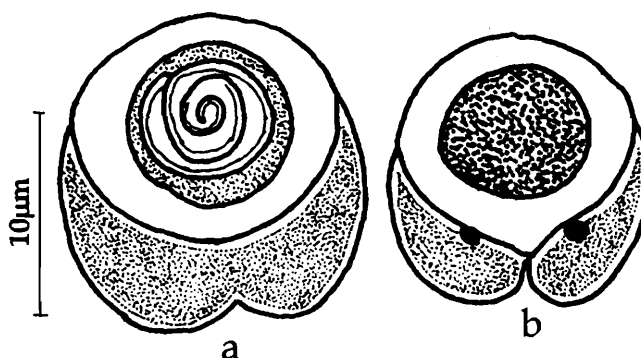


Fig. 269. *Unicapsula chirocentrusi* : a & b. Fresh spores valvular view

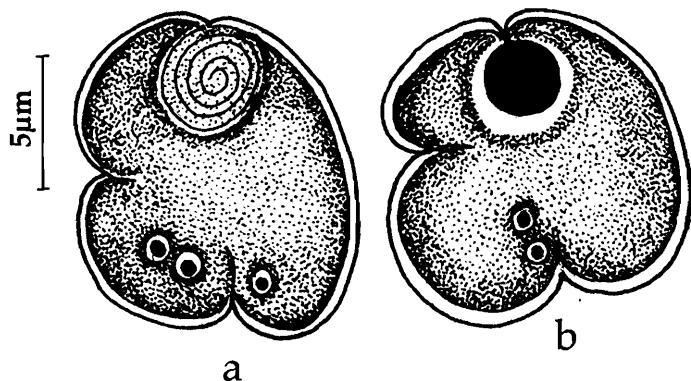
Host : *Chirocentrus dorab* Day; *site of infection* : skeletal muscle; *pathogenicity* : not apparent.

Distribution : Indian southern coast of Indian sea (exact location not mentioned).

271. *Unicapsula maxima* Sarkar, 1999b

(Fig. 270 a-b)

Diagnosis : Spores trilocular; valves asymmetrical, 2 valves round, one large, flat, smooth; sutural line distinct at the periphery, obscure at the center; polar capsule single, spherical, eccentrically placed; polar filament making 3-4 turns while inside the capsule; sporoplasm bi or uninucleate, extra capsular cavity large.



Size : Spore length 10.0–14.4 (12.28) µm, width 9.0–11.0 µm; polar capsule 3.2–4.5(3.8) µm in diameter.

Host : *Pseudosciaena coibar* (Ham.); *site of infection* : kidney parenchyma; *pathogenicity* : not apparent.

Fig. 270. *Unicapsula maxima* : a. Spore stained with Giemsa, b. Fresh spore valvular view

Distribution : India : West Bengal (24 Parganas district).

Family KUDOIDAE Meglitsch, 1947

Diagnosis : As in the key.

Genus *Kudoa* Meglitsch, 1947

Diagnosis : Spores stellate or quadrate in apical view, sutural line indistinct, polar capsules pyriform, two uninucleate sporoplams one enveloping the other, histozoic in marine fishes.

Key to the Species

1. Spores quadrate without lateral inflations 3
2. Spores spherical or rectangular with inflations 4
- 3.1. Spores triangular in valvular view enclosed in mucous envelop; polar capsules equal, pyriform *K. atropi*
- 3.2. Spores triangular in valvular view; polar capsules club-shaped *K. sphyraeni*

- 3.3. Spores club-shaped in valvular view; polar capsules club-shaped, equal
 *K. tetraspora*
- 3.4. Spores club-shaped with deep notches in valvular view; polar capsules pyriform,
 unequal *K. valamugili*
- 4.1 Spore large, with 4 lateral inflations from the capsular surface; polar capsule
 tubular and convergent *K. bengalensis*
- 4.2. Spore 'small', not forming any stellate shape; polar capsule pyriform and
 convergent *K. tachysuræ*
- 4.3. Spore rectangular with low lateral inflations, polar capsule pyriform
 *K. chilensis*

272. *Kudoa atropi* Sandeep, Kalavati and Narasimhamurti, 1986
 (Fig. 271 a-d)

Diagnosis : Trophozoites opaque white, 0.5-1.0 mm in diameter; pansporoblast disporous; spores enclosed in a mucous envelop; quadrate in polar view, with deep notches extending $\frac{1}{4}$ the length of the sutural line; ends rounded; triangular with rounded corners and bluntly pointed anterior end in valvular view; shell valves smooth, equal; sutural line faint; polar capsules 4, terminal, equal, pyriform; polar filament

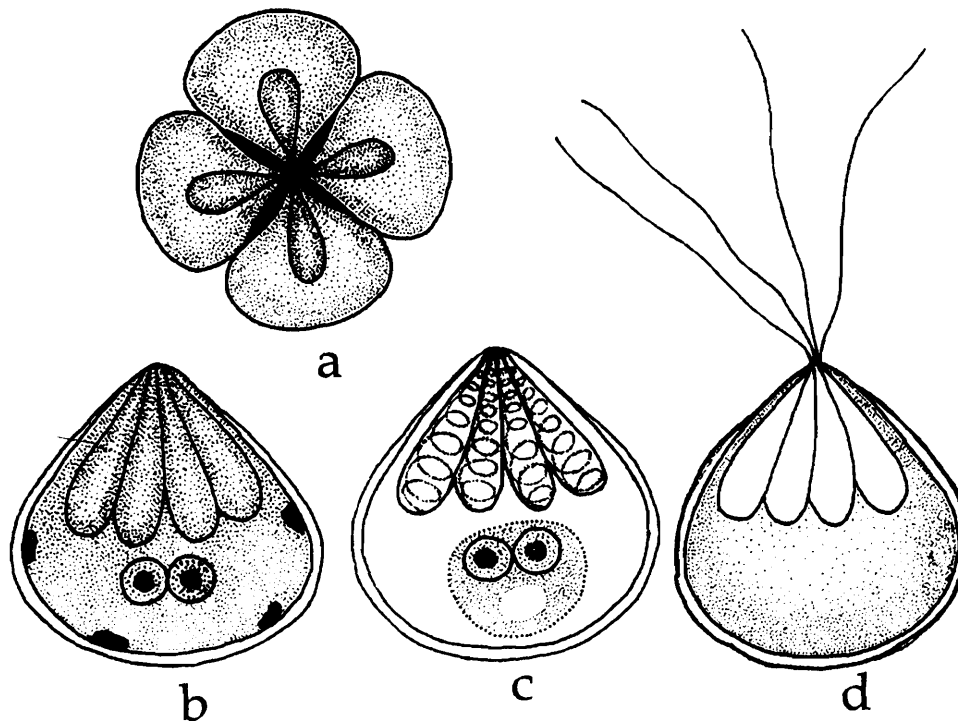


Fig. 271. *Kudoa atropi* : a. Fresh spore valvular view, b. Spore polar view, c. Spore stained with Giemsa, d. Spore with extruded polar filament

making 6-7 coils while inside the capsule; two uninucleate hyaline sporoplasms one enclosing the other, sometimes appearing as oval binucleate body.

Size : Spore length 8.0–11.0 (10.0) μm , width 8.0–11.0 (10.0) μm , thickness 8.0–9.5 (9.0) μm ; polar capsule length 3.0–3.6 (3.3) μm , width 1.6–1.8 (1.7) μm ; polar filament length 8.0–12.0 (10.0) μm .

Host : *Atropus atropus*; *site of infection* : gill filaments; *pathogenicity* : not apparent.

Distribution : India : Andhra Pradesh (Catches at the Fishing harbour, Visakhapatnam).

273. *Kudoa bengalensis* Sarkar and Mazumder, 1983a
(Fig. 272 a-b)

Diagnosis : Spore ovoid, thin-walled and with four lateral inflations from the capsular surface giving it a stellate shape; two indistinct sutural lines dividing the spore into four quadrants; each quadrant with a polar capsule and a lateral inflation extending as median, bluntly pointed edge, meeting with the other quadrant at the sutural lines through small notches; polar capsules four, almost tubular and convergent; sporoplasm finely granular, uninucleate filling the spore cavity.

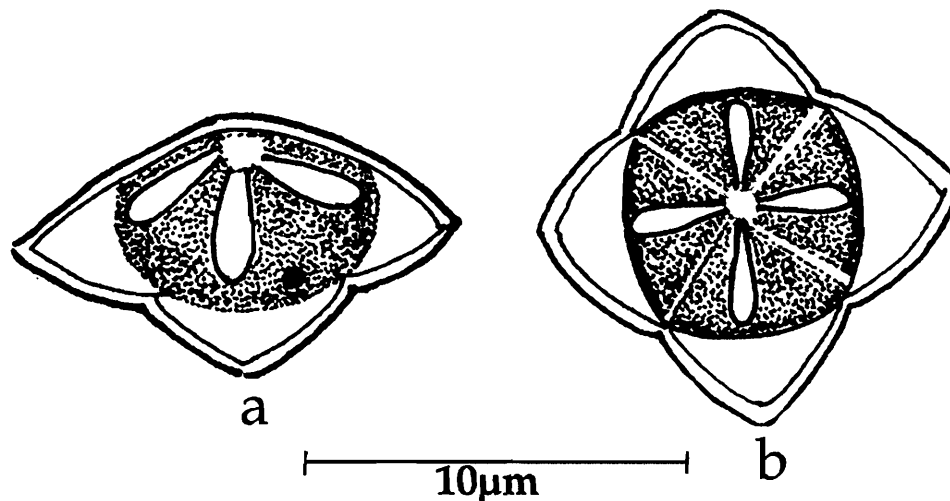


Fig. 272. *Kudoa bengalensis* : a. Fresh spore sutural view, b. Spore valvular view

Size : Spore length 7.0–8.5 (7.87) μm , width 7.0–11.0 (8.44) μm ; polar capsule length 3.0–4.8 (3.8) μm , width 1.8–2.0 (1.95) μm .

Host : *Tachysurus platystomus* (Day); *site of infection* : skeletal muscle; *pathogenicity* : not apparent.

Distribution : India : West Bengal (Bay of Bengal).

274. *Kudoa cascasia* Sarkar and Ray chaudhury, 1996
(Fig. 273 a-c)

Diagnosis : Spore quadrate in basal and apical view, triangular or pyramidal with truncate apex in side view; no lateral inflations; sutures fine visible only at the periphery of the valves; polar capsules four, equal, pyriform, convergent; sporoplasm binucleate granular located behind the capsule; iodophilous vacuole absent; no mucous envelop.

Size : Spore length 6.0-8.0 (6.6) μm , width 7.0-9.0 (8.2) μm , thickness 7.0-8.0 (7.6) μm ; polar capsule length 2.5-3.5 (3.1) μm , width 1.2-2.04 (1.62) μm .

Host : *Sicamugil cacasias* (Ham); **site of infection :** mesentery; **pathogenicity :** not apparent.

Distribution : India : West Bengal (Hugli estuary).

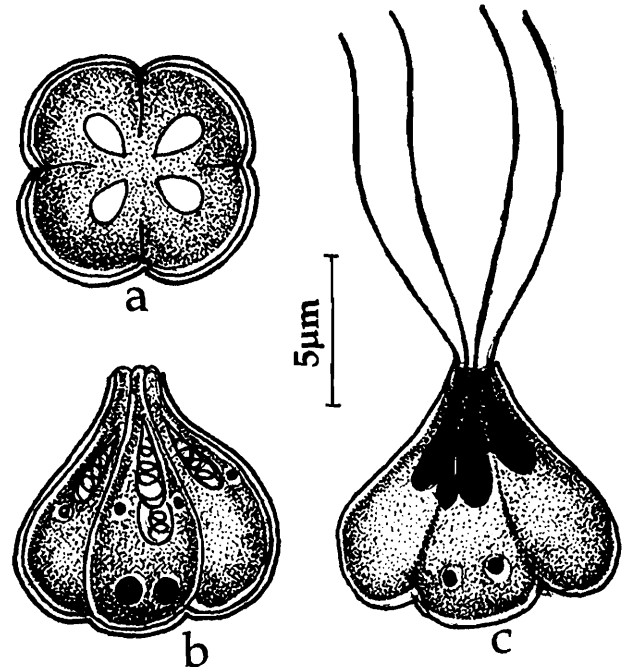


Fig. 273. *Kudoa cascasia* : a. Fresh spore sutural view, b. Spore valvular view, c. Spore with extruded polar filament

275. *Kudoa chilensis* Tripathi, 1952
(Fig. 274 a-c)

Diagnosis : Spore rectangular in apical view; lateral inflations low; shell valve thin and smooth; polar capsules four, equal, pyriform, convergent; sutures fine; sporoplasm granular.

Size : Spore length 5.5 μm , width 7.2 μm ; polar capsule length 3.5 μm , width 1.0-1.5 μm ; polar filament 10 μm .

Host : *Strongilura strongilura*; **site of infection :** muscle; **pathogenicity :** not apparent.

Distribution : India : Orissa (Chilka lake).

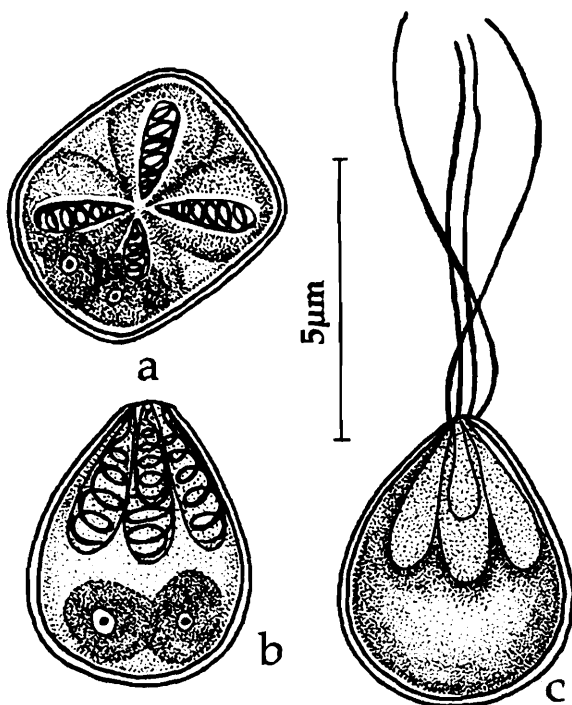


Fig. 274. *Kudoa chilensis* : a. Fresh spore sutural view, b. Spore valvular view, c. Spore with extruded polar filament

276. *Kudoa coibori* Sarkar, 1999b
(Fig. 275 a-d)

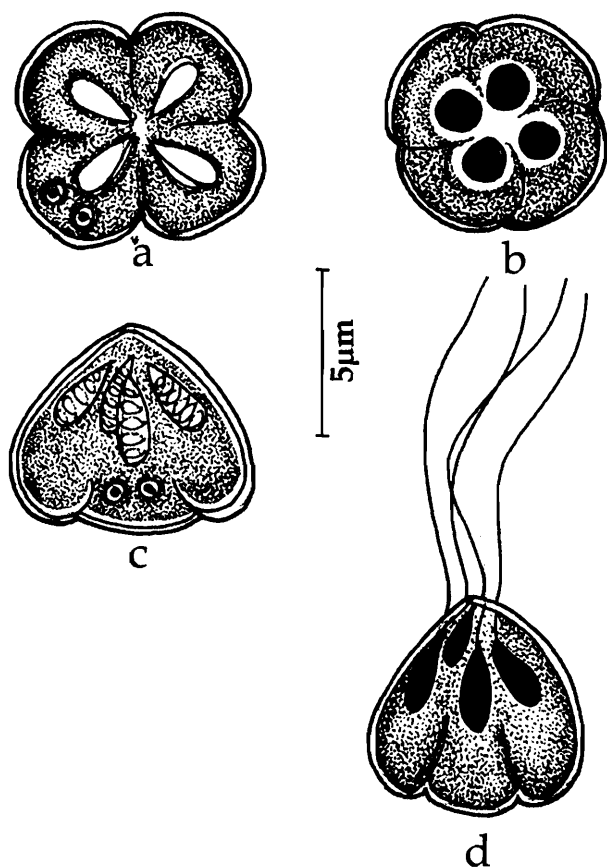


Fig. 275. *Kudoa coibori* : a & b. Spore valvular view, c. Spore sutural view, d. Spore with extruded polar filament

Diagnosis : Spore spherical to quadrate in capsular view, triangular in side view; no lateral inflations; shell valves smooth symmetrical, very thin; sutures fine, visible only at the periphery of the valves; polar capsules four, unequal, pyriform, convergent; one polar capsule smaller than the other three; polar filament making 5 – 6 coils while inside the capsule; sporoplasm binucleate granular located behind the capsule, no mucous envelop.

Size : Spore length 6.0-7.0 (6.6) μm , width 7.5-8.5 (8.0) μm , thickness 8.5-9.8 (9.2) μm ; polar capsule length 2.5-4.0 (3.3) μm , width 1.0-1.8 (1.6) μm .

Host : *Pseudosciaena coibar* (Ham); **site of infection :** gut wall; **pathogenicity :** not apparent.

Distribution : India : West Bengal (24 Parganas district).

277. *Kudoa haridasae* Sarkar and Ghosh, 1991b
(Fig. 276 a-c)

Diagnosis : Spores stellate in apical view; boat-like or triangular in side view with four lateral equal symmetrical, petaloid, inflations originating from the basal side of the spore; sutural line indistinct; polar capsules small, pyriform, symmetrical, strongly converging anteriorly; sporoplasm binucleate filling the spore cavity, iodophilous vacuole absent.

Size : Spore length 4.0 -5.5 (5.0) μm , width 9.0 -11.0 (10.07) μm ; polar capsule

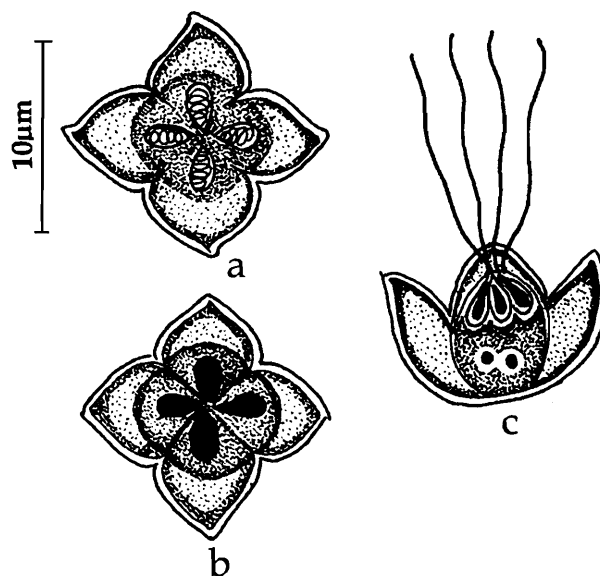


Fig. 276. *Kudoa haridasae* : a. Spore stained with Giemsa, b. Fresh spore valvular view, c. Spore with extruded polar filament

length 2.0-3.0 (2.75) μm , width 1.0-1.2 (1.11) μm .

Host : *Mugil parsia*; *site of infection* : gall bladder; *pathogenicity* : not apparent.

Distribution : India : West Bengal (Hooghly estuary).

278. *Kudoa sagarica* Das, 1996

(Fig. 277 a-d)

Diagnosis : Spore rectangular in polar view, with notches extending inside; valves thin, smooth, transparent; sutural line very faint; polar capsules 4, pyriform, equal; sporoplasms hemispherical, binucleate.

Size : Spore length 12.5-14.0 (13.0) μm , width 10.0-12.0 (11.0), thickness 8.5-10.5 (9.0) μm ; polar capsule length 3.0-4.0 (3.7) μm , width 2.5-3.5 (3.05) μm .

Host : *Liza parsia*; *site of infection* : gall bladder; *pathogenicity* : not apparent.

Distribution : India : West Bengal : (Sagar Island, South 24 Parganas district).

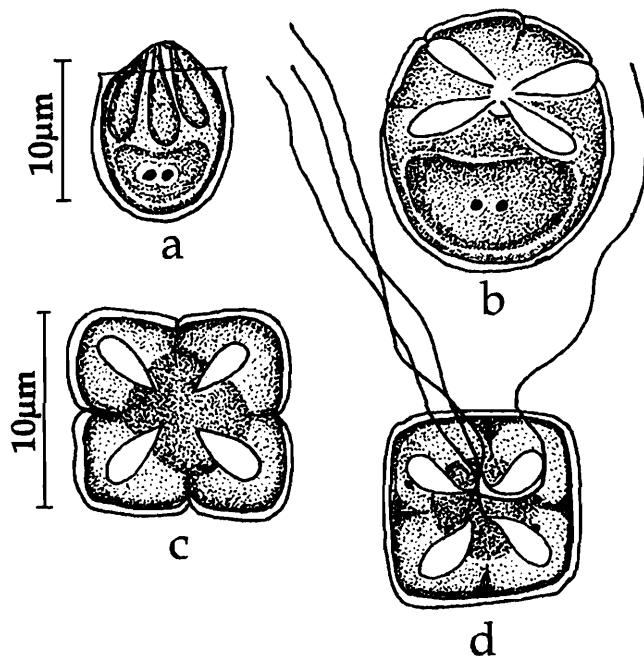


Fig. 277. *Kudoa sagarica* : a. Fresh spore sutural view, b. Spore apical view, c. Spore valvular view, d. Spore with extruded polar filament

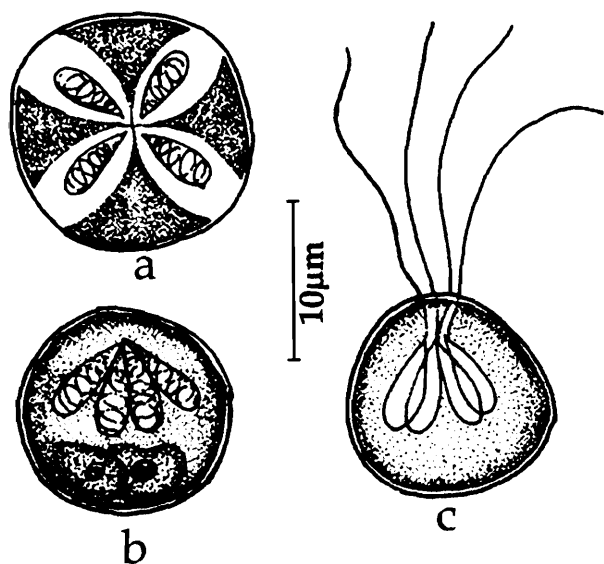


Fig. 278. *Kudoa sphaeraeni* : a. Fresh spore apical view, b. Spore stained with Giemsa, c. Spore with extruded polar filament

279. *Kudoa sphaeraeni* Narasimhamurti and

Kalavati, 1979c

(Fig. 278 a-c)

Diagnosis : Trophozoites small, spherical, opaque white, pedunculate 0.5-2.0 mm in size; spore quadrate in polar view, triangular in valvular view, broader than long; valves thin, smooth, transparent; sutural line very faint; polar capsules 4, club-shaped, equal; polar filament forming 7 coils while inside the capsule; long and thin when fully extended; 2 filaments straight and 2 coiled; 2 sporoplasms closely placed, bean-shaped.

Size : Spore length 9.0-10.2 (9.4) μm , width 9.5-10.5 (9.8) μm , thickness 9.5-10.5 (10.8) μm ; polar capsule length 3.0-4.2 (3.6) μm , width 1.0-1.6 (1.42) μm ; polar filament length 20-28.0 (26.8) μm .

Host : *Sphyraena jello*; *site of infection* : muscles; *pathogenicity* : not apparent.

Distribution : India : Andhra Pradesh (Bheeminipatnam and Visakhapatnam fish-landing centres, Visakhapatnam district).

280. *Kudoa tachysuræ* Sarkar and Mazumdar, 1983a
(Fig. 279 a-b)

Diagnosis : Spore coelozoic, small, thin-walled; shell valves comprising of four indistinct quadrants, two quadrants longitudinally arranged having large polar capsules than the other two horizontal ones; edges highly convex, almost round unlike flat and parallel edges of the horizontal quadrants, forming four notches at their meeting points; spore triangular in lateral view; polar capsule pyriform, convergent, with coils of polar filament inside; sporoplasm small, finely granular located in the largest quadrant.

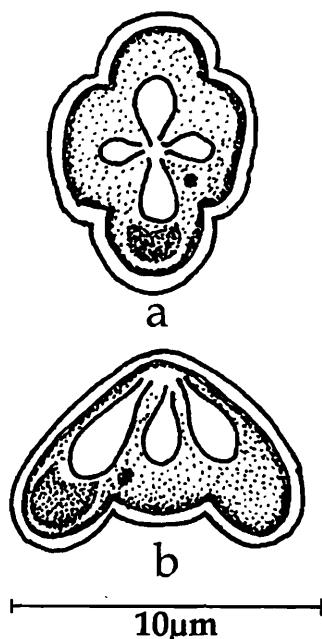


Fig. 279. *Kudoa tachysuræ* : a. Fresh spore valvular view, b. Spore side view

Size : Spore length 4.50-6.0 (4.87) μm , width 7.0-9.0 (7.75) μm , thickness 5.0 -6.5 (5.5); polar capsule (largest) length 3.0-4.0 (3.25) μm , width 2.0-3.0 (2.45) μm ; polar capsule (smallest) length 1.0-1.5 (1.45) μm , width 1.0-1.5 (1.4) μm .

Host : *Tachysurus tenuispinis* (Day); *site of infection* : gall bladder; *pathogenicity* : not apparent.

Distribution : India : West Bengal (Coast, Bay of Bengal).

281. *Kudoa tetraspora* Narasimhamurti and Kalavati, 1979b
(Fig. 280 a-c)

Diagnosis : Trophozoites translucent, white, oval or spherical, 0.3-1.5 mm in size; di- or tetrasporous; spores quadrate in polar view, club-shaped with deep notches in valvular view, triangular with rounded corners and bluntly pointed anterior end in lateral view; shell valves delicate, smooth, equal; sutural line faint; polar capsules 4, sub terminal, equal, club-shaped; polar filament making 3-4 coils while inside the capsule;

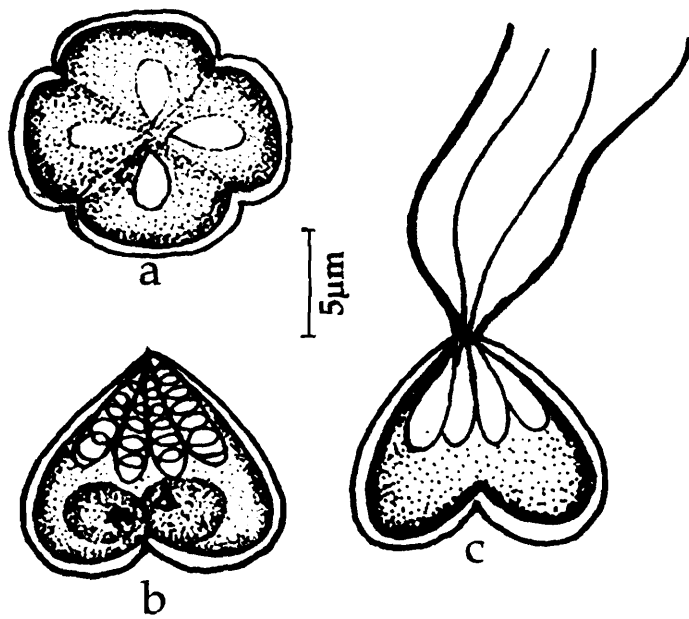


Fig. 280. *Kudoa tetraspora* : a. Fresh spore apical view, b. spore stained with Giemsa, c. spore with extruded polar filament

polar filaments short and varying in thickness when extruded; two uninucleate sporoplasms located in juxtaposition, oval in shape.

Size : Spore length 8.0–11.0 (9.0) μm , width 8.0–12.0 (9.0) μm ; polar capsule length 3.4–4.0 (3.8) μm , width 1.5–1.8 (1.68) μm ; polar filament length 10.0–12.0 μm .

Host : *Mugil cephalus*; *site of infection* : brain and optic lobes; *pathogenicity* : not apparent.

Distribution : India : Andhra Pradesh (Fishing market, Visakhapatnam).

282. *Kudoa valamugili* Kalavati and Anuradha, 1993 (Fig. 281 a-d)

Diagnosis : Trophozoites opaque, white, spherical, 0.45–0.65 mm enclosed in a thin connective tissue layer; disporous; spores quadrate, club-shaped with deep notches in valvular view, triangular with broad base and pointed anterior end in lateral view; shell valves thick, smooth, unequal; one valve large with rounded end; sutural line faint, indistinct; polar capsules 4, subterminal, pyriform, unequal; polar filament making 3–4 coils while inside the capsule; two uninucleate sporoplasms, one enveloping the other, in larger valve.

Size : Spore length 5.2–6.6 (5.6) μm , width 4.3–5.6 (4.7), thickness 5.0–5.4 (5.3) μm ; polar capsule

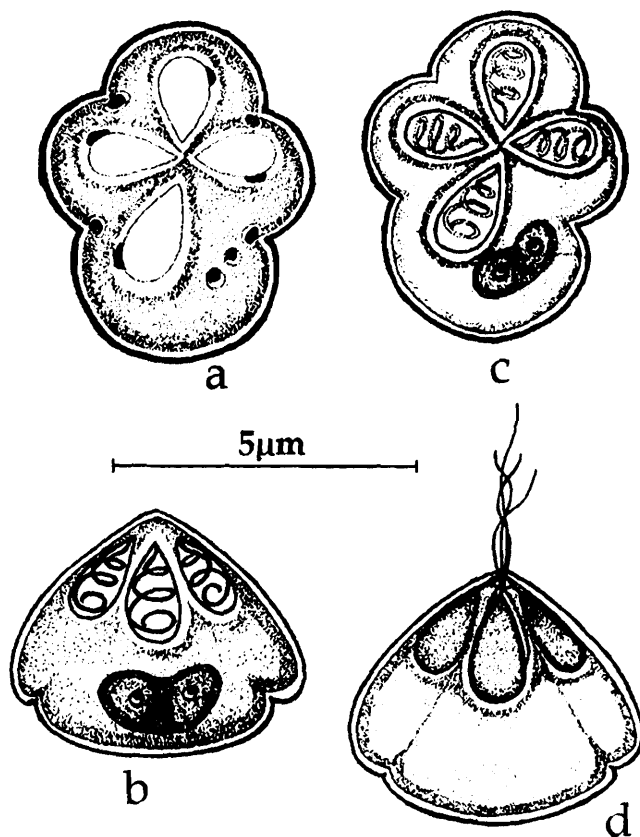


Fig. 281. *Kudoa valamugili* : a. Fresh spore valvular view, b & c. Spores stained with Giemsa, d. Spore with extruded polar filament

(large) length 3.0-3.8 (3.2) μm , width 1.6-2.0 (1.8) μm ; polar capsule (small) length 2.0-3.2 (2.4) μm , width 1.2-1.6 (1.4) μm .

Host : *Valamugil cunnessius*; *site of infection* : muscles of the intestine; *pathogenicity* : not apparent.

Distribution : India : Andhra Pradesh (Visakhapatnam harbour).

8. DISEASE AND PATHOLOGY

Myxozoan parasites are usually coelozoic or histozoic in nature and initially cause disturbance in the infected organ or tissue. This may or may not be accompanied by functional interruption. Many histozoic species form large plasmodia which together with their connective tissue wall appear as macroscopically visible 'cysts' There is often little, if any, tissue response to the cyst beyond the formation of connective tissue wall (Lom, 1969). In such cases tissue damage and inflammation when present is usually minimal and localised. Extensive lesions are rare. Light or moderate infections do not cause any apparent damage or clinical disease. Such latent infections are generally referred to as myxosporidiasis, while the manifestations of the disease condition is referred to as myxosporidiosis. Clinical manifestations caused by a specific genus, namely, *Myxobolus* are referred to as myxoboliosis, *Ceratomyxa*, ceratomyxiosis, *Thelohanellus*, thelohanellosis etc. Coelozoic myxosporeans usually tend to be non-pathogenic. Heavy infections, however, may cause blockage, dilatation and degenerative changes or inflammation of the infected ducts or tubules.

Myxosporidians (= myxosporeans) that have been reported to cause disease and death are species that infect vital organs like gills, brain, heart and skeletal system. They evoke prominent inflammatory reactions. In general, lesions caused by histozoic myxozoa develop in a 2 phase process (Dyková and Lom, 1978). In the first phase there is tissue displacement, atrophy and occasional hyperplasia associated with extensive growth of the parasites. In the second phase there is granulomatous inflammation associated with maturation of spores and rupture of the cyst. Extensive investigations have been carried elsewhere on the diseases caused by myxozoan infections and associated pathology. Ray (1933) reported that infection of *Ceratomyxa* in *Gobioides rubicundus* proved fatal under laboratory conditions. Chakravarty (1939) observed mortality among fishes infected with myxosporidian parasites and noted that the fishes showing severe myxosporidian infection were greatly emaciated and reduced in weight, and occurred when infection was heavy. But in India despite several reports of the occurrence of disease caused by myxosporidians (brain myxoboliosis in *Labeo rohita*, Das *et al.*, 1988a; and gill and renal myxoboliosis in 15day old fry of *Catla catla*, Mohan and Shankar. 1995), studies dealing with pathology remain few and fragmentary. Many taxonomic descriptions do not record information on pathology. Absences of macroscopic visible symptoms, in spite of records of mortalities perhaps lead to this lapse. Nevertheless the available information from Indian species and the specific lesions caused by them in different organs of the host is briefly discussed hereunder with reference to infected organ or tissue (Plate 1-5).

Gut and gall bladder

The bile ducts and gall bladder are the most common sites of infection by coelozoic species belonging to the genera *Leptotheca*, *Ceratomyxa*, *Zschokkella*, *Myxidium* and *Chloromyxum*. Many species do not exhibit any apparent pathogenicity and remain quiescent for a long time. Some species, however, are reported to be pathogenic. For example, heavy infection with *Zschokkella* sp., in *Tachysurus arius* caused dilatation of the hepatic ducts and eventual pericholangitis (Vaidehi, 1992 unpublished). *Chloromyxum tripathi* has been reported to cause hypertrophy and damage of the gall bladder epithelium and blocking of the bile duct leading to liver disease and jaundice in *Therapon jarbua* (Kalavati and Narasimhamurti, 1984b). *Ceratomyxa kudoii* causes hepatitis, hardening and discolouration of the gall bladder and bile juice in the mullet *Valamugil cunnesius* (Kalavati and Anuradha, 1993). *Sphaeromyxa therapani* in *Therapon jarbua* (Forsk.), *Myxidium papernae* in *Liza macrolepis* showed hypertrophy and distension of the gall bladder, discoloured bile with agglutinated granules and frayed epithelium (Kalavati and Vaidehi, 1991b; Padma Dorothy and Kalavati, 1992a). Padma Dorothy and Kalavati, (1994) noticed hypertrophy and discolouration of the gall bladder, sinusoidal dilatation associated with enlargement of hepatic ducts and accumulation of mononuclear leucocytes and aggregates of bile salts in *Liza macrolepis* infected with *Davisia murtii*. Although several species of *Ceratomyxa* are reported from gall bladder of marine fishes, there is no record of pathogenicity.

Myxozoan cysts are frequently found attached to gut wall and peritoneum. They do not seem to induce any host response except for the formation of a collagenous wall around the trophozoites. Anuradha (1991) noticed multifocal degeneration of intestinal epithelium, excess secretion of mucus when infected with *Sphaerospora mayi*.

Gills

Gill myxosporiosis is most widely distributed in many states in India being common among carps, catfishes and mullets. Several species of *Myxobolus*, *Henneguya* and *Unicuada* are reported from these hosts in West Bengal, Andhra Pradesh, Orissa and Kerala. Heavy infections by myxozoans in the gills often cause mortality. Infections of the gills could be intralamellar or interlamellar. Intralamellar form, *Henneguya waltirensis* caused heavy mortality in *Channa punctata* in Andhra Pradesh in 1978 -79 (Kalavati and Narasimhamurti, 1984c). During early stages the parasite develops among the basal cells causing severe epithelial cell hypertrophy and vacuolisation. When under heavy infection the damage was associated with reduction in functional gill surface. Degenerative changes are more severe and are associated with accumulation of macrophages and haemorrhages in the later stages. There was no specific host response. *Myxobolus sophorae* (Jayasri, 1982) in *Puntius sophore* and *Myxobolus* sp. in carp *Catla catla* (Lakshminarayana, 1988; Mohan and Shanker, 1995) showed similar lesions and significant loss of respiratory surface due to intralamellar branchial forms. Mohan and Shanker (op.cit) also observed necrosis and blockage of branchial micro

circulation. An inflammatory gill disease is caused by interlamellar *Myxobolus sphaeralis* in the mullet, *Liza macrolepis* (Padma Dorthy and Kalavati, 1992b). The lesions are characterised by diffuse perichondrial granulomatous inflammation, surrounding the developing parasite. Host response included hypertrophy and cellular disintegration in tissue around the growing trophozoite. Necrosis of lamellar epithelium is also seen in the case of *Myxobolus meglitschus*. Qadri (1970) noticed obstruction of blood flow in *Notopterus notopterus* infected with *H. ganapatii*.

Skeletal system

One of the wide spread and serious disease of salmonoids caused by *Myxobolus cerebralis* is 'Whirling disease'. The parasite invades cartilage and the site of infection determines the symptoms of the disease. Destruction of cartilage of the auditory capsule and semicircular canals results in disturbance of equilibrium. Fish makes small rotatory movements in vertical direction, rapid convulsive somersaults characteristic of the disease. Invasion of other parts results in deformities in skull, jaw bone, curvature of the caudal part of the spine etc. The parasite is known to cause necrosis, chronic granulomatous inflammation and fibrosis of cartilage (Halliday, 1974). The disease is wide spread in France, Germany, Italy, Poland and USA. *Myxobolus cartilaginis* is another species that localises in cartilage of head and gill arches. The species induces only little histopathological changes in the first 7 weeks. In about 4-5 months epitheloid granulomas appear around the spore masses, followed by liquefaction of the cartilage. Ram *et al.* (1984) reported occurrence of both the species *Myxobolus cerebralis* and *Myxobolus cartilaginis* associated with ulcerative syndrome in major and minor carps and murels. Details of the disease are, however, not available. Das *et al.*, (1988a) observed brain myxoboliasis caused by *Myxobolus encephaliticus* in *Labeo bata* collected in Cuttack, Orissa. The infection is seen in optic lobes, cerebellum, telencephalon and medulla oblongata. When present in blood vessels they hinder blood flow resulting in perivascular oedema and erythrocyte diapedesis. Multifocal degeneration and necrosis of cartilaginous skeleton of the gill ray/ operculum in *Mugil cephalus* infected with *Myxobolus spinocurvatura*. The species is reported by Anuradha (1991) from mullets inhabiting the harbour waters of Visakhapatnam.

Kidney

Renal myxosporiosis caused by *Myxobolus* sp. resulting in mortality in carp fry was reported by Mohan and Shanker (1995) in fish farms in Karnataka. The developing cysts damage the interstitial tissue and significantly reduce the functional renal tubules. Necrotic cellular and tissue damage results in significant decrease in osmoregulatory, excretory and haemopoietic deficiencies (Mohan and Shanker, 1995). Nephrosis and obstruction of ureter caused by *Neoparvicapsula monoalata* is reported by Sarkar (1999b) in the sciaenid, *Microspinosa cuja*. *Neothelohanellus catlae* induced hypertrophy of kidney and visible enlargement of abdomen. No histological observations

were made on this species. Significant decrease in blood glucose levels (32.6 ± 3.2 mg/100ml as against 62.2 ± 3.0 mg/100ml in healthy fish) was noticed in *Heteropneustes fossilis* infected with *Myxobolus fossilii*. The impact was amplified when there is concomitant infection with *Trypanosoma karelensis* (Gupta *et al.*, 2001).

Muscle tissue

Myxosporiosis of the muscle is generally considered significant since it reduces the economic value of the fish considerably. Studies elsewhere have shown many species of *Kudoa* result in lysis of the muscle tissue. In India although as many as 10 species of *Kudoa* were reported their apparent pathogenicity was never noticed. The only report of muscle disintegration was in the case of *Unicapsula chirocentrusi* infecting the musculature of *Chirocentrus dorab* (Sarkar, 1984b).

Skin

Dermal lesions do not cause clinical disease but are important because they may produce unsightly macroscopic cysts/ulcers that decrease the marketability of the fish. Examples of species that form tumor like out-growths are *Henneguya rubicundi* in *Gobioides rubicundus* (Haldar and Mukherjee, 1985), *Myxobolus esomi* from *Esomus* sp. (Kalavati and Narasimhamurti, 1984a) and *Myxobolus rohita* (Haldar *et al.*, 1983). Haldar and Mukherjee (1985) observed that the tumors were more concentrated on dorsal and ventral fins, disfigured them and interfered with movements of the body. In the case of *Unicauda aplocheili* skin was ulcerated with sloughed pockets and spores accumulated in the pockets underneath the scales (Kalavati *et al.*, 1992).

Heart

Cardiac myxosporiosis is rather rare. But the pathogenic effects appear to be more severe. For example, *Henneguya otolithi* parasitic in bulbous arteriosus of species of *Otolithus* results in corrosion and destruction of the heart muscle. Initially plasmodia grow in the muscle fibres of the wall separating them and later fibres in contact with the trophozoite degenerate completely causing considerable destruction. When under heavy infection, there is hyaline degeneration and yellow granulation. The host response included formation of active fibroblasts and layers of connective tissue around the growing parasite. Penetration of the connective tissue into the cyst sometimes results in parasite mortality (Ganapati, 1936, 1941). Another example of cardiac myxosporiosis is *Myxobolus etropli* infecting the bulbous arteriosus of *Etroplus suratensis*. There are elevated foci on the bulbous arteriosus. In heavily infected fish the organ is grossly enlarged and distorted. Infection foci are reported in the advential and medial layers. Metastasis throughout, necrosis of elastic fibres and degeneration of functional tissue was reported. (Rajendran *et al.*, 1998)

Other organs

Another interesting example is that of *Palliatius indicus* causing neoplasia in *Liza macrolepis* (Padma Dorothy and Kalavati, 1998). The parasite infected pancreas affecting mostly the 'β' cells in Islets of Langerhans. The authors observed that there is loss of body weight among infected individuals evidently due to impairment of glucose metabolism. Exophthalmia and ovotestes condition was reported in *Channa punctatus* infected with *Myxobolus* sp. and concurrent infection with *Ichthyophonus*. (Malhotra *et al.*, 1978).

It is evident that the pathogenic influence of myxozoans on host body is variable. It neither depends on the extent of infection nor on the site of infection. Host responses appear to be species specific and also vary from fish to fish. In India, there is significant paucity of information on pathology and disease albeit frequent occurrence of the parasites in a variety of fish. Future studies should focus more on the histological and biochemical changes due to infections both at cellular and tissue levels and a re-examination of already described species seems to be necessary to evaluate their impact.

Zoonosis in myxozoa

Till recently myxosporidians in food fishes are not considered to be of human health risk because they have not been shown to infect human beings. The reports of occurrence of spores of *Henneguya salmanicola* (McClelland *et al.*, 1997) parasitic in salmonoid fishes in Canada, *Myxobolus plectroplites* (Boreham *et al.*, 1998) parasitic in freshwater fish *Plectroplites ambiguus* in Australia and *Myxobolus* sp. (Moncada *et al.*, 2001) in Colombia in human stool samples of patients with gastrointestinal disturbance suggest that this aspect requires serious consideration in India.

Immunity

Most of the myxozoan diseases that resulted in mortality are reported in fishes reared in captivity. With the recent growth in aquaculture industries these diseases have become more prevalent. The absence of significant inflammation in fish with these infections may also be due to lack of antibody response to these parasites. Some species, for example, *Myxobolus cerebralis* from salmonoids and *Myxobolus* sp. from eels are known to mimic host antigens to avoid host detection (Hallyday, 1974; McArthur and Sengupta, 1982). In an experimental study, Siau (1980) and McArthur and Sengupta (1982) did not find any antibody formation when they challenged mullets with antigens of *M. exiguus*. Antibodies were, however, detected in trout infected with *M. cerebralis* (Griffin and Davis, 1978). Species of *Kudoa* that infect somatic musculature of estuarine and marine fishes seem to invoke antibody of the IgG subclass (Martinez de velasco *et al.*, 2002). Such investigations have not been carried out with regard to infections in Indian fishes.

Host-Parasite interactions

Prevalence of myxosporean infections were related to environmental factors such as water temperature and salinity, host populations density, age, feeding, migratory, breeding and spawning habits besides species' specific susceptibility and other biological factors. Several reports indicate high degree of seasonal changes in myxosporean prevalence. For example, vegetative stages of *Myxidium leibekuhni* were found in winter whereas mature spores are noticed during early summer (Schulman, 1966). In case of *Myxidium incurvum* and *Ceratomyxa* sp. intensity was high during summer and low during winter (Noble, 1957). In India, high prevalence of myxozoan parasites was reported during August to January when the ambient temperature was < 25°C. (Basu, 1950; Das *et al.*, 1989; Seenappa and Manohar, 1980c; Narasimhamurti and Kalavati, 1984; Basu and Haldar, 2003). It is presumed that temperature is an important environmental factor in the infection dynamics (Mukherji, 1990). The feature appeared to be common in those species having cysts on exposed surfaces of its hosts, namely, gills and scales (Cone, 1994; Nie, 1996; Molnar, 1998; Flores and Vozzi, 2001). Those species which infect internal organs such as muscles, cartilage and nerves may not have such cycles. Gall bladder inhabiting species seem to be an exception since the spores can reach water easily through intestine.

It is generally accepted that most myxozoans infect their hosts while they are still young and usually infection reaches maximum in the mature fish. In *Myxobolus pavloskii* infecting silver carp, *Hypophthalmichthys molitrix* (Lucky, 1978), *M. osburni* in pumpkin seed, *Lepomis gibbosus* (Cone and Anderson, 1977b); *Kudoa* sp. in Peruvian hake, *Merluccius gayi* (Okade *et al.*, 1981) and locally *Myxobolus* sp. in *Liza tade* (Rajagopalasamy and Natarajan, 1987), low prevalence was noticed in smaller (young) fish. On the contrary, Joy *et al.* (1978), Pellitero *et al.* (1983) reported decrease in prevalence with age in the chubb, *Leuciscus cephalus cabeda*, in the barbell, *Barbus barbus* infected with *Chloromyxum* sp. and *Myxidium carinae* respectively. Evidently among myxosporean infections preference to age of the host is species specific. Padma Dorothy (1990, Unpublished) made similar observations with regard to prevalence of myxozoan infections in *Liza macrolepis*.

In India, reports of myxozoans infestations were more among freshwater fishes than in estuarine or marine fishes. So far a total of 282 species are reported from Indian fishes of which 212 are from freshwater fishes, 33 from estuarine and 37 are from marine fishes. Among the marine fishes 30 species are from fishes of Bay of Bengal, 5 from Andaman sea and 2 from Indian ocean (non specified). There appears a big lacuna of observations from the fishes of Arabian Sea (West coast of India)

In recent years there is considerable upsurge in the cultivation of carps and other freshwater fish in India. New aquaculture practices such as intensive and polyculture systems have been widely introduced. Growing more fish in a limited area often resulted in increased disease outbreaks. Overall, in culture ponds, gill myxoboliosis is

most widely distributed in many states in India, being found in all three species of carps. Heavy mortality is reported in Andhra Pradesh during November – December 2000. Pathogenic effects included hypertrophy of secondary gill lamellae and atrophy of branchial arches. On the contrary, gill sphaerosporiosis appeared localized. Necrosis of gills is common, mortality being relatively high (48-56%). Renal myxosporiosis caused by *Neothelohaenellus* in fingerlings of *C. mrigala* is found only in West Bengal. Dermal lesions by *Myxobolus* and *Thelohaenellus* were relatively common in the states of Andhra Pradesh and Karnataka. Jaundice in *C. catla* caused by *Chloromyxum* sp. often resulted in high (80%) mortality in juvenile fish. As many as 9 species of *Thelohaenellus* are reported from Deccan plateau causing gill and dermal lesions with subdued virulence and pathogenicity.

Three major carps, namely, *Labeo rohita*, *Cirrhina mrigala* and *Catla catla*, are extensively cultured in some parts in India. As many as 48 species of myxozoans represented by 8 genera, namely, *Myxobolus* (18 species), *Thelohaenellus* (18 species), *Neothelohaenellus* (2 species), *Myxidium* (2 species), *Chloromyxum*, *Sphaerospora*, *Gyrospora* and *Lomosporus* (1 species each) are known. Of these, 9 species are reported severely pathogenic. Among the species examined, *L. rohita* was most susceptible (31 species of myxozoa) followed by *Cirrhina mrigala* (12 species) and *C. catla* (7 species). Parasite virulence was, however, greater in *C. catla* with mortality up to 82-90%. In general, mortality was low to moderate (2-22%) in *C. mrigala* and *L. rohita*. In *C. mrigala*, prevalence of infection was perceptibly high in fingerlings (87.5%) (Gopalakrishnan, 1968). Hybrid carps are more susceptible to myxozoan infestation. In many instances they prove to be more susceptible to pathogenic effects leading to heavy mortality in culture systems (Basu and Haldar, 1998; 2003 c).

Host, Organ and tissue specificity

The host specificity of different genera and species of myxosporeans is different, but is always restricted to a well definable circle of related hosts (Molnar, 1994). While certain species have very narrow host range and infect only a single species of fish host, several species infect a wide range hosts belonging to different families and orders invading many organs and tissues. Such examples are more apparent among marine fishes. For example, *Myxidium incurvatum*, *M. lieberkunhi*, *M. bergense* etc. infecting more than 10 species of hosts belonging to 6 families. Parasites of more specialized tissues such as cartilage, nervous system, renal organs reveal comparatively a narrow specificity, viz., *M. cerbralis* and *M. neurobius* of salmonoids.

Organ specificity is more elevated among myxozoa. Most of the species that are seen in gall bladder are not found elsewhere in the body. So is the case with kidney, muscle or cartilage inhabiting forms. Organ specificity depends primarily on the cell type necessary for the development of the particular species. In India, high degree of organ specificity is noticed in myxozoans infecting mullets, *Mugil cephalus* and *Liza macrolepis* (Padma Dorothy, 1990; Anuradha, 1991).

Myxosporeans are highly tissue specific. They begin the development, within the basic tissue, only in a single specific cell type (Molnar, 1994), for instance epithelial cells of the gill, liver cells, compact connective tissue or perichondrial cells. Consequently their development is consistently restricted to a specific tissue such as epithelial, muscle and nervous, cartilaginous, bone and connective tissue and the organ associated with it.

Myxozoa as biological tags

Several investigations have been carried out on the potential use of parasites as biological tags for understanding the origin and migration of marine fishes. They seem to have several advantages over conventional mark and recapture methods. Lester (1990), Moser (1991), Mackenzie (1987) and Mackenzie and Abaunza (1998) summarised these studies and listed guidelines for using parasites as biological tags for stock identification, seasonal migration patterns, recruitment and pollution studies. Mackenzie (1987) has identified 4 characters necessary for use as 'Tag parasites' They are: (1) geographic variation in prevalence or abundance, (2) easily detectable, (3) longevity of infection and (4) not causing any selective mortality or behavioural changes. Many myxozoans appear to meet these criteria. It is well documented that gall bladder myxosporeans, namely, species of *Myxidium*, *Ceratomyxa*, *Sphaeromyxa* and *Leptotheca* were all used as successful tags for stock identification in gadids, namely, Whiting, *Merlangius merlangius* and haddock, *Melanogrammus aeglefinni* populations in British and Feroe waters; cod, *Gadus morua* populations off Newfoundland and northern Norway and Alaskan and Canadian populations of sockeye Salomon, *Onchorhynchus nerka* (Kabata, 1963, 1967; Moles and Short 1989; Khan and Tuck, 1995; Larsen *et al.*, 1997; Mackenzie *et al.*, 2005). *Alatospora serenum* and *A. solmoni* were found to be potentially useful as tag parasites for stock identification of Atlantic horse mackerel, *Trachurus trachurus* (L.) in the north east Atlantic Ocean and Mediterranean Sea (Campbell, 2005).

Myxozoans are highly sensitive to environment. Their use as indicators of aquatic pollution is also significant. Bucher *et al.* (1992) and Marcogliese and Cone (2001) found that levels of infection were significantly high in organically enriched water bodies. On the contrary, prevalence of infection decreases perceptibly when contaminated with PCBs and PAHs (Khan, 1998, 1999).

9. DIAGNOSIS, CONTROL AND TREATMENT

Presumptive diagnosis of myxosporean infections can be based on clinical signs. Many histozoic species form macroscopic visible cysts. In addition to detection by visual examination, ultrasound imaging has been used to detect cysts of *Henneguya salmonicola* in fresh fish (Boyce, 1985). However, confirmation of infection can be made only on microscopic detection and identification of the spores. Species identification is carried out based on spore morphometrics in fresh preparations because spore shape and size is often distorted by preservatives (Parker and Warner, 1970; Kudo, 1921). In case of diffused light infections diagnosis is aided, by concentration of spores. Most of the techniques in use for concentration have been developed for detection of *Myxobolus cerebralis* spores. The same can be used for other species. Initially, *Myxobolus cerebralis* spores are released from the cartilage by maceration and homogenization which is followed by digestion with the enzymes such as pepsin and trypsin (Markiw and Wolf, 1974 a, b). Spores once released from tissue by digestion can be concentrated by filtration followed by centrifugation in a plankton centrifuge (O'Grodnick, 1975; Prashaer *et al.*, 1971; Markiw and Wolf, 1980) or by centrifugation in polyethylene glycol (PEG) 4000, PEG 6000 or dextran T 500 solutions (Kozel *et al.*, 1980). In species that infect soft tissues (ex. *Myxobolus arcticus*) spores are released by digestion with pepsin and HCl (Bailey and Margolis, 1986) and concentrated by centrifugation in a 55% aqueous dextrose solution (Markiw and Wolf, 1974b). Staining the spores with Silver nitrate facilitates detection of spores after concentration (Wolf and Markiw, 1979). It is often found difficult to differentiate species solely based on spore morphometrics and structure since in some genera (e.g., *Myxobolus*, *Thelohanellus*, *Myxidium* etc.), they tend to be closer. Therefore, other criteria, such as tissue location, pathological changes, and species of the host infected, and geographic location of the infected fish should be taken into consideration for species identification.

Trophozoite stages of the parasite rarely induce disease (e.g., proliferative kidney disease, hamburger gill disease, ceratomyxosis), and diagnosis of these infections are often based on the specific pathological changes in the tissue, morphological characteristics and location of the trophozoites in the tissues. Serologic techniques have been developed to identify some of these species. (*viz.*, *Myxobolus cerebralis* and *Ceratomyxa shasta*). Markiw and Wolf (1978) developed a direct fluorescent antibody technique for the identification of *M. cerebralis* spores. Bartholomew *et al.* (1989 b) developed monoclonal antisera to prespore stages and polyclonal antiserum to spores of *C. shasta*. The monoclonal antibodies to prespore stages do not react with spores, whereas the polyclonal antiserum to spores reacted with both spores and prespore stages. Therefore, the monoclonal antibody was used to detect early developmental stages of the parasite in fish (Bartholomew, 1989a). Intestinal lavage has also been used to obtain *C. shasta* for diagnostic examination from living fish (Coley *et al.*, 1983).

Guidelines for identification

Lom and Arthur (1989) recommended several guidelines to aid in identifying and describing myxosporean parasites. They have summarized the criteria provided by previous authors and added some new important features to these guidelines. They listed characteristics that are recommended and those that are indispensable for species identification. The following are the criteria provided by Lom and Arthur (1989) :

1. Samples

1. Samples should preferably be fresh. In an emergency, samples may be fixed in buffered 10% formalin or frozen and examined soon after they thaw. Never fix samples in alcohol.

2. Host

1. The scientific name of the host, its age, and geographic location, the prevalence of infection, the tissue or organ infected and pathological changes should all be recorded.

3. Vegetative stages of the parasite

1. Note shape, size, structure and, number of spores present, if any.

4. Spore

1. Note size, shape and presence of sutural ridges.
2. Prepare high quality line drawings and, when possible, microphotographs.
3. Note presence of spore projections, caudal appendages, ribs, ridges or striae.
4. Note number, shape, size and angle of polar capsules, size of the angles in relation to spore length.
5. Note number and arrangement of coils of the polar filaments and position of capsule opening.
6. Note presence/absence of membranaceous or mucous envelope around spore.
7. Note presence/absence and shape of iodophilous vacuole.
8. Note position and number (1 or 2) of sporoplasms in spore cavity.
9. Note variability in spore shape and size.

Control and Treatment

Most attempts at controlling myxosporean diseases have been directed toward avoiding infection. This has been done by disinfection of holding facilities or incoming water, by altering water temperature, and by using resistant strains of fish. Calcium hydroxide, calcium oxide, calcium cyanamide, Roccal (alkyl dimethyl benzyl ammonium chloride), potassium hydroxide and chlorine have been used to kill the spores of *Myxobolus cerebralis* (Hoffman and Hoffman, 1972; Hoffman and Putz, 1969). The transmission of the disease was eliminated or reduced in field trials by treating mud from infected ponds with calcium oxide (Hoffman and Hoffman, 1972) or chlorine or by thorough air drying (Hoffman and O'Grodnick, 1977). Bauer *et al.* (1973) recommended drying of ponds to control several myxosporean diseases of carp. Seenepa and Manohar (1983) reported that treatment of mud with calcium hydroxide effectively controlled *Myxobolus vanivilasae* in ponds in Karnataka. Myxosporean spores are resistant and can tolerate extended drying and freezing as well (Long and Meglitsch, 1969; Hoffman and Putz, 1969, 1971). Periodic reexamination is recommended. Hoffman (1974, 1975) reported that infectious stage of *M. cerebralis* could be eliminated from water by ultraviolet radiation. The water is irradiated as it enters the tank. Irradiation and chlorination of the water has also been used to control *Ceratomyxa shasta* (Bedell, 1971; Leith and Moore, 1967; Bower and Margolis, 1985; Bedell, 1971; Sanders, *et al.*, 1972). Some myxosporean diseases can be controlled by alterations in husbandry. The incidence of proliferative kidney disease can be minimized by not transferring trout to infectious water until mid-summer or fall (Ferguson and Ball, 1979; Clifton-Hadley, *et al.*, 1986). The efficacy of late transfer is probably due to the fact that by the time the parasite has established itself in the fish the water has become too cold for it to induce disease (Ferguson, 1981). *Ceratomyxa shasta* infections can be avoided by maintaining fish below 10°C (Schafer, 1968). However, if the fish are already infected, the disease will progress even at lower temperature (6.7°C) but at a slow rate (Udey *et al.*, 1975). Improved nutrition of fish and concomitant intensification of growth, decrease invasion by parasites and lowers their pathogenicity (Dogel and Bauer, 1955). In the Indian context, Narasimhamurti and Kalavati (1984) reported low prevalence of infections during winter months when the ambient temperature was minimum and high during summer. They also noticed that tolerance of the host *Channa punctata* to environmental stresses such as low oxygen levels reduced with gill infections. Myxosporidean spores also cannot survive in high pH and turbidity (Mitchell, 1976).

There are no effective chemotherapeutic agents for control of myxosporiosis. Considering the importance of myxosporean disease in economically important fish, relatively little has been done on development of chemotherapeutics. Scolari (1954) and Bauer (1959), however, reported partial success by treating fish suffering from whirling disease with Acetarsol (Stovarsol), but Alderman (1986) was unable to duplicate their successes. Taylor *et al.* (1973) reported that there were fewer spores of *M. cerebralis*

in fish fed with furazolidone than in control fish. Mehlhorn *et al.*, (1988) reported that toltrazuril (triasinone), an anticoccidial compound, is effective against various protozoa, including myxosporeans (Quoted from Moser and Kent, 1994). Alderman (1986) found >75% reduction in spore numbers and a marked reduction in associated pathological changes in fish fed with proguanil. Sphaerosporosis in carp (Molnar *et al.*, 1987), whirling disease caused by *M. cerebralis* in salmonoids (El Matbouli and Hoffman, 1991) and PKX disease in chinook salmon (Hedrick *et al.*, 1988) have been controlled by feeding fumagillin DCH, an antibiotic. Fumagillin, however, is not efficacious against histozoic myxosporeans such as *Thelohanellus* and *Myxobolus* (Molnar *et al.*, 1987). Fumigillan at 3.95mg/500 g body weight per day for one month was recommended as the optimal dose for treatment and prevention of Thelohanellosis caused by *Thelohanellus kitauei* in *Cyprinus carpio nudus* (Rhee *et al.*, 1993) in Japan. Since Fumigillin is sparingly soluble in water, mode of application is through incorporation in feed. The drug has limited safety margin and is known to affect the erythropoietic system of the host (Rajendran, 2003).

In India, Sarkar (1946) advocated disinfecting the fry before planting them in rearing tanks. This can be done by a bath in Condy's Fluid ($\frac{1}{2}$ grain by weight of potassium permanganate per gallon of water) or weak solution of common salt (0.2 percent solution). Dey and Chandra (1994) suggested a traditional herbal mixture consisting of garlic and salt for treatment of myxoboliosis in carps. The mixture consisting of crude extract of garlic bulb at 1 ppm and salt at 10 ppm (10 kg and 100 kg /ha/m of water) was found effective in checking fish mortality, decomposing and breaking of parasitic cysts in the gills, inducing healing and regeneration of damaged gill tissue. In general, treatment for internal protozoa although not specifically for myxozoa, as suggested by Misra (1999) includes use of Dimetridazole 0.15% in food daily for 3 days or Enhalptin 0.2 % in food for 4 days or Furazolidone 1 ppm for 1 hr or 25 mg/kg body weight of fish per day for 14 days.

10. REFERENCES

- Alderman, D.J. 1986. Whirling disease chemotherapy. *Bull. Eur. Ass. Fish Pathol.*, **6** : 38-39.
- Anuradha, I. 1991. Myxosporidia of the common striped mullet, *Mugil cephalus*, Linn., from Visakhapatnam coast. Ph.D. Thesis (unpublished), Andhra University, India.
- Anuradha, I. and Kalavati, C. 1987. A new myxosporidian *Myxobilatus* sp. from the freshwater fish, *Clarius batrachus*. *National Seminar on freshwater Aquaculture in India*, 28-30th December. Abs. No. 4.7.
- Auerbach, M. 1910. Die sporenbildung von *Zschokkella* und dei system der Myxosporidien. *Zool. Anz.*, **35** : 240-256.
- Bailey, R.E., and Margolis, L. 1986. Comparison of parasite fauna of juvenile sockeye salmon *Onchorhynchus nerka* from southern British Columbian and Washington state lakes. *Can. J. Zool.*, **65** : 420-431.
- Bajpai, R.N. and Haldar, D.P. 1982a. A new myxosporidian, *Unicauda chaudhuryi* n. sp., (Myxozoa : Myxosporea) from the fish, *Ophicephalus punctatus* Bloch. *Riv. Parassitol.*, **43** (1) : 147-152.
- Bajpai, R.N. and Haldar, D.P. 1982b. Observations on a new species of *Unicauda* Davis, 1944 (Myxozoa : Myxosporea) from the teleost, *Rita rita* (Hamilton). *Arch. Protistenk.*, **125** : 79-86.
- Bajpai, R.N. and Haldar, D.P. 1982c. Observations on two myxosporidian parasites (Myxozoa : Myxosporea) from the gall bladder of freshwater fishes. *Arch. Protistenk.*, **125** : 129-136.
- Bajpai, R.N., Kundu, T.K. and Haldar, D.P. 1981. Observations on *Myxosoma magauddi* n. sp., (Myxosporea : Myxosomatidae) parasitic in the gill filaments of *Trichogaster fasciatus*. *Riv. Parassitol.*, **42** (3) : 343-350.
- Banerji, S.R. and Das, B.K. 1989-1990 (1993). Control of *Myxobolus* infestation in *Clarius magur*. *Matsya*, **15/16** : 202-204.
- Bartholomew, J.L., Rohovec, J.S. and Fryer, J.L. 1989a. Development, characterization and use of monoclonal and polyclonal antibodies against the myxosporean, *Ceratomyxa shasta*. *J. Protozool.*, **36** : 397-401.
- Bartholomew, J.L., Smith, C.E. Rohovec, J.S., and Fryer, J.L. 1989b. Characterisation of host response to the myxosporean parasite, *Ceratomyxa shasta* (Noble) by

- histology, scanning microscopy and immunological techniques. *J. Fish. Dis.*, **12** : 509-512.
- Basanquet, W.C. 1910. Brief notes on two myxosporidian organisms (*Pleistophora hippoglossoides* n. sp. and *Myxidium mackiei* n. sp.). *Zool. Anz.*, **35** : 434-438.
- Basu, S.P. 1950. Myxosporidian parasites of Indian carps, *L. bata* (Ham.), *Catla catla* (Ham.), *L. rohita* (Ham.), *C. mrigala* (Ham.), and their seasonal variations. *Proc. Indian Sci Congr.*, Part III, **37** : 239.
- Basu, S. and Haldar, D.P. 1998. Comparative study on prevalence of protozoan parasites in pure and hybrid carps. *Environment & Ecology*, **16** (3) : 584-587.
- Basu, S. and Haldar, D.P. 1999. *Thelohanellus bifurcata* n. sp., a new species of the genus *Thelohanellus* from hybrid carps and check list of the species of the genus described from Indian fishes. *Proc. Zool. Soc. Calcutta*, **52**(1) : 115-124.
- Basu, S. and Haldar, D.P. 2002a. *Myxobolus ophthalmusculata*, a new species of histozoic myxozoan (Myxozoa : Bivalvulida) from *Cirrhinus mrigala* (Hamilton). *Proc. Zool. Soc. Calcutta*, **55** (2) : 43-48.
- Basu, S. and Haldar, D.P. 2002b. Observations on three new species of *Myxobolus* Butschli, 1882 from Hybrid carps of West Bengal, India. *Indian J. Environ. & Ecoplan.*, **6** (3) : 629-640.
- Basu, S. and Haldar, D.P. 2003a. Three new species of *Myxobolus* Butschli, 1882 from different food fishes of West Bengal, India. *Acta. Protozool.*, **42** (2) : 245-251.
- Basu, S. and Haldar, D.P. 2003b. Observations on two new thelohanellid species (Myxozoa : Bivalvulida) from Indian major carps of West Bengal, India. *J. Parasit. Appl. Anim. Biol.*, **12** (1&2) : 15-24.
- Basu, S. and Haldar, D.P. 2003c. A comparative study on the prevalence of myxosporeans (Myxozoa : Bivalvulida) in pure and hybrid carps of West Bengal. *Ecol. Env. & Cons.*, **9** (2) : 147-159.
- Basu, S. and Haldar, D.P. 2004. Description of three new myxosporean species (Myxozoa : Myxosporea : Bivalvulida) of the genera *Myxobilatus* Davis, 1944 and *Myxobolus* Butschli, 1882. *Acta Protozool.*, **43** (2) : 337-343.
- Bauer, O.N. 1959. The ecology of parasites of freshwater fishes. *Izvest, Gosud. Nauchno-issled, Inst. ozern. Rechn. Ryb. Khoz.*, **49** : 3-215.
- Bauer, O.N., Mussellius, V.A., and Strelkov, Y.A. 1973. *Diseases of Pond fishes*. Keter Press, Jerusalem, pp. 218.

- Bedell, G.W. 1971. Eradicating *Ceratomyxa shasta* from infected water by chlorination and ultraviolet irradiation. *Prog. Fish Cult.*, **33** : 51-54.
- Bhatt, V.S. and Siddiqui, W.A. 1964. Four new species of myxosporidia from the Indian freshwater fish, *Ophicephalus punctatus* Bloch. *J. Protozool.*, **11** : 314-316.
- Boreham, R.E., Hendrick, S., O'Donoghue, P.J. and Stenzel, D.J. 1998. Incidental finding of *Myxobolus* spores (Protozoa : Myxozoa) in stool samples from patients with gastrointestinal symptoms. *J. Clin. Microbiol.*, **36** (12) : 3728-3730.
- Bower, S.M. and Margolis, L. 1985. Microfiltration and ultraviolet irradiation to eliminate *Ceratomyxa shasta* (Myxozoa : Myxosporea) a salmonoid pathogen from Fraser River water, British Columbia. *Can. Tech. Rep. Fish. Aquat. Sci.*, **1364** : p. 11.
- Boyce, N.P. 1985. Ultrasound imaging used to detect cysts of *Henneguya salmonicola* (Protozoa : Myxozoa) in the flesh of whole pacific salmon. *Can. J. Fish. Aquat. Sci.*, **42** : 1312-1314.
- Bucher, F., Hofer, R. and El-Matbouli, M. 1992. Prevalence and pathology of *Zschokkella nova* (Myxosporea) in the liver of bullhead, *Cottus gobio* from a polluted river. *Dis. Aquat. Organ.*, **14** : 137-143.
- *Bütschli, O. 1881. Beiträge zur Kenntnis der Fischsporospermien. *Ztschr. wiss. zool.*, **35** : 620.
- *Bütschli, O. 1882. 'Myxosporidia' In Bronn's *Klass. ordn., des tierreiches, protozoa vol. 1* : 590-603.
- Campbell, N. 2005. The myxosporean parasitofauna of the Atlantic horse mackerel, *Trachurus trachurus* (L.) in the North-East Atlantic Ocean and Mediterranean Sea. *Acta. Parasitologica*, **50** (2) : 97-101.
- Cavelier-Smith, T. 1993. Kingdom Protozoa and its 18 phyla. *Microbiological Review*, pp. 593-594.
- Cavelier-Smith, T. 1997. A revised six kingdom of life. *Biol. Rev.* **73** : 203-266.
- Chakravarty, M.M. 1938. Studies on myxosporidia from freshwater fishes of Bengal. *Proc. 23rd Indian Sci. Congr. Section IV, Zoology*, p.156.
- Chakravarty, M.M. 1939. Studies on myxosporidia from fishes of Bengal, with a note on myxosporidian infection in aquaria fishes. *Arch. Protistenk.* **92** : 169-178.
- Chakravarty, M.M. 1943. Studies on myxosporidia from the common food fishes of Bengal. *Proc. Indian Acad. Sci.*, **18** (2) B : 21-35.

- Chakravarty, M.M. and Basu, S.P. 1948. Observations on some myxosporideans parasitic in fishes with an account of nuclear cycles in one of them. *Proc. zool. Soc. Bengal*, **1** : 23-33.
- Chen, C.L. 1973. Illustrations of fish Pathogens in Hubei province. Peking. Science Publ. House. 456 pp.
- Choudhury, A. and Nandi, N.C. 1973. Studies on myxosporidian parasites (protozoa) from an estuarine gobiid fish of West Bengal. *Proc. Zool. Soc. Calcutta*, **26** (1) : 45-55.
- Clifton-Hadley, R.S., Richards, R.H. and Bucke, D. 1986. Proliferative kidney disease (PKX) in rainbow trout *Salmo gairdneri* : further observations on the effects of water temperature. *Aquaculture*, **55** : 165-171.
- Coley, T.C., Chacko, A.J. and Klontz, G.M. 1983. Development of a lavage technique for sampling *Ceratomyxa shasta* in adult salmonoids. *J. Fish. Dis.*, **6** : 317-319.
- Cone, D.K. 1994. Annual cycle of *Henneguya doori* (Myxosporea) parasitizing yellow perch (*Perca flavescens*). *J. Parasitol.*, **80** : 900-904.
- Cone, D.K. and Anderson, R.C. 1977b. Myxosporean parasites of pumpkinseed (*Lepomis gibbosus* L.) from Ontario. *J. Parasitol.*, **63** : 657-666.
- Cone, D.K. and Melendy, J.S. 2000. Infections of *Unicauda clavicauda* (Kudo, 1934) (Myxozoa) in the skin of *Notropis hudsonius* (Cyprinidae) from Montana, with a synopsis of the genus *Unicauda* Davis, 1944. *Folia Parsitologica*, **47** : 273-278
- Corliss, J.O. 1984. The kingdom Protista and its 45 phyla. *Biosystems*, **17** : 87-126.
- Corliss, J.O. 1985. Consideration of taxonomic nomenclatural problems posed by report of myxosporidians with two host life cycle. *J. Protozool.*, **32** : 589-591.
- Dana, D. 1982. The biology of transmission of *Myxobolus nerobius* Scuberg and Schroder, 1905 a myxosporean parasite of salmonid fishes. Master's Thesis, Simon Fraser University, Burnaby, B.C.
- Das, A.K., Mandal, A.K., Nandi, N.C., Nandi, R. and Sarkar, N.C. 1993. Protozoa fauna of West Bengal. 2. Parasitic Protozoa. *State Fauna Series* 3. Fauna of West Bengal, part 12. Z.S.I , Calcutta pp. 135-468.
- Das, M.K. 1985. Studies on Protozoan Parasites in intensive culture ponds of West Bengal. Ph.D. Thesis, University of Kalyani, Kalyani, India.
- Das, M.K. 1992a. Fish pathogens their occurrence in floodplain ecosystems –virus, bacteria, protozoa and Fungi. In : *FAO sponsored Training Programme on Flood plain Fisheries Management* (1.9.92-31.12.92) *Compendium* Vol. 1 (eds. S.Yadav and V. V. Sugunan), pp. 103-107.

- Das, M.K. 1992b. Fish health monitoring and disease control measures. In : *FAO sponsored Training Programme on Flood plain Fisheries Management (1.9.92-31.12.92) Compendium Vol. 1* (eds.S.Yadav and V.V.Sugunan), pp. 108-117.
- Das, M.K. 1996. Myxozoan and urceolarid ciliate parasites of wild and cultured *Liza parsia* in deltaic West Bengal. *J. Inland. Fish. Soc. India*, **28** (2) : 46-56.
- Das, M.K. and Das, R.K. 1995. Fish Disease in India A review. *Environ. & Ecol.*, **13** (3) : 533-541.
- Das, M.K. and Haldar, D.P. 1986. Studies on Protozoan parasites from fishes : Two new species of the genus *Neothelohanellus* n. gen. (Myxosporidia). *Arch. Protistenk.*, **132** : 125-130.
- Das, R.C., Das, N. and Sinha, Y.K.P. 1988a. Occurrence of acute endoparasitism (myxoboliasis) in the brain of a freshwater fish *Labeo bata* (Hamilton). *J. zool. Res.*, **1** (2) : 153-155.
- Das, M.K, Pal, R.N. and Ghosh, A.K. 1988b. The morphology and development of a new myxozoan *Ceratomyxa cyanoglossi* sp. n. from an estuarine fish *Cyanoglossus lingua*. *J. Inland. Fish Soc. India*, **20** (1) : 63-65.
- Das, M.K., Haldar, D.P. and Mondal, S.K. 1989. Macroecological studies on protozoan disease of carps in tropical intensive fish culture ponds in India. *Environment and Ecology*, **7** (1) : 1-9.
- Davis, H.S. 1917. The myxosporidea of the Beaufort region : A systematic and biological study. *Bull. Bur. Fish.*, **35** : 201-243.
- Davis, H.S. 1924. A new myxosporidian parasite, the cause of wormy halibut. *Rep. U.S. Comm. Fish.* (year 1923) **8** : 1-5.
- Davis, H.S. 1944. A revision of the genus *Henneguya* (Myxosporidia) with description of two new species. *Trans. Amer. Micro. Soc.*, **63** : 311-320.
- Dey, R.K. and Chandra, S. 1994. New trends in fish disease management through application of herbal materials. *Fishing chymes*, **19** : 13-14.
- *Doflein, F. 1898. Studien zur Naturgeschichte der protozoen three uber Myxosporidien. *Zool. Jahrb. Abt. Anat onlog.* Tien, **2** : 281-350.
- *Doflein, F. 1899. Fortschritte auf dem Gebiete der Myxosporidienkunde Zussammenfassende Uebersicht. *Zool. Zentrbl.*, **6** : 361-379.
- Dogel' V.A. and Bauer, O.N. 1955. Control of parasitic diseases of fish in pond farms. *Izdalet'stro. A. N. SSR.*

- Dykova, I. and Lom, J. 1978. Histopathological changes in fish gills infected with myxosporidian parasites of the genus *Henneguya*. *J. Fish. Biol.*, **12** : 197-202.
- Dykova, I. and Lom, J. 1982. *Sphaerospora renicola* n. sp., a myxosporean from carp kidney and its pathogenicity. *Z. Parasitenkd.*, **88** : 259-268.
- Egusa, S., Maeno, Y. and Sorimachi, M. 1990. A new species of myxozoa, *Myxobolus episquammalis* sp. nov., infecting the scales of the mullet, *Mugil cephalus*. *L. Fish Pathology.*, **25** (2) : 87-91.
- Eiras, J.C. and D'Souza, J. 2004. *Myxobolus goensis* n. sp. (Myxozoa, Myxosporea, Myxobolidae), a parasite of the gills of *Mugil cephalus* (Osteichthyes, Mugilidae) from Goa, India. *Parasite*, **11** (3) : 243-248.
- El Matbouli, M. and Hoffman, R.W. 1991. Prevention of experimentally induced whirling disease in rainbow trout *Oncorhynchus mykiss* by fumagillin. *Dis. aquat. Org.*, **10** : 109-113.
- Evadakimova, E.B. 1973. New species of myxosporidias from fishes of Kelingrad *Parazitologiya*, **15** : 168-170.
- Ferguson, H.W. 1981. The effect of water temperature on the development of proliferative kidney disease in rainbow trout, *Salmo gairdneri* Richardson. *J. fish. Dis.*, **4** : 175-177.
- Ferguson, H.W. and Ball, H.J. 1979. Epidemiological aspects of the proliferative kidney disease amongst rainbow trout, *Salmo gairdneri* Richardson. *J. fish. Dis.*, **2** : 219-225.
- Flores, V. and Viozzi, G. 2001. Redescription, seasonality and distribution of *Myxobolus magellanicus* (Myxosporea) in *Galaxias maculatus* (Osmeriformes, Galaxiidae) from Patagonian Andean Lakes (Argentina). *Acta Parasitologica*, **46** (3) : 159-163.
- Fujita, T. 1912. Notes on sporozoan parasites of fishes. *Zool. Anz.*, **39** : 259-262.
- Fujita, T. 1930. On the new myxosporidian, *Chloromyxum bora* nov. sp., in the muscle of the grey mullet (Japanese with English summary). *Zool. Mag. Tokyo*, **42** : 45-48.
- Ganapati, P.N. 1936. A new species of myxosporidian from the heart of a marine fish, *Otolithus ruber*. *Curr. Sci.*, **65** : 204.
- Ganapati, P.N. 1941. On a new myxosporidian *Henneguya otolithi* n. sp., a tissue parasite from the bulbus arteriosus of two species of fish of the genus *Otolithus*. *Proc. Ind. Acad. Sci.*, **13** : 135-150.

- *Gavaeskaya, A.V., Kovaleva, A.A. and Schulman, S.S. 1982. *Neoparvicapsula* gen. n. and the position of the family Parvicapsulidae among the Myxosporidia (In Russian). *Zool. Zh.*, **5** : 774-775
- Gopalakrishnan, V. 1968. Diseases and parasites of fishes in warm water ponds in Asia and far East, *F. A. O. Fish Rep.*, **5** : 319-343
- *Grasse, P.P. 1960. Les myxosporidies sont des organismes pleuricellularis. *C.R. Acad. Sci. Paris* **251** : 2638-2640.
- Grell, K.G. 1973. *Protozoology*. Springer-Verlag, Berlin–Newyork.
- Griffin, B. and Davis, E. 1978. *Myxosoma cerebralis* : detection of circulating antibodies in infected rainbow trout (*Salmo gairdneri*). *J. Fish. Res. Board Canada*, **35** : 1186-1190.
- Gupta, S. and Khera, S. 1987. On the genera *Henneguya* Thelohan, 1892 and *Unicauda*, Davis, 1944. *Res. Bull. (Science), Punjab university.*, **38** (I-II) : 153-163.
- Gupta, S. and Khera, S. 1988a. On a new myxosporean parasite (Myxozoa) *Lomosporus indicus* gen. et., sp. n., from the freshwater fish, *Labeo calbasu* (Ham.). *Acta Protozool* **27** (2) : 171-175.
- Gupta, S. and Khera, S. 1988b. Review of the genus *Myxobolus* Butschli, 1882. *Res. Bull. (Science), Punjab University.*, **39** (I-II) : 45-48.
- Gupta, S. and Khera, S. 1988c. On one new and one already known species of the genus *Myxobolus* from fresh water fishes of India. *Res. Bull. (Science), Punjab University*, **39** (III-IV) : 173-179.
- Gupta, S. and Khera, S. 1988d. On a new species *Myxidium labeonis* from freshwater fishes of Punjab, India. *Arch. Protistenkd.*, **136** : 393-396.
- *Gupta, S. and Khera, S. 1989a. Observations on *Myxobolus punjabensis* sp. nov., (Myxozoa : Myxobolidae) parasitic on gills and fins of *Labeo dyocheilus*. *Riv.Parasitol.*, **50** (1-2) : 131-138.
- Gupta, S. and Khera, S. 1989b. Observations on *Myxobolus haldari* sp. nov., (Myxozoa : Myxosporea) from freshwater fishes of northern India. *Res. Bull. (Science), Punjab University.*, **40** (III-IV) : 281-191.
- Gupta, S. and Khera, S. 1990. On three species of the genus *Myxobolus* Butschli, 1882 from freshwater fishes of northern India. *Indian J. Parasitology*, **14** : 1-8.
- Gupta, S. and Khera, S. 1992. On *Thelohanellus ophthalmicus* (Myxozoa : Myxosporea) and histopathological changes due to this parasite in the gills of *Catla catla*. *Rec. zool. Surv. India*, **91** (2) : 263-270.

- Gupta, N., and Saraswat, H. 1993. Haemoprotozoosis in *Clarias batrachus* (Linn) from freshwater ponds of Rohilkhand region, India. *Him. J. Env. Zool.*, **7** : 47-52.
- Gupta, N., Gupta, T.K. and Saraswat, H. 2001. Hypoglycemia in *Heteropneustes fossilis* parasitized by two new species of parasites (*Trypanosoma karelsensis* n. sp., and *Myxosoma fossilii* n. sp.) *Proc. Natl. Sym. On fish Health Management and sustainable aquaculture*. pp. 179-186.
- Hagargi, S.S. and Amoji, S.D. 1981. *Myxosoma karnatakae* n. sp. (Protozoa : Myxosporidia) from the caudal muscles of fresh water teleost fish, *Barbus chola* (Ham. et Buch.). *Arch. Protistenk.*, **124** : 385-390.
- Hagargi, S.S., Kundu, T.K. and Haldar, D.P. 1979. Observations on *Thelohanellus rodgi* n. sp. (Protozoa : Myxosporidia) from a freshwater teleost. *J. Karnatak Univ. Sci.*
- Haldar, D.P., Das, M.K. and Sharma, B.K. 1983. Studies on Protozoan parasites from fishes. Four new species of the genera *Henneguya* Thelohan, 1882, *Thelohanellus* Kudo, 1933. and *Myxobolus* Butschli, 1882. *Arch. Protistenk.*, **127** (2) : 283-296.
- Haldar, D.P. and Mukherjee, M. 1985. Studies on Bivalvulida (Myxozoa : Myxosporea) : Observations on two new species of *Henneguya* from food fishes of West Bengal, India. *Arch. Protistenk.*, **130** : 419-425.
- Haldar, D.P., Mukherjee, M. and Kundu, T.K. 1981. Observations on two new species of *Myxosoma* Thelohan, 1892 (Myxozoa : Myxosomatidae) from fresh water teleost fishes. *Arch. Protistenk.*, **124** : 244-251.
- Haldar, D.P., Samal, K.K. and Mukhopadhyay, D. 1996. Studies on the protozoan parasites of fishes in Orissa : eight species of *Myxobolus* Butschli (Myxozoa : Bivalvulida). *J. Beng. Nat. Hist. Soc.*, **16** (1) : 3-24.
- Haldar, D. P., Samal, K. K. and Mukhopadhyay, D. 1997. Studies in the protozoan parasites of fishes in Orissa : five new species of the genera *Henneguya*, *Thelohanellus* and *Unicauda* (Myxozoa : Bivalvulida). *J. Beng. Nat. Hist. Soc.*, **16** (2) : 50-63.
- Hallyday, M.M. 1974. Studies on *Myxosoma cerebralis*, a parasite of salmonoids IV. A preliminary immunofluorescent investigation of the spores of *Myxosoma cerebralis*. *Nor. Vet.*, **25** : 173-179.
- Hausmann, K. and Haulsmann, K. 1996. *Protozoology*. 2nd Edition. George Thieme, Stuttgart.
- Hedrick, R.P., Groff, J.M., Foley, P., and McDowell, T. 1988. Oral administration of fumigillin DCH protects chiknook salmon, *Onchorhynchus tshawytscha* from experimentally induced proliferative kidney disease. *Dis. Aquat. org.*, **4** : 165-167.

- *Hofer, B. 1903. Uber die Drehkrankhert der Re gebogenferelle. *Alla.Fischereiztg.*, **28** : 728.
- Hoffman, G.L. 1974. Disinfection of contaminated water by ultraviolet radiation, with emphasis on whirling disease (*Myxosoma cerebralis*) and its effect on fish. *Trans, Amer. Fish Soc.*, **103** : 541-550.
- Hoffman, G.L. 1975. Whirling disease (*Myxosoma cerebralis*) : control with ultraviolet radiation and its effect on fish. *J. Wild l. Dis.*, **11** : 505-507.
- Hoffman, G.L. Sr. and Hoffman, G.L. Jr. 1972. Studies on the control of whirling disease (*Myxosoma cerebralis*) : I. The effect of chemicals on spore in vitro and Calcium hydroxide as disinfectant in simulated ponds. *J. Wildl. Dis.*, **8** : 49-53.
- Hoffman, G.L. and Meyer, F.P. 1974. Parasites of Freshwater Fishes, a review of their control and Treatment. T.F.H. Publications, Neptune, New Jersey.
- Hoffman, G.L. and O'Grodnick, J.J. 1977. Control of whirling disease (*Myxosoma cerebralis*) : I. the effects of drying and disinfection with hydrated lime or chlorine. *J. Fish Biol.*, **10** : 175-179.
- Hoffman, G.L. and Putz, R.E. 1969. Host susceptibility and the effect of aging, freezing, heat and chemicals on spore of *Myxosoma cerebralis*. *Prog. Fish-cult.*, **31** : 35-37.
- Hoffman, G.L. and Putz, R.E. 1971. Effect of freezing and aging on spore of *Myxosoma cerebralis*, the causative agent of whirling disease. *Prog. Fish-cult.*, **33** : 95-98.
- Hoffman, G.L., Putz, R.E. and Dunbar, C.E. 1965. Studies on *Myxosoma cartilaginis* N. sp., (Protozoa : Myxosporidea) of centrarchid fish and a synopsis of the *Myxosoma* of North American freshwater fishes. *J. Protozool.*, **12** : 319-332.
- Hosina, T. 1952. Notes on some myxosporidian parasites of fishes of Japan. *J.Tokyo Univ. Fish.*, **39** : 69-97.
- *Ishii, S. 1915. *Lentospora* parasitic in the skin of the Japanese eel. *Zool. Mag.* (Tokyo), **27** : 471-474.
- Jaczo, I. 1940. Vizsgal tok a balaton halainak myxosporidian 1 *Magyar Bioygiai Kutato Interzet Munkai*, **12** : 227-290.
- Jayasri, M. 1982. Morphology and pathology of *Myxobolus sophorae* n. sp., *Proc. Indian Acad. Parasitology*, **3** : 1-3.
- Jayasri, M., Parvateesam, M. and Mathur, P.N. 1981. *Myxosoma mathurii* n. sp., (Protozoa : Myxosporidia) parasitic on *Puntius sarana*. *Curr. sci.*, **50** (11) : 736-739.

- Jayasri, M. and Hoffman, G.L. 1982. Review of *Myxidium* (Protozoa : Myxozoa Myxosporidia). *Protozool. Abstr.*, **6** (4) : 61-90.
- Joy, J.E., Tartar, D.C. and Franklin, H. 1978. Gill parasites, *Octomacrum spinum* (Trematoda, Monogenea) and *Unicauda* sp.(Protozoa : Myxosporidia) from the stone roller minnow (*Campostoma anomalum*) in west Virginia. *Trans. Amer. Micr. Soc.*, **97** (1) : 100-104.
- Kabata, Z. 1963. Parasites as biological tags. *Spec. publs. Int. Comm. NW. Atlant. Fish.*, **4** : 31-37.
- Kabata, Z. 1967. Whirling stocks and their gall-bladder parasites in British waters. *Mar. Res. No.*, **2**, 11 pp.
- Kalavati, C. and Anuradha, I. 1992. Species association patterns among myxosporeans parasitic to mullet, *Mugil cephalus*, found in the backwaters in Visakhapatnam, East coast of India. *Proc. zool. Soc., Calcutta*, **45** (suppl. A) : 107-113.
- Kalavati, C. and Anuradha, I. 1993. Two new species of myxosporeans infecting *Valamugil cunnesius* in Visakhapatnam harbour, East coast of India. *Uttar Pradesh J. Zool.*, **13** (2) : 148-152.
- Kalavati, C. and Anuradha, I. 1995. A new myxosporean, *Bipteria indica* sp. n. (Myxospora : Sinuolineidae) from the gall bladder of the striped mullet, *Mugil cephalus* Linneaus. *Acta Protozool.*, **34** : 307-309.
- Kalavati, C., Padma Dorothy, K. and Paul Pandian, P. 2002. Gall bladder inhabiting myxosporidia from fishes of Andaman Sea. *J. Parasitic Diseases*, **26** (2) : 89-100.
- Kalavati, C. and Narasimhamurti, C.C. 1981. *Unicauda andhrae* n. sp., (Myxosporidia) in the mucus on the gills of *Ophiocephalus gachua*. *Z. Parasitenkd.*, **65** : 89-93.
- Kalavati, C. and Narasimhamurti, C.C. 1984a. A new myxosporidian, *Rudicapsula esomi* n. gen. n. sp., from the freshwater fish, *Esomus* sp. *Z. Parasitenkd.*, **70** : 21-27.
- Kalavati, C. and Narasimhamurti, C.C. 1984b. Two new species of myxosporidians, *Chloromyxum tripathii* sp. n., and *Chloromyxum mitchelii* sp. n., from fish, *Therapon jarbua* (Fosskal). *Acta Protozool.*, **23** (2) : 135-144.
- Kalavati, C. and Narasimhamurti, C.C. 1984c. Histopathological changes in the gills of *Channa punctatus* Bl. infected with *Henneguya waltirensis*. *Arch. Protistenkd.* **129** (4) : 199-202.
- Kalavati, C., Sandeep B.V. and Narasimhamurti, C.C. 1981. Two new species of myxosporidians, *Myxosoma channai* n. sp., and *Myxobolus tripathii* n. sp., from freshwater fishes of Andhra Pradesh. *Proc. Indian. Acad. Sci.*, **90** (1) : 61-78.

- Kalavati, C., Venkateswara Rao, J. and Vaidehi, J. 1992. Myxosporidian parasites (Protozoa) of fishes of Chilka Lake, east coast of India : Three new species of *Henneguya*, *Thelohan*, *Rudicapsula*, Kalavati and Narasimhamurti and *Unicauda*, Auerbach. *Ind. J. Parasitol.*, **16** (1) : 77-83.
- Kalavati, C. and Vaidehi, J. 1991a. A new myxosporidian, *Thelohanellus chilkensis* n. sp. from the gills of the common carp, *Labeo rohita* in Chilka Lake, Orissa, India. *Uttar Pradesh J. Zool.*, **11** (1) : 73-78.
- Kalavati, C. and Vaidehi, J. 1991b. Two new species of myxosporidians from fishes of Chilka Lake. I. Genus *Sphaeromyxa* Thelohan and *Zshcokkella* Auerbach. *Uttar Pradesh J. Zool.*, **11** (2) : 146-150.
- Kalavati, C. and Vaidehi, J. (1996). A new myxosporan, *Myxobilatus notopterii* from the gall bladder of *Notopterus notopterus* in Chilka lake India, *Riv. Parassitol.*, **33** (57) : 79-82.
- Karamchandani, S.J. 1970. A new species of *Myxobolus* from the gill cavity of *Labeo bata* (Ham.). *J. Inland Fish. Soc. India*, **2** : 170-171.
- Kent, M.L. and Hedrick, R.P. 1985a. Transmission of the causative agent of proliferative kidney disease (PKD) with the blood and spleen of infected fish : further evidence that the PKX parasite belongs to the phylum Myxozoa. *Bull. Euro. Assoc. Fish. Pathol.*, **5** : 39-42.
- Kent, M.L. and Hedrick, R.P. 1985 b. PKX : The causative agent of proliferative Kidney disease (PKD) in pacific salmonoid fishes and its affinities with Myxozoa. *J. Protozool.*, **32** : 254-260.
- Kent, M.L. and Hedrick, R.P. 1986. Development of PKX myxosporean in rainbow trout, *Salmo gairdneri*. *Dis. Aquat. Org.*, **1** : 169-182.
- Kent, M.L. and Hedrick, R.P. 1987. Effects of cortisol implants on the PKX myxosporean causing proliferative kidney disease in rainbow trout, *Salmo gairdneri*. *J. Parasitol.*, **73** : 455-461.
- Kent, M.L., Andru, K.B., Bartholomew, J.L., El Matbouli, M., Desser, S.S., Delvin, R. H., Hedrick, R.P., Hoffmann, R.W., Kallera, J., Hallet, S.L., Lester, R.J.G., Longshaw, M., Palenzeula, O., Siddal, M.E. and Xiao, C. 2001. Recent advances in our knowledge of Myxozoa. *J. Eukaryot. Microbiol.*, **48**(4) : 395-413.
- Kent, M.L., Margolis, L. and Corliss, J.O. 1994. The demise of a class of protists : taxonomic and nomenclatural revisions proposed for the Protist phylum Myxozoa Grasse, 1970. *Can. J. Zool.*, **72** : 932-937.
- Khan, R.A. 1998. Influence of petroleum at a refinery terminal on feral flounder, *Pleuronectes americanus*. *Bull. Environ. Contam. Toxicol.*, **61** : 770-777.

- Khan, R.A. 1999. Length mass relationship, histopathology and parasitism in winter flounder (*Pleuronectes americanus*) living near a PCB contaminated naval facility in Newfoundland. *Can. J. Zool.*, **77** : 381-388.
- Khan, R.A. and Tuck, C. 1995. Parasites as biological indicators of stocks of Atlantic cod (*Gadus morua*) off Newfoundland, Canada. *Can. J. Fish. Aquat. Sci.*, **52** (Suppl 1) : 195-201.
- Koveleva, A.A., Zubchenko, A.V. and Krasin, V.K. 1983. Foundation of a new myxosporidean family (Protozoa : Myxosporidia) with a description of two new genera. (in Russian). *Parazitologiya*, **17** (3) : 195-202.
- Kozel, T.R., Lott, M., and Taylor, R. 1980. Isolation of *Myxosoma cerebralis* (whirling disease) spore from infected fish by use of physical separation technique. *Can. J. Fish. Aquat. Sci.*, **37** : 1032-1035.
- Krishna Kumar, K. 2000. Studies on Myxosporean parasites of fishes of Kerala. Ph.D Thesis (Unpublished), University of Kerala, India.
- Kudo, R.R. 1919. Studies on Myxosporidea : a synopsis of genera and species of myxosporidia. *Ill. Biol. Monogr.*, **5** (3-4) : 1-265.
- Kudo, R.R. 1921. On the effect of some fixatives upon Myxosporidian spores. *Trans. Amer. Micr. Soc.*, **40** : 161-167.
- Kudo, R.R. 1929. Histozoic myxosporidia found in freshwater fishes of Illinois, USA. *Arch. Protistenk.*, **65** : 364 -378.
- Kudo, R.R. 1933. A taxonomic consideration of Myxosporidia. *Trans. Amer. Micro. Soc.*, **52** : 195-216.
- Kudo, R.R. 1966. *Protozoology*. 5th edition, Charles C. Thomas, Springfield, Illinois.
- Kundu, T.K. 1985. *Myxosoma indirae* sp. n. (Myxozoa : Myxosomatidae) from the head cartilage, scale and tail fin of *Cirrhina mrigala* (Ham.). *Acta Protozool.*, **24** (3-4) : 333-337.
- Kundu, T.K. and Haldar, D.P. 1981. Studies on *Thelohanellus jiroveci* sp. n., a new myxosporidian parasitic in a common teleost fish. *Vest. Cesk. Spot. Zool.*, **45** : 94-101.
- Laird, M. 1953. The protozoa of New Zealand intertidal fishes. *Trans. Roy. Soc. N. Z.*, **81** : 285-356.
- Lakshminarayana, D. 1988. Studies on myxosporidian parasites of freshwater fishes of Andhra Pradesh. M.Phil Dissertation (unpublished), Andhra University, India.

- Lalitha Kumari, P.S. 1965. On a new species of *Henneguya* (Protozoa : Myxosporidia) from an Indian fresh water fish, *Ophicephalus gachua*. *Riv. Parasitol.*, **26** : 79-84.
- Lalitha Kumari, P.S. 1968. On a new species *Myxobolus seshadrii* (Protozoa : Myxosporidia) from an Indian fresh water fish, *Labeo fimbriatus*. *Riv. Parassitol.*, **29** (3) : 161-164.
- Lalitha Kumari, P.S. 1969. Studies on parasitic protozoa (Myxosporidia) of fresh water fishes of Andhra Pradesh, India. *Riv. Parassitol.*, **30** : 153-226.
- Landsberg, J.H. and Lom, J. 1991. Taxonomy of the genera of the *Myxobolus/Myxosoma* group (Myxobolidae : Myxosporidia), current listing of the species and revision of synonyms. *Systematic Parasitology*, **18** : 165-186.
- Larsen, G., Hemmingsen, W., Mackenzie, K. and Lysne, D.A. 1997. A population study of cod, *Gadus morhua* L., in northern Norway using otolith structure and parasite tags. *Fisheries Research*, **32** : 13-20.
- Lee, J.J., Hutner, S.H. and Bovee, E.C. 1985. *An Illustrated guide to the Protozoa*. Society of Protozoologists, Lawrence, Kansas.
- *Leger, L. and Hesse, E. 1907. Sur une nouvelle myxosporian parasite da la sardine. *Ann. Univ. Grenoble.*, **19** : 3-6.
- Leith, D.A. and Moore, K.D. 1967. Peltron pilot Hatchery progress report, November 1966 through October, 1967, *Oregon Fish Comm. Res. Div. Prog. Rpt.* 50pp.
- Lester, R.J.G. 1990. Reappraisal of the use of parasites for stock identification. *Aust. J. mar. freshwater Res.*, **41** : 855-864.
- Levine, N.D., Corliss, J.O., Cox, F.E.G., Deroux, G., Grain. J., Honnigberg, B.M., Leedale, G.F., Loeblich, A.R., Lom, J., Lynn, D., Merinfeld, G., Page, F.C. Poljansky, G. Sprague, V., Vavra, J. and Wallace, F.C. 1980. A newly revised classification of protozoa. *J. Protozool.*, **27** : 37-59.
- Lom, J. 1969a. Notes on the ultrastructure and sporoblast development in the fish parasitizing myxosporidian of the genus *Sphaeromyxa*. *Z. Zellforsch. Mikrosk. Anat.*, **97** : 416 -437.
- Lom, J. 1969b. Cold blooded vertebrate immunity to protozoa. In : G.J. Jackson, R. Herman, and I. Singer (eds.). *Immunity to parasitic Animals* pp. 249-265. Appleton-century-crofts, New york, Educational Division, Meredit corporation.
- Lom, J. 1987. Myxosporidia : A new look at long known parasites of fish. *Parasitol. Today*, **3** : 327-332.

- Lom, J. and Arthur, J.R. 1989. A guideline for preparation of species description in Myxosporea. *J. Fish. Dis.*, **12** : 151-156.
- Lom, J. and Dykova, I. 1992. Protozoan parasites of fishes. *Development in aquaculture and Fishries science*, Elsevier, Amsterdam. **26** : 160-235.
- Lom, J. and de Puytorac, P. 1965. Studies on the myxosporidean ultrastructure and polar capsule development. *Protistologica*, **1** (1) : 53-65.
- Lom, J. and Hoffman, G.L. 1971. Morphology of the spores of *Myxosoma cerebralis* (Hofer, 1903) and *M. cartiliginis* (Hoffmana, Putz and Dunbar, 1965). *J. Parasitol.*, **57** : 1302-1308.
- Lom, J. and Noble, E.R. 1984. Revised classification of the class Myxosporea Butschli, 1881. *Folia Parasitologia* (Praha), **31** : 193-205.
- Long, C.C. and Meglitsch, P. 1969. Pretreatment of spores as a factor in dimensional analysis of two species of histozoic myxosporidia. *Iowa Acad. Sci.*, **76** : 436-445.
- Lucky, Z. 1978. Occurrence of *Myxobolus pavlovskii* the parasite of *Hypophthalmichthys molitrix* and *Aristichthys nobilis* in the fish ponds in Czechoslovakia. *Acta veterinaria. Brno.*, **47** : 203-207.
- Mackenzie, K. 1987. Parasites as indicators of host populations *Internat. J. Parasitol.*, **17** : 345-352.
- Mackenzie, K. and Abaunza, P. 1998. Parasites as biological tags for stock discrimination of marine fish : a guide to procedures and methods. *Fish. Res.*, **38** : 45-56.
- Mackenzie K., Kalavati, C., Gaard, M. and Hemmingsen, W. 2005. Myxosporean gall bladder parasites of gadid fishes in the North Atlantic : Their geographical distribution and an assessment of their economic importance in fisheries and Mariculture. *Fish. Res.*, **76** : 454-465.
- Maeno, Y., Sorimachi, M. and Egusa, S. 1990 *Myxobolus spinocurvatura* sp. N. (Myxosporea : Bivalvulida) parasitic in deformed mullet, *Mugil cephalus*. *Fish Pathology*, **25** (1) : 37-41.
- Mahaeswari, S.C. 1986 (1987). Occurrence of whirling disease in *Cirrhina mrigala* in Wardha. *J. Bombay Nat. Hist. Soc.*, **83** (3) : 673.
- Malhotra, Y.R., Jyoti, M.K. and Gupta, K. 1978. *Ichthyophonus* and *Myxobolus* as a possible cause of exophthalmia and ovotestes condition in male *Channa punctatus* Bloch. *Matsya*, **4** : 83-86.

- Mandal, A.K., Das, A.K. and Nandi, N.C. 1990. Collection and preservation of animals : Protozoa and Mesozoa. In : *Handbook of Zoological collectors*, Z.S.I. pp 1-17.
- Mandal, A.K. and Nair, K.N. 1975. *Myxobolus eeli* sp. n., (Myxobolidae) a new myxosporidian from Indian Spiny eel, *Mastacembelus armatus* (Lacepede). *Acta. Protozool.*, **14** (2) : 175-178.
- Marcogliese D.J. and Cone, D.K. 2001. Myxozoan communities parasitizing *Notropis hudsonius* (Cyprinidae) at selected localities on the St. Lawrence river, Quebec : possible effects of urban effluents. *J. Parasitol.*, **87** : 951-956.
- *Markevich, A.P. 1932. Zur kenntnis der myxosporidien von süsswasserfishchen. *Zool. Anz.*, **99** (11/12) : 297-303.
- Markiw, M.E. 1989. Portals of entry for salmonoid whirling disease in rainbow trout. *Dis. Aquat. Org.*, **6** : 7-10.
- Markiw M.E. and Wolf, K. 1974a. *Myxosoma cerebralis* : isolation and concentration from fish skeletal elements, sequential enzymatic digestion and purification by differential centrifugation. *J. Fish. Res. Board. Can.*, **31** : 15-20.
- Markiw, M.E., and Wolf, K. 1974b. *Myxosoma cerebralis* : comparative sensitivity of spore detection methods. *J. Fish. Res. Board. Can.*, **31** : 1597-1600.
- Markiw, M.E., and Wolf, K. 1978. *Myxosoma cerebralis* : fluorescent antibody techniques for antigen recognition. *J. Fish. Res. Board. Can.*, **35** : 828-832.
- Markiw, M.E., and Wolf, K. 1980. *Myxosoma cerebralis* : trypsinization of plankton centrifuge harvest increases optical clarity and spore formation. *J. Fish. Res. Board. Can.*, **37** : 2225-2227.
- Martinez de velasco, G., Rodero, M., Zapatero and Cuellar, C. 2002. Humoral immune responses induced by *Kudoa* sp. (Myxosporidia : Multivalvulida) antigens in BALB/c mice. *Mem. Inst. Oswaldo Cruz, Rio de Janeiro*. **97** (8) : 1091-1095.
- McArthur, C.P. and Sengupta, S. 1982. Antigenic mimicry of eel tissue by a myxosporidian parasite. *Z. Parasitenk.*, **66** : 249-255.
- McClelland, R.S., Murphy, D.M and Cone, D.K. 1997. Report of spores of *Henneguya salmonicola* (Myxozoa) in human stool specimens : possible source of confusion with human spermatozoa. *J. Clin. Microbiol.*, **35** : 2815-2818.
- Mehlhorn, H., Schmahl, G and Haberkorn, A. 1988. Toltrazuril effective against a broad spectrum of protozoan parasites. *Parasitol. Res.*, **75** : 64-66.
- Meglitsch, P.A. 1947. Studies on Myxosporidea from Beaufort region II Observations on *Kudoa clupeiidae* (Hahn), gen, nov. *J. Parasitology*, **33** : 271-277

- Meglitsch, P.A. 1960. Some coelozoic myxosporidia from New Zealand fishes I. General and family Ceratomyxidae. *Trans. Roy Soc. N.Z.*, **88** : 265-356.
- Meglitsch, P.A. 1968. Some coelozoic myxosporidia from New Zealand fishes II. On a new genus of myxosporidia, *Auerbachia*. *Proc. Iowa. Acad. Sci.*, **75** : 397-401
- Menon, N.G. 1986. On a new myxosporidan *Henneguya tachysuri* sp. nov., from the marine cat fish *Tachysurus thalassinus* Ruppell, from the Gulf of Mannar. *J. Mar. Biol. Assoc. India*, **21**(1/2) : 196-199.
- *Mingazzini, P. 1890. Sullo sviluppo dei Myxosporidi. *Bull. Soc. Nat. Napoli.*, **4** : 160-164.
- Mitchell, L.G. 1976. Myxosporidia : In : *Parasitic Protozoa*. (ed.) J. P. Kreier, Academic press, New York. pp. 115-154.
- Misra, B.K. 1999. Parasitic and fungal diseases of fish, their treatment and control. In : *Compendium of the Training programme on fish diseases, their diagnosis and control*, CIFA, Bhuvaneswar, pp. 34-41.
- Mohan, C.V. and Shankar, K.M. 1995. Pathogenic myxosporean infection in early fry of Indian major carp, *Catla catla*. *Curr. Sci.*, **68** (5) : 548-551.
- Moles, A., and Short, J. 1989. Parasites and chemical markers show promise for stock separation. *NWAFSC Quart Rept., NMFS, U.S. Dept. Comm.* Jan-Mar., pp. 1-11.
- Molnar, K. 1994. Comments on host, organ and tissue specificity of fish myxosporeans and on the types of their intrapiscine development. *Parasit. hung.*, **27** : 5-20.
- Molnar, K. 1998. Taxonomic problems, seasonality and histopathology of *Henneguya creplini* (Myxosporidia) infection of pike perch *Stizostedion luciperca* in lake Balaton. *Folia Parasitol.*, **45** : 261-269.
- Molnar, K., Baska, F. and Szekely, C. 1987. Fumagillin, an efficacious drug against renal sphaerosporosis of the common carp, *Cyprinus carpio*. *Dis. Aqat. Org.*, **2** : 187-190.
- Moncada, L.I., Lopez, M.C., Murcia, M.I., Nicholas, S. Leon, F. Guio, O.L. and Corredor, A. 2001. *Myxobolus* sp., another opportunistic parasite of immunosuppressed patients? *J. Clin. Microbiol.*, **39** (5) : 1938-1940.
- Moser, M. 1991. Parasites as biological Tags. *Parasitol. Today*, **7** (7) : 182-187.
- Moser, M. and Kent, M.L. 1994. Myxosporidia. In : *Parasitic Protozoa*. J.P. Kreier (ed.) vol., **8** : 265-318. Academic Press. Newyork.
- Moser, M., Kent, M.L. and Dennis, D. 1989. Gall bladder Myxosporidia in coral reef fishes from Heron islands, Australia. *Aust. J. Zool.*, **37** : 1-13.

- Moser, M. and Noble, E.R. 1977. Three genera of Myxosporidea (Protozoa) in macrourid fishes. *Int. J. Parasitol.*, **7** : 93-96.
- Mukherjee, M. 1990. Fish diseases due to protozoan parasites and their relation to the environment. In : *Impact of Environment on Animals and Aquaculture*, pp. 261-264.
- Mukherjee, M. and Haldar, D.P. 1981. Studies in the spore morphology of *Myxobolus punctatus* Ray Chaudhuri and Chakravarty, 1970. (Myxosporidia : Myxobolidae); variations due to invasion in different organs of the fish, *Ophicephalus punctatus* Bloch. *Arch. Protistenk.*, **124** : 29-35.
- Mukhopadhyay, D. and Haldar, D.P. 1998. Spore variations in a piscine myxozoan parasite (Myxozoa : Myxosporida) from the juvenile major carp, *Catla catla*. *Trans. Zool. Soc. India*, **2** (1) : 46-52.
- Mukhopadhyay, D. and Haldar, D.P. 2003. *Myxobilatus anguillaris* sp. n., (Myxosporida : Sphaerosporidae) a new species of histozoic myxosporean from an estuarine fish. *J. Parasit. Appl. Anim. Biol.*, **12** (1/2) : 9-14.
- Mukhopadhyay, D. and Haldar, D.P. 2004. *Thelohennellus endodermis* sp. n. A new Myxozoan (Myxozoa : Bivalvulida) from the major carp, *Labeo rohita* (Hamilton-Buchanan) in a sewage farm in West Bengal, India. *Environment & Ecology*, **22** (1) : 139-142.
- *Mulsow, K. 1911. Eine neuer Gehirnparasit des Karpfens. *Allg. Fisch. Zeit.*, **36** : 483-485.
- Nakai, N. 1926. Eine neue Myxosporidean art aus den Kiemen des Karpfens (Japanese and German). *Suisan Kosyuzya Siken Hokoku*, **22** : 11-20.
- Nandi, N.C., Kalavati, C., Das, A.K. and Nandi, R. 2004. Parasitic protozoa. *State Fauna Series 5 : Fauna of Andhra Pradesh, Part-6* (Protozoa) pp. 1-466. Zool. Surv. India, Kolkata.
- Nandi, N.C., Nandi, R. and Mandal, A.K. 1983. Index – catalogue and Bibliography of protozoan parasites from Indian fishes. *Rec. zool. Surv. India. Occ. Paper No. 41* : pp. 1-46.
- Nandi, N.C., Nandi, R. and Mandal, A.K. 2002. Index – catalogue and Bibliography of protozoan parasites from Indian fishes. Supplement-I *Rec. zool. Surv. India. Occ. Paper No.*, **193** : 1-65.
- Nandi, N.C and Mandal, A.K. 1980. Collection and preservation of parasitic Protozoa. *Proc. Workshop Tech. Parasitol. Zool. Surv. India.*, Kolkata, pp.1-11.

- Narasimhamurti, C.C. 1970. *Myxosoma intestinalis* n. sp. (Protozoa, Myxosporidia) from the gut epithelium of the estuarine fish, *Mugil waigensis* (Quoy & Gaimard). *Proc. Indian Acad. Sci.*, **81** : 19-27.
- Narasimhamurti, C.C. and Kalavati, C. 1975. A new myxosporidian parasite, *Henneguya waltirensis* n. sp., from the gills of *Ophicephalus punctatus* Bl. *Riv. Parassitol.*, **36** (4) : 255-259.
- Narasimhamurti, C.C. and Kalavati, C. 1979a. *Myxosoma lairdi* n. sp., (Protozoa : Myxosporidia) parasitic in the gut of the estuarine fish, *Liza macrolepis* Smith. *Proc. Indian. Acad. Sci.*, **88B** (4) : 269-272.
- Narasimhamurti, C.C. and Kalavati, C. 1979b. *Kudoa tetraspora* n. sp. (Myxosporidea : Protozoa) parasitic in the brain tissue of *Mugil cephalus*. *Proc. Indian. Acad. Sci.*, **88B** (1) : 85-89.
- Narasimhamurti, C.C. and Kalavati, C. 1979c. *Kudoa sphyraeni* n. sp. (Myxosporidia : Protozoa) parasitic in the muscles of the gut of the marine fish, *Sphyraena jello* Cuv.. *Proc. Indian. Acad. Sci.*, **88B** (4) : 265-269.
- Narasimhamurti, C.C. and Kalavati, C. 1984. Seasonal variation of the myxosporidian *Henneguya waltirensis* parasitic in the gills of the freshwater fish, *Channa punctatus* Bl. *Arch. Protistenk.*, **128** (3) : 351-356.
- Narasimhamurti, C.C. and Kalavati, C. 1986. A new myxosporidian, *Myxobolus bivacuolatus* n. sp., parasitic in the intestinal wall of the freshwater fish, *Clarius batrachus*. *Arch. Protistenkd.*, **131** : 153-157.
- Narasimhamurti, C.C., Kalavati, C. Anuradha I. and Padma Dorothy, K. 1990. Studies on the protozoan parasites of deepwater fishes from the Bay of Bengal. *Proc. I. Workshop on Scientific Results of FORV Sagar Sampada 5-7th June, 1989* : pp. 325-336.
- Narasimhamurti, C.C., Kalavati, C. and Saratchandra, B. 1980. *Myxosoma microspora* n. sp. (Myxosporidia : Protozoa) parasitic in the gills of *Mugil cephalus* L. *J. Fish. Biol. U.K.*, **16** : 345-348.
- Nie, P. 1996. Co-occurrence of microhabitat of *Ancyrocephalus mogurndae* (Monogenea) and *Henneguya weishansis* (Myxosporea) on the gills of the mandarin fish, *Siniperca chautsi*. *Folia Parasitologica*, **43** : 272-276.
- Noble, E.R. 1957. Seasonal variations in host-parasite relations between fish and their protozoa. *J. Mar. Biol. Ass. (U.K.)*, **36** : 143-155.
- O'Grodnick, J.J. 1975. Whirling disease *Myxosoma cerebralis* : spore concentration using the continuous plankton centrifuge. *J. Wildl. Dis.*, **11** : 54-57.

- Okada M., Areche, T.N. and Ysikawa, Y.E. 1981. Myxosporidian infestation of the Peruvian hake. *Bull. Jap. Soc. Scientific fish.*, **47** (2) : 229-239.
- Padma Dorothy, K. 1990. Studies on myxosporidian parasites of *Liza macrolepis* (Smith) (Mugilidae). Ph. D. Thesis (unpublished), Andhra University, India.
- Padma Dorothy, K. and Kalavati, C. 1992a. Two new myxosporean parasites of the mullet, *Liza macrolepis* (Smith). *Uttar Pradesh J. Zool.*, **12** (1) : 15-19.
- Padma Dorothy, K. and Kalavati, C. 1992b. Description of four species of *Myxobolus* Butschli, 1882 from the mullet, *Liza macrolepis*, in the backwater regions of Visakhapatnam, east coast of India. *Proc. Zool. Soc. Calcutta*, **45** (2) : 197-204.
- Padma Dorothy, K. and Kalavati C., 1993a. *Parvicapsula hoffmanii* n. sp. (Myxozoa, Parvicapsulidae) from the mullet, *Liza macrolepis* (Smith). *Acta Protozool.*, **32** : 123-125.
- Padma Dorothy, K. and Kalavati, C. 1993b. A new myxosporean parasite, *Ortholinea visakhapatnamesis* n. sp., from the mullet, *Liza macrolepis* from Visakhapatnam harbour, India. *Riv. Parassitol.*, **10** (54) : 457-461.
- Padma Dorothy, K. and Kalavati, C. 1994. Gall bladder inflammation in the mullet, *Liza macrolepis* (Smith) following infection of a myxosporean *Davisia murtii* n. sp. *Indian J. Animal Sci.*, **42** (1) : 38-48
- Padma Dorothy, K. and Kalavati, C. 1998. *Palliatius indicus* n. sp. (Myxosporea : Protozoa) : parasitic to the mullet *Liza macrolepis* (Smith) causing neoplasia –A preliminary report. *Proc. zool. Soc., Calcutta*. **51** (1) : 60-64.
- Padma Dorothy, K., Kalavati, C. and Vaidehi, J. 1998. Three new species of myxozoans from teleosts of Bay of Bengal. *Riv. Parassitol.*, **15** (55) : 67-74.
- Pagarkar, A.U. and Das, M. 1993. Two new species of myxozoa, *Thelohanellus caudatus* n. sp., and *Myxobolus serrata* n. sp., from the cultural carps. *J. Inland Fish Soc. India*, **25** (1) : 30-35.
- Parker, J.D. and Warner, M.C. 1970. Effects of fixation, dehydration, and staining on dimensions of myxosporean and microsporidian spores. *J. Wildl. Dis.*, **6** : 448-456.
- Pearse, A.G.E. 1960. *Histochemistry*. J.A. Churchill, London 2nd edition
- Pellitero, Ma, P.A., Gonzalez-Lanza, Ma, C and Pereira Bueno, Ma. J. 1983. Coelozoic myxosporidians (*Myxidium* spp. and *Chloromyxum* sp.) of cyprinids from the river Esla (Leon, N.W. Spain) II. Population dynamics. *Angew. Parasitol.*, **24** : 65-71.

- Prashaer J.B., Tidd, W.M. and Tubb, R.A. 1971. Techniques for extracting and qualitatively spore stage of the protozoan parasite, *Myxosoma cerebralis*. *Prog. Fish Cult.*, **33** : 193-196.
- Qadri, S.S. 1962a. New Myxosporidia from Indian fresh water fish, *Labeo fimbriatus*, 1. *Gyrospora crucifila* gen. n., sp. n., *Z. Parasitenk.*, **21** : 513-516.
- Qadri, S.S. 1962b. On a new myxosporidian parasite, *Phlogospora mysti*, gen. n., sp. n., from Indian fresh water fish, *Mystus bleekeri*. *Arch. Protistenk.*, **106** : 211-217.
- Qadri, S.S. 1962c. New Myxosporidia from Indian fresh water fish, *Labeo fimbriatus* II *Thelohaenellus andhrae* sp. n., *Z. Parasitenk.*, **21** : 517-520.
- Qadri, S.S. 1962d. On a new myxosporidian, *Thelohaenellus boggoti* n. sp., from Indian fresh water fish *Labeo boggot*. *Arch. Protistenk.*, **106** : 218-222.
- Qadri, S.S. 1965. Study on a new myxosporidian parasite from the fresh water fish *Notopterus notopterus*. *Zool. Anz.*, **175** : 225-228.
- Qadri, S.S. 1967. On a new myxosporidian *Thelohaenellus shortti* n. sp., from the fresh water fish, *Labeo fimbriatus* of Andhra Pradesh, India. *J. Protozoology.*, **11** : 207-218.
- Qadri, S.S. 1970. On a new parasite, *Henneguya ganapatiae* n. sp from fresh water fish of Hyderabad, *Notopterus notopterus*. *Prof. Ganapati. Shas. Comm. Vol.*, pp. 1-5.
- Qadri, S.S. and Lalitha Kumari, P.S. 1965. A new Myxosporidian, *Myxobilatus mastacembeli* from a fresh water fish, *Mastacembelus armatus*. *Riv. Parassitol.*, **26** : 73-77.
- Rajagopalasamy, C.B.T. and Natarajan, P. 1987. Infestation of certain parasites of mullet, *Liza tade* (Forsskal). *J. mar. biol. Ass. India*, **29** (1&2) : 208-219.
- Rajendran, K.V. 2003. Anti protozoal and anti-metazoal preparations in aquaculture. In : *Aquaculture Medicine* (eds. Bright Singh, Somanath Pai, Rosamma Philip and Mohandas) Publ. Centre for fish disease Diagnosis and Management, School of Environmental Studies, Cochin University of Science and Technology, pp. 83-87.
- Rajendran, K.V. and Janardanan, K.P. 1989. Studies on *Myxobolus nodularis* Southwell and Prasad, 1918, infecting the fish, *Rasbora daniconius* and the metacercaria, *Diplostomulum minutum* with a note on its spore variations in different host tissues. *Riv. Parassitol.*, **6** : 115-120.

- Rajendran, K.V. and Janardanan, K.P. 1992. *Ceratomyxa etroplusi* sp. n. (Protozoa : Myxozoa) from the gall bladder of the brackish water fish, *Etroplus maculatus* (Bloch). *Acta Protozool.*, **31** : 177-180.
- Rajendran, K.V. and Janardanan, K.P. 2005. Two new species of *Chloronyxum* Mingazzini, 1890 (Myxosporia : Myxozoa) from the gall bladder of freshwater fishes in Kerala, India. *Riv. Parassitol.*, **22** (66) : 15-21.
- Rajendran, K.V., Vijayan, K.K. and Alvandi, S.V. 1998. Cardiac myxosporiasis of pearl spot, *Etroplus suratensis* (Bloch), due to *Myxobolus etropli* sp. nov. *J. fish Dis.*, **21** : 169-176.
- Ram, S.M.T., Chabra, M.B. Batra, U.K. and Mahipal, S.K. 1994. The association of myxosporidia as the cause of ulcerative disease syndrome in fish. *Ind. Vet. J.*, **71** (3) : 293-294.
- Ray, H.N. 1933a. Preliminary observations on Myxosporidia from India. *Curr. Sci.*, **1** : 349-350.
- Ray, H.N. 1933b. Myxosporidia from India. *Proc. Indian. Sci. Congr.*, p. 259.
- Ray Chaudhuri, S. and Chakravarty, M.M. 1970. Studies on Myxosporidia (Protozoa : Sporozoa) from the food fishes of Bengal. I. Three new species from *Ophicephalus punctatus* Bloch. *Acta Protozool.*, **8** : 167-173.
- Ruidisch, S., El-Matbouli, M. and Hoffman, R.W. 1991. The role of tubificid worms as an intermediate host in the life cycle of *Myxobolus pavlovskii* (Akhemerov' 1954). *Parasitol. Res.*, **77** : 663-667.
- Rhee, J.K., Kim, H.C. and Park, B.K. 1993. Efficacy of Fumagillin against *Thelohanellus kitauei* infection of Israel carp, *Cyprinus carpio nudus*. *The Korean J. Parasit.*, **31** (1) : 57-65.
- Rothwell, J.T., Virgona, J.L., Callinan, R.B., Nicholas, P.J. and Langdon, J.S. 1997. Occurrence of cutaneous infections of *Myxobolus episquammalis* (Myxozoa : Myxobolidae) in sea mullet, *Mugil cephalus* L, in Australia. *Aust. Vet. J.*, **75** (5) : 349-356.
- Sanders, J.E., Fryer, J.L., Leith, D.A., and Moore, K.D. 1970. Occurrence of the myxosporidian parasite *Ceratomyxa shasta*, in salmonid fish from the Columbia River basin and Oregon coastal streams. In : "Symposium on Diseases of Fishes and Shellfishes" (S F. Snieszko, ed.) *Spec. Publ 5*, pp. 133-144. Am. Fish. Soc., Washington, DC.
- Sanders, J.E., Fryer, J.L., Leith, D.A., and Moore, K.D. 1972. Control of the infectious protozoan *Ceratomyxa shasta* by treating hatchery water supplies. *Prog. Fish cult.*, **34** : 13-17.

- Sandeep, B.V., Kalavati C. and. Narasimhamurti C.C., 1986. *Kudoa atropi* sp. n. (Myxosporea, Multivalvulida) a new myxosporidian from the gills of *Atropus atropus*. *Vest. cs. Spolec. Zool.*, **50** : 132-135.
- Sarkar, H.L. 1946. On protozoan parasite *Myxobolus mrigalae* Chakravarty, infecting the fry, *Cirrhina mrigala* (Ham.). *Curr. Sci.*, **15** : 111-112.
- Sarkar, N.K. 1982b. On three new myxosporidian parasites (Myxozoa) of the Ophicephalid fishes of West Bengal, India. *Acta Protozool.*, **21** (3-4) : 239-244.
- Sarkar, N.K. 1984a. A new myxosporidan, *Sphaeromyxa hareni* sp. n. (Myxozoa : Myxidiidae) from Indian marine teleost *Tachysurus platystomus* (Day). *Acta Protozool.*, **23** : 183-186.
- Sarkar, N.K. 1984b. A species of *Unicapsula*, Davis, 1914 (Myxozoa) infecting a fish of the southern coast of India. *Intl. J. Acad. Ichthyol.*, (Proc. IV AISI), **5** : 187-189.
- Sarkar, N.K. 1985a. Some Coelozoic Myxosporida (Myxozoa : Myxosporea) from a fresh water teleost fish of River Padma. *Acta Protozool.*, **24** (1) : 47-53.
- Sarkar, N.K. 1985b. Myxosporidan *Henneguya mystusii* sp. n. (Myxozoa : Myxosporea) from the gill of a fresh water teleost fish *Mystus* sp. *Acta Protozool.*, **24** (1) : 56-58.
- Sarkar, N.K. 1985c. Some Myxosporida (Myxozoa : Myxospora) of Anabantid fishes of West Bengal, India. *Acta Protozool.*, **24** (2) : 175-180.
- Sarkar, N.K. 1986a. On two new species of *Myxobolus* Butschli, 1882 (Myxozoa : Myxosporea) from the freshwater fishes of West Bengal, India. *Acta Protozool.*, **25** (2) : 235-239.
- Sarkar, N.K. 1986b. *Ceratomyxa tartoori* sp. n. (Myxozoa) from the gall bladder of a marine teleost (Clupeidae) of West Bengal, India. *Acta Protozool.*, **25** (3) : 351-354.
- Sarkar, N.K. 1986c. A new myxosporidan *Myxidium sciaenae* sp. n. (Myxozoa : Myxididae) from the gall bladder of a marine teleost of West Bengal, India. *Acta Protozool.*, **25** (4) : 477-479.
- Sarkar, N.K. 1987. Studies on myxosporidian parasites (Myxozoa : Myxosporea) from marine fishes in West Bengal, India. II. Description of two new species from *Tachysurus platystomus* (Day). *Arch. Protistenkd.*, **133** : 151-155.
- Sarkar, N.K. 1989. *Myxobolus anili* sp. nov. (Myxozoa : Myxosporea) from marine teleost fish, *Rhinomugil corsula* Hamilton. *Proc. Zool. Soc. Calcutta*, **42** : 71-74.

- Sarkar, N.K. 1993. On two new species of *Myxobolus* Butschli 1882 (Myxozoa : Myxosporea) from some freshwater fish of West Bengal, India. *Proc. Zool. Soc., Calcutta*, **46** (1) : 61-66.
- Sarkar, N.K. 1994. Three new species of Myxosporidia (Myxozoa : Bivalvulida) infecting some fresh water fishes of West Bengal, India. *Proc. Zool. Soc., Calcutta*, **47** (1) : 63-69.
- Sarkar, N.K. 1995a. A new myxozoan, *Coccomyxa baleswarensis* n. sp. (Myxosporea : Myxidiidae), parasite in the gall bladder of an anadromous clupeid, *Hilsa ilisha* (Ham.). *Arch. Protistenkd.*, **145** : 135-138.
- Sarkar, N.K. 1995b. Observations on two new myxosporidia (Myxozoa : Myxosporea) from fishes of Bhery-fishery of West Bengal, India. *Acta Protozool.*, **34** (1) : 67-70.
- Sarkar, N.K. 1996a. *Zschokkella pseudosciaena* sp. n. and *Myxoproteus cujaeus* sp. n. (Myxozoa : Myxosporea) from sciaenid fish of Hooghly Estuary, West Bengal, India. *Acta Protozool.*, **35** : 331-334.
- Sarkar, N.K. 1996b. On two new myxosporidian parasites (Myxozoa : Myxosporea) of a freshwater teleost, *Notopterus notopterus* (Pallas) of West Bengal, India. *Proc. Zool. Soc., Calcutta*, **49** (1) : 5-10.
- Sarkar, N.K. 1997. *Sinuolinea indica* sp. n. (Myxosporea : Sinuolineidae) parasitic in the urinary bladder of a sciaenid fish from the Hooghly Estuary, West Bengal, India. *Acta Protozool.*, **36** : 305-309.
- Sarkar, N.K. 1999a. *Ortholinea gadusiae* sp. n., and *Sphaeromyxa opisthopterae* sp. n., (Myxozoa : Myxosporea) from clupeid fish of Bay of Bengal, India. *Acta Protozool.*, **38** : 145-153.
- Sarkar, N.K. 1999b. Some new myxosporidia (Myxozoa:Myxosporea) of the genera *Myxobolus* Butschli, 1882, *Unicapsula* Davis, 1942, *Kudoa* Meglitsch, 1947, *Ortholinea* Shulman, 1962 and *Neoparvicapsula* Gaevskaya, Kovaleva and Schuman, 1982. *Proc. zool. Soc. Calcutta*, **52** (1) : 38-48.
- Sarkar, N.K. 2004. On some new coelozoic myxosporidia (Myxozoa; Myxosporea) from some teleost fishes of West Bengal, India. *J. Environ. & Sociobiol.*, **1** (1&2) : 35-47.
- Sarkar, N.K. and Ghosh, S. 1990. Two new myxozoan parasite of the genus *Thelohanellus* Kudo, 1933 (Myxosporea : Myxobolidae) from fresh water fishes of West Bengal, India. *New Agriculturist*, **1** (1) : 35-38.

- Sarkar, N.K. and Ghosh, S. 1991a. Two new coelozoic myxosporida (Myxozoa : Myxosporea) from estuarine teleost fishes (Mugilidae) of West Bengal, India. *Proc. Zool. Soc. Calcutta*, **44** (2) : 131-135.
- Sarkar, N.K. and Ghosh, S. 1991b. Two new myxosporida (Myxozoa : Myxidiidae) from fresh water fishes of West Bengal, India. *Uttar Pradesh J. Zool.*, **11** (1) : 54-58.
- Sarkar, N.K. and Majumdar, S. 1983a. Studies on myxosporidian parasites (Myxozoa; Myxosomatidae) from marine fishes in West Bengal, India. 1. Description of three new species from *Tachysurus* sp. *Arch. Protistenkd.*, **127** (1) : 59-63.
- Sarkar, N.K. and Mazumdar, S. 1983b. Myxosporidian, *Sphaeromyxa dighae* sp. n. (Myxozoa : Myxidiidae) from the gall bladder of *Hilsa ilisha* (Clupeidae). *Acta Protozool.*, **22** (3-4) : 257-280.
- Sarkar, N.K., Halder, B. and Chakraborti, R. 1982. *Myxosoma gangulli* sp. n. (Myxozoa : Myxosomatidae) from the head cartilage of *Sillago maculata* Quoy and Gaimard (Sillaginidae). *Acta Protozool.*, **21** (3-4) : 245-249.
- Sarkar, N.K., Mazumdar, S.K. and Pramanik, A. 1985. Observations on four new species of Myxosporidia (Myxozoa) from channid (Ophicephalid) fishes of West Bengal, India. *Arch. Protistenk.*, **130** : 289-296.
- Sarkar, N.K. and Misra K.K. 1996. Neothelohanellidae fam. n., and taxonomic consideration on the genera *Neothelohanellus* and *Lomosporus* (Myxozoa : Myxosporea). *Acta Protozool.*, **35** : 157-160.
- Sarkar, N.K. and Pramanik, A.K. 1994a. *Ceratomyxa daysciaenae* sp. n. (Myxozoa : Ceratomyxidae) a myxosporean parasite in the gall bladder of a teleost from the Hooghly estuary, West Bengal, India. *Acta Protozool.*, **33** : 121-124.
- Sarkar, N.K. and Pramanik, A.K. 1994b. *Ceratomyxa tenulosae* sp. nov., (Myxozoa : Myxosporea : Ceratomyxidae) parasite of gall bladder of an estuarine teleost *Tenulosa toli* (Valenciennes). *Uttar Pradesh J. Zool.*, **14** (2) : 113-116.
- Sarkar, N.K. and Ray choudhury, S. 1986. *Thelohanellus bengalensis* sp. n. and *Myxidium mystusium* sp. n. (Myxozoa) : Two new Myxosporida from Indian freshwater teleosts. *Acta Protozool.*, **25** (3) : 359-362.
- Sarkar, N.K. and Ray chaudhury, S. 1996. *Kudoa cascasia* sp. n. (Myxosporea : Kudoidae) parasitic in the mesentery of *Sicamugil cascasia* (Ham.) from Hooghly Estuary of West Bengal, India. *Acta Protozool.*, **35** : 335-338.

- Sarkar, N.K. and Raychoudhury, S. 1997. *Myxidium leptocephalichthysum* sp. n. (Myxosporidia : Myxidiidae) infecting an estuarine fish of West Bengal, India. *Uttar Pradesh J. Zool.*, **17** (3) : 233-236.
- Schafer, W.E. 1968. Studies on epizootiology of the myxosporidian *Ceratomyxa shasta* Noble. *Calif. Fish game*, **54** : 90-99.
- Schulman, S.S. (ed.) 1966. *Myxosporidea of USSR*. Nauka Publishers, Moscow-Leningrad. 631 pp.
- Schulman, S.S. 1953. New and little known myxosporidia from the White sea. *Zool. Zh.*, **32** : 384-394.
- Schulman, S.S. 1959. New classification of myxosporidia. Tr. *Karelsk. fil. An. SSSR. Vopr. Parazitol. Karelii*. pp. 33-47.
- Schulman, S.S. 1962. Myxosporidia (Myxosporida) In : *Opredelitel' Presnovodnykh Ryb SSSR* Izd. An SSSR Moscow-Leningrad, pp. 47-130.
- Schulman, S.S., Kovaleva, A.A. and Dubina, V.R. 1979. New myxosporideans from fishes of the Atlantic coast of Africa (in Russian) *Parazitologiya*, **13** : 71-79.
- Scolari, C.* 1954. Sull'impiego dello stovarsole nella profilassi del « Capostorno » o "Lentosporiasi" delle trote d' allevamento. *Clin Veterin.*, **77** : 50-53.
- Seenappa, D. and Manohar, L. 1980a. Two new species of *Myxobolus* (Myxosporidia : Protozoa) parasitic on *Cirrhina mrigala* (Ham.) and *Puntius curmuca* (Hamilton). *Curr. Sci.* **49** (5) : 204-206.
- Seenappa, D. and Manohar, L. 1980b. *Myxobolus vanivilasae* n. sp. parasitic in *Cirrhina mrigala* (Ham.). *Proc. Indian Acad. Sci. (Anim. Sci.)*, **89B** : 485-491.
- Seenappa, D. and Manohar, L. 1980c. Intensity of *Myxobolus vanivilasae* (Myxosporidia) parasitic in *Cirrhina mrigala* (Ham.) with a note on spore load. *Mysore J. Agri. Sci.*, **14** : 385-387.
- Seenappa, D. and Manohar, L. 1981a. Five new species of *Myxobolus* (Myxosporidia : Protozoa), parasitic in *Cirrhina mrigala* (Ham.) and *Labeo rohita* (Ham.), with a note on a new host record. *J. Protozool.*, **28** (3) : 358-360.
- Seenappa, D., Manohar, L. and Prabhu, R.N. 1981b. *Henneguya thermalis* n. sp., parasitic in the brain tissue of the loach, *Lepidocephalichthys thermalis* (Hamilton). *Curr. Sci.*, **50** (6) : 295-296.
- Seenappa, D. and Manohar, L. 1983. In Vitro effects of chemicals and disinfectants on the spores of *Myxobolus vanivilasae*, Seenappa and Manohar, 1980 (Myxosporidia : Protozoa). *Mysore. J. Agric. Sci.*, **17** : 170-176.

- Setna, S.B. 1942. Preliminary observations on Myxosporidia from sharks. *Curr. sci.*, **11** : 165-169.
- Siau, Y. 1980. Observations immunologiques sur des poissons du genre *Mugil* parasites par la myxosporidie *Myxobolus exiguus* Thelohan, 1895. *Z.Parasitenk.*, **62** : 1-6.
- Siddal, M.E., Martin, D.S., Bridge, D., Desser, S.S. Cone, D.K. 1995. The demise of a phylum of protists : Phylogeny of the Myxozoa and other parasitic cnidaria. *J. Parasitol.*, **81** : 96-97.
- Sindermann, C.J. 1970. *Principal Diseases of Marine fish and Shellfish*. Academic press, New York.
- Srivastava, S.P. 1979. A new species of *Myxobolus* from scales of *Cirrhina mrigala* (Hamilton). *Science and Culture*, **45** : 444-445.
- *Southwell, T. 1915. A skin disease found in *Rasbosa daniconius*. On some Indian parasites of fish with note on the carcinoma in trout. I. A skin disease found in *Rasbora daniconius*. *Rec. Indian Mus.*, **II** : 312-313.
- *Southwell, T. and Prashad, B. 1918. On some Indian Myxopordia. Parasites of Indian fishes with a note on carcinoma in the climbing perch. II. On some Indian myxosporidia. *Rec. Indian Mus.*, **15** : 344-348.
- Susha, T.K. and Janardaran, K.P. 1994. *Myxobilatus fossilis* n.sp. (Myxosporia : Myxozoa) parasitic in the urinary bladder of *Heteropneustes fossilis* (Bloch). *Bioved*, **5** (2) : 119-124.
- Susha, T.K. and Janardhan, K.P. 1995. On a new myxosporean parasite, *Phlogospora oculatus* n. sp., from *Mystus oculatus* (Hamilton) in Kerala. *Proc. Zool. Soc., Calcutta*, **48** (1) : 11-14.
- Taylor, R.E.L., Coli, S.J. and Junell, D.R. 1973. Attempts to control whirling disease by continuous drug feeding. *J. Wildl. Dis.*, **9** : 302-305.
- *Thelohan, P. 1892. Observation sur les myxosporidies et essai de classification de ces organismes. *Bull. Soc. Philon.*, **4** : 165-178.
- *Thelohan, P. 1895. Recherches sur les myxosporidies. *Bull. Sci. Fr. Belg.*, **26** : 110-394.
- Tripathi, Y.R. 1948. Some new Myxosporidia from Plymouth with a proposed new classification of the order. *J. Parasitol.*, **39** : 110-118.
- Tripathi, Y.R. 1952. Studies on parasites of Indian fishes I. Protozoa : Myxosporidia together with a check list of parasitic protozoa described from Indian fishes. *Rec. Indian Mus.*, **50** : 63-88.

- Udey, L.R., Freyer, J.L. and Pilcher, K.S. 1975. Relation of water temperature to ceratomyxosis in rainbow trout (*Salmo gairdneri*) and Coho salmon (*Onchorhynchus kisutch*). *J. Fish. Res. Board. Can.*, **32** : 1545-1551.
- Uspenskaya, A.V. 1978. Biological features of the spore stage of *Myxosoma cerebralis* (Myxosporidea : Myxosomatidae). *Parazitologiya*, **12** : 1331-1333.
- Vaidehi, J. 1992. Myxosporidian parasites of fishes of Chilka Lake. Ph. D. Thesis (unpublished), Andhra University, India.
- Wierzbicka, J. 1986. *Paramyxoproteus reinhardti* gen. n., et. sp. n., (Bivalvulida, Myxosporea) a parasite of *Reinhardtius hippoglossoides* (Walbaum, 1972). *Acta Protozool.*, **25** : 227-234.
- Wolf, K. and Markiw, M.E. 1979. *Myxosoma cerebralis* : a method for staining spores and other stages with silver nitrate. *J. Fish. Res. Board. Can.*, **36** : 88-89.
- Wolf, K. and Markiw, M.E. 1984. Biology contravenes taxonomy in Myxozoa : New discoveries show alternation of invertebrates and vertebrate hosts. *Science*, **225** : 1449-1452.
- Wyatt, E.J. 1978. Studies in the epizootiology of *Myxobolus insidiosus* Wyatt and Pratt, 1963 (Protozoa : Myxosporida). *J. Fish Dis.*, **1** : 230-240.
- Yatindra and Mathur B.N. 1988. Studies on new species of *Myxidium* (Protozoa : Myxozoa : Myxosporea) from a fresh water teleost fish *Cirrhina reba*. *Uttar Pradesh J. Zool.*, **8** (1) : 43-48.
- Yokoyama, H., Ogawa, K. and Wakabayashi, H. 1991. A new collection method of actinosporeans-probable infective stage or myxosporeans to fishes from tubificids and experimental infection of goldfish with actinosporean. *Raabeia* sp. *Gyobyō Kenkyū*, **26** : 13-138.
- Yunchis, O.N. 1974. Some details of the biology of Myxosporidia. *4th All-Union Conf. Dis, Parasites Fishes*, Moscow (In Russian).

LEGENDS TO THE PLATES 1-5

Plate 1 : 1 - Intralamellar cysts - *Myxobolus* sp.,

Labeo; 2 - Interlamellar cysts - *Myxobolus* in *Catla catla*;

3 to 9 - Inflammatory and degenerative changes in gill epithelium

**Plate 2 : 1 to 9 - Myxosporiosis in the gut and viscera of the mullet,
*Mugil cephalus***

**Plate 3 : Gall bladder inflammation, hypertrophy, sinusoidal dilatation
mononuclear leucocyte aggregation in *Liza macrolepis* infected with
*Davisia murtii***

**Plate 4 : Myxosporiosis in different organs : 1 - Testis; 2 - Ovary;
3 to 5 - Muscles; 6 - Heart (from Krishna Kumar 2000); 7 & 8 - Cartilage**

**Plate 5 : 1 - Renal myxosporiosis in carp
2 to 8 - Pancreatitis in *Liza macrolepis* infected with *Palliatius indicus***

PLATE - 1

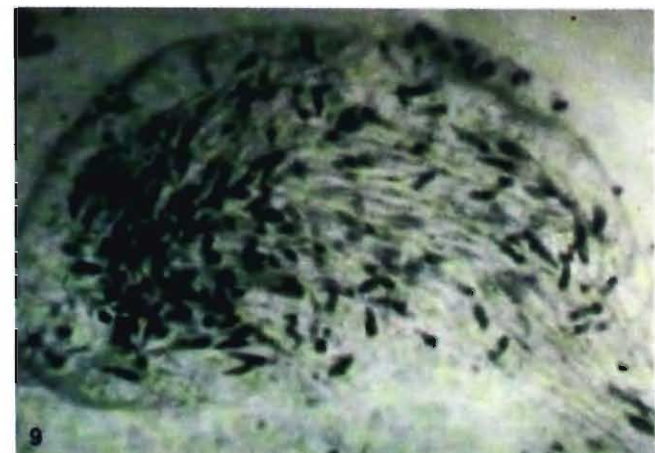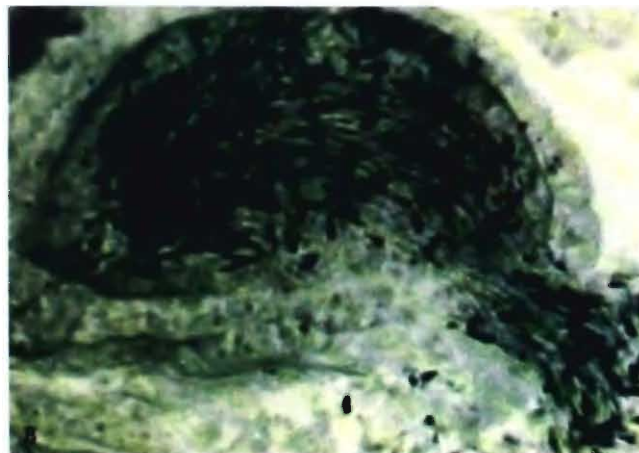
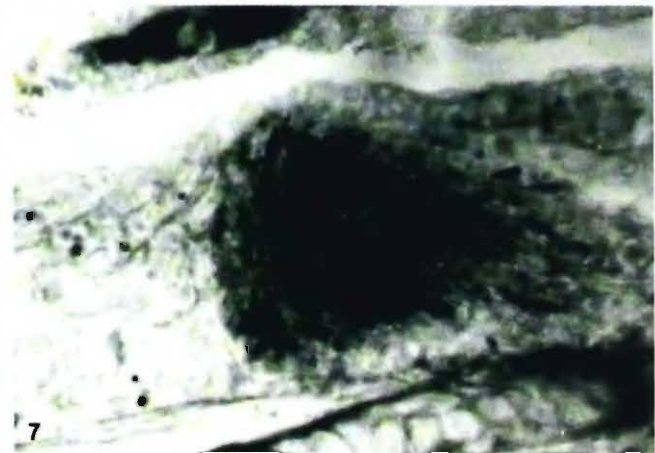
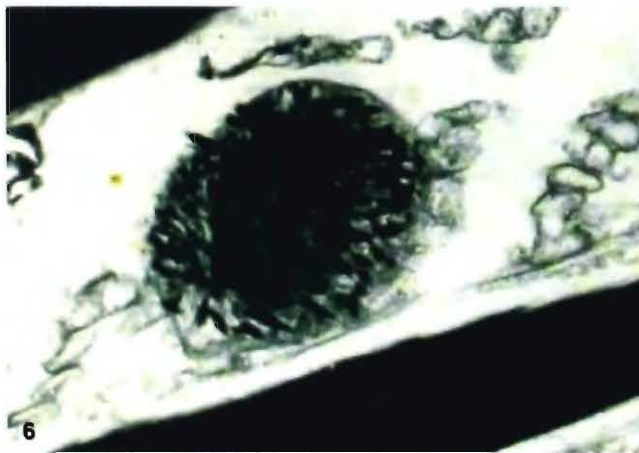
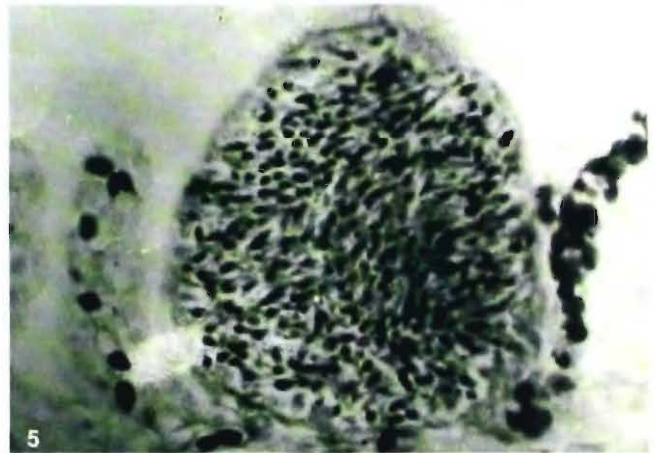
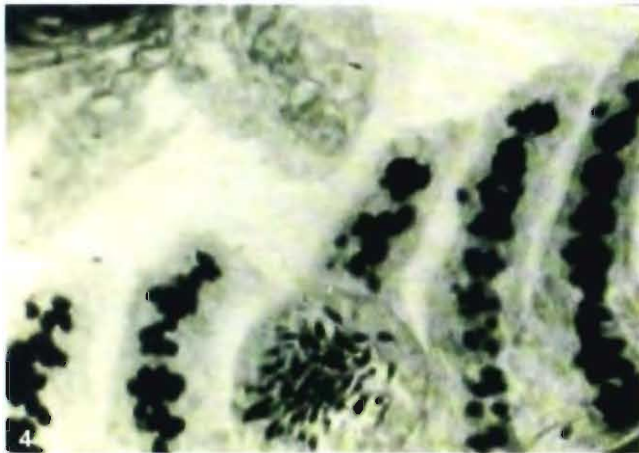
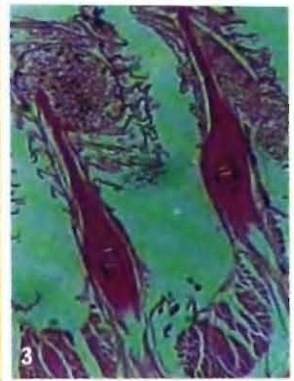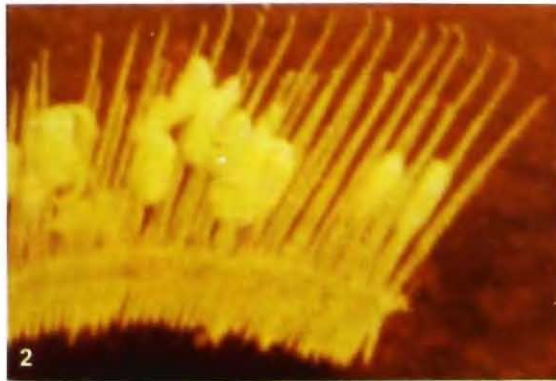


PLATE - 2

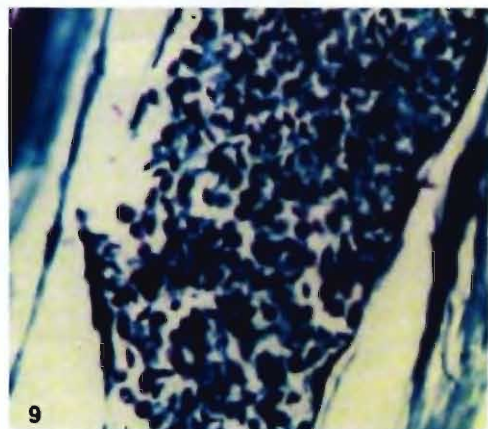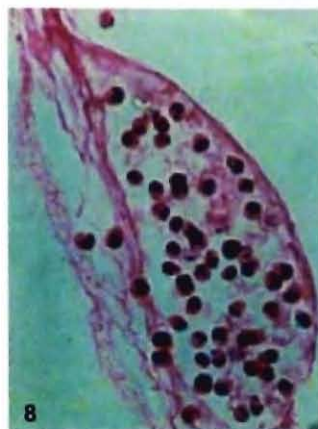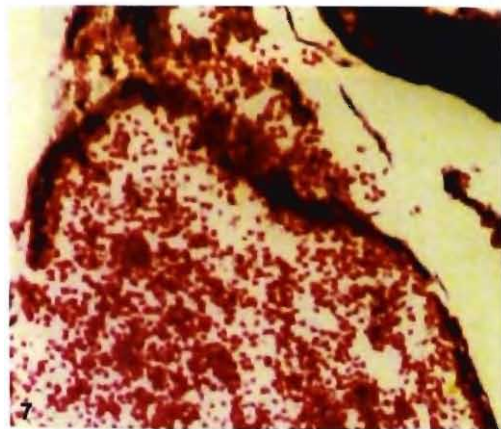
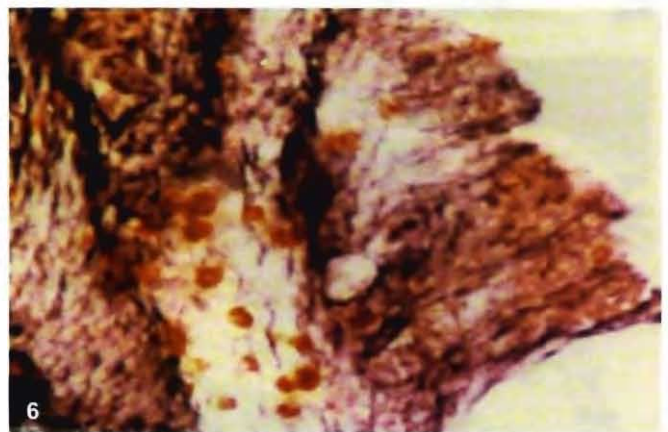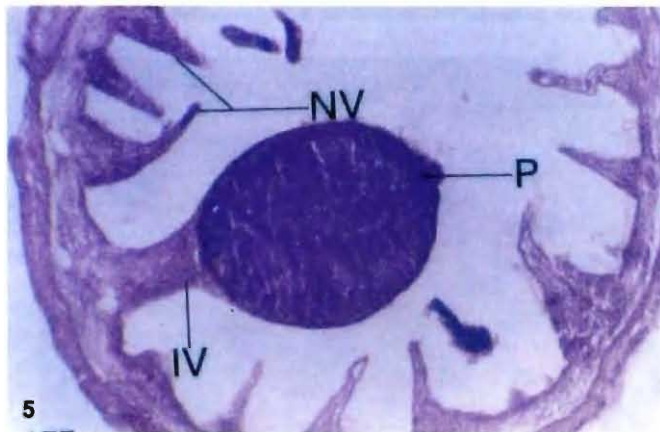
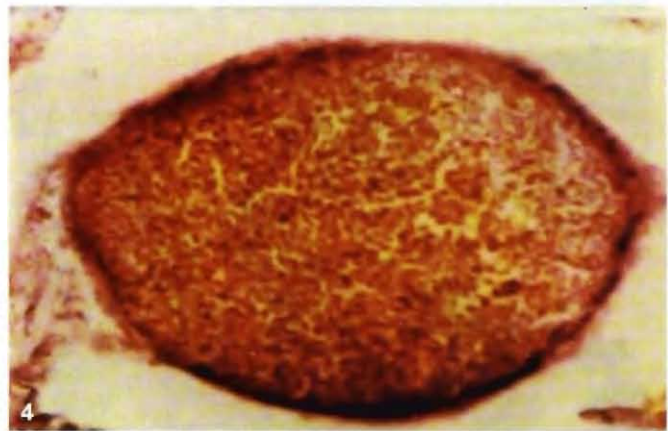
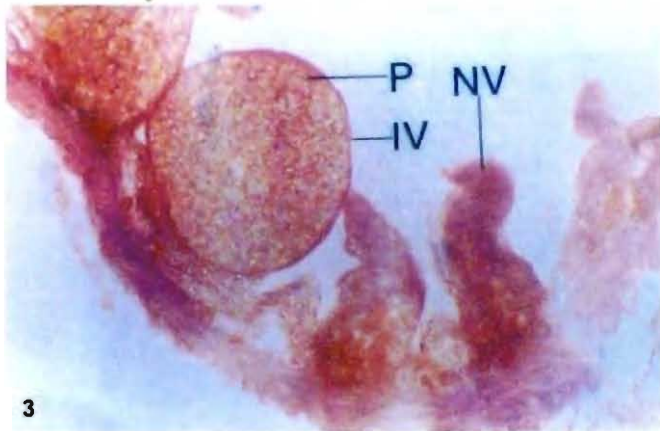
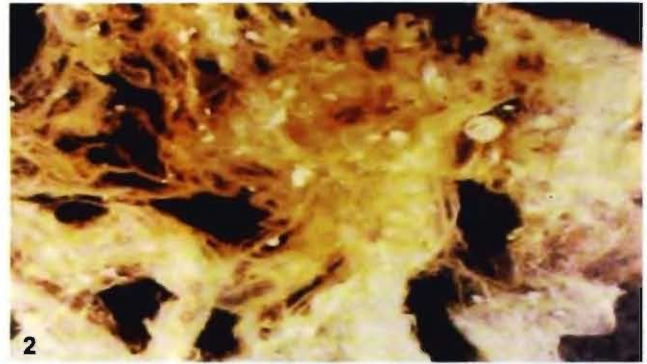
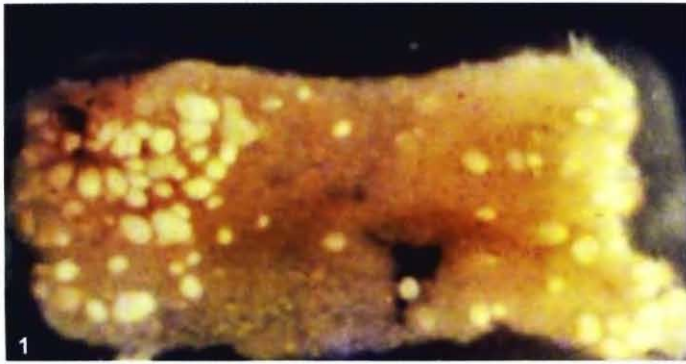


PLATE - 3

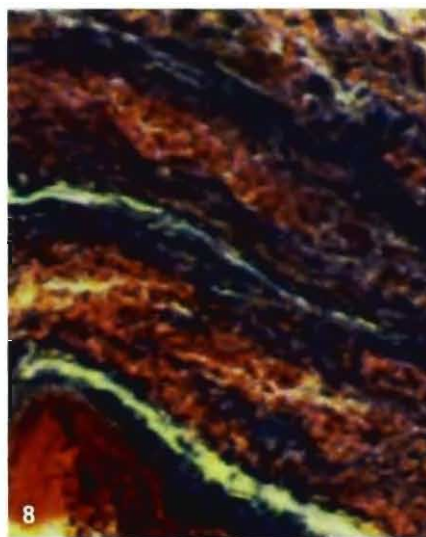
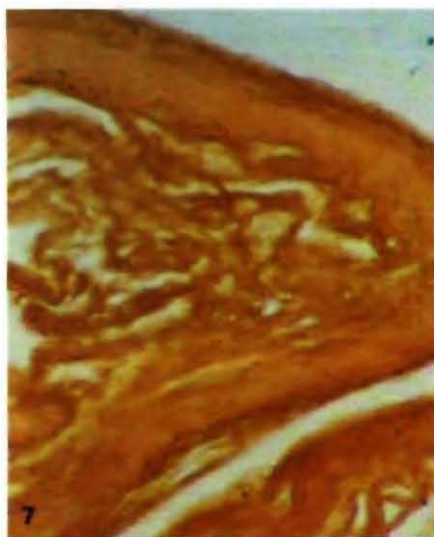
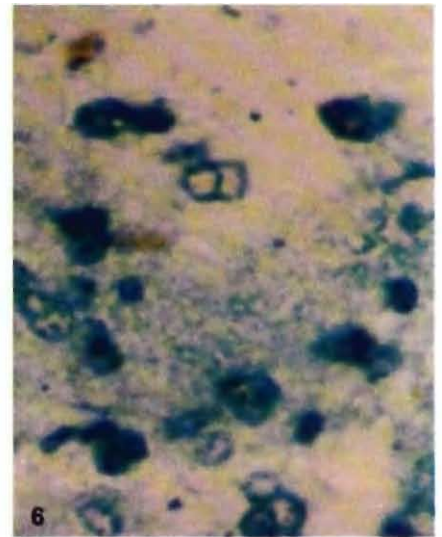
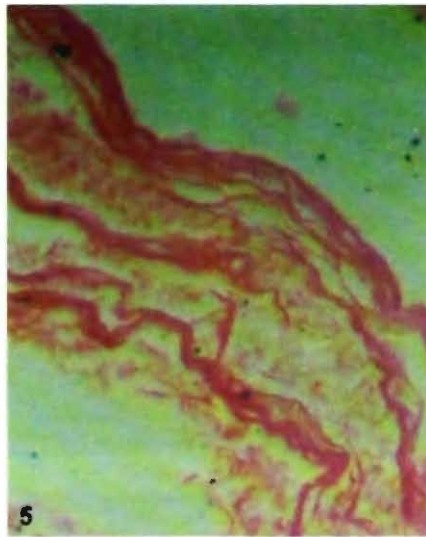
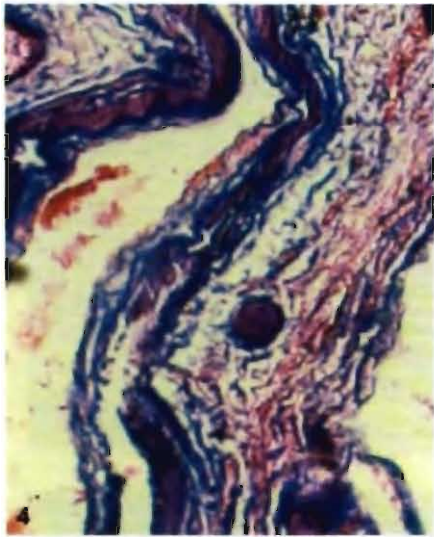
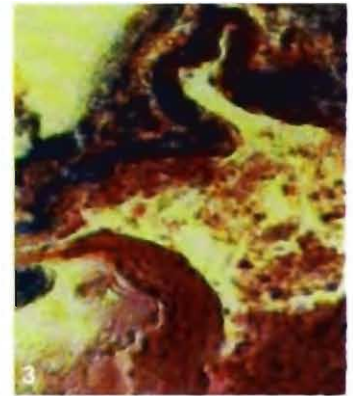
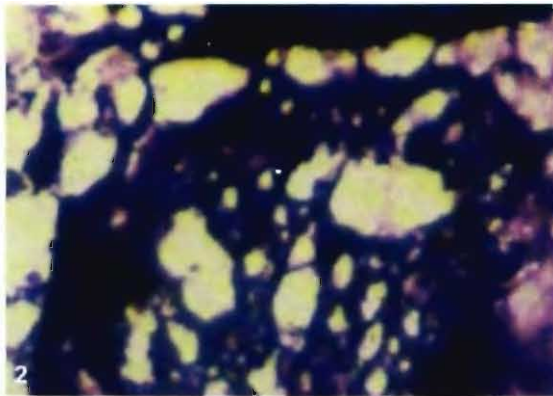
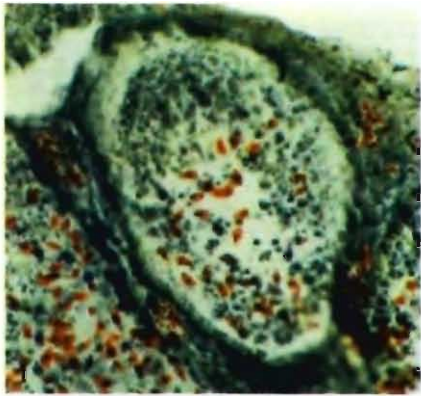


PLATE - 4

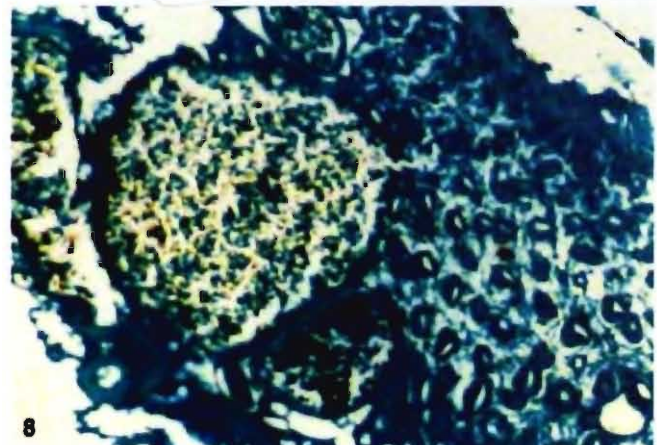
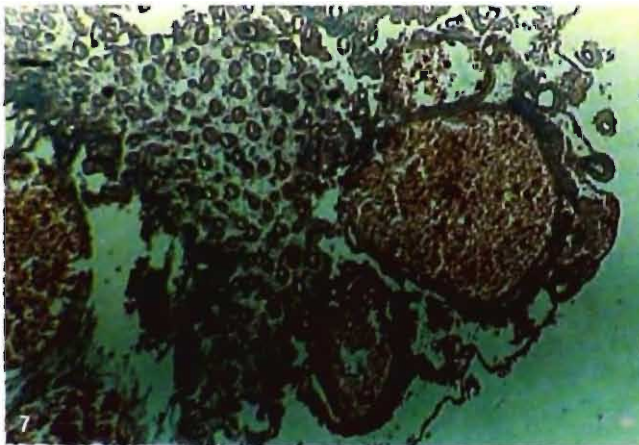
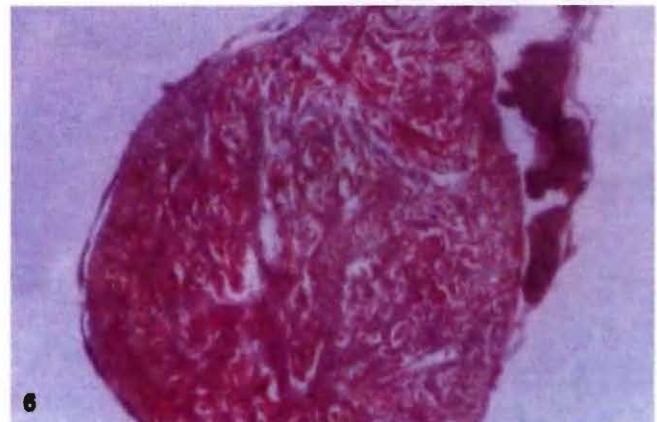
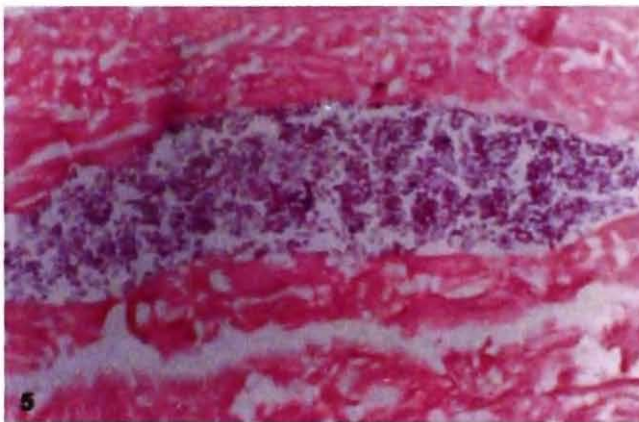
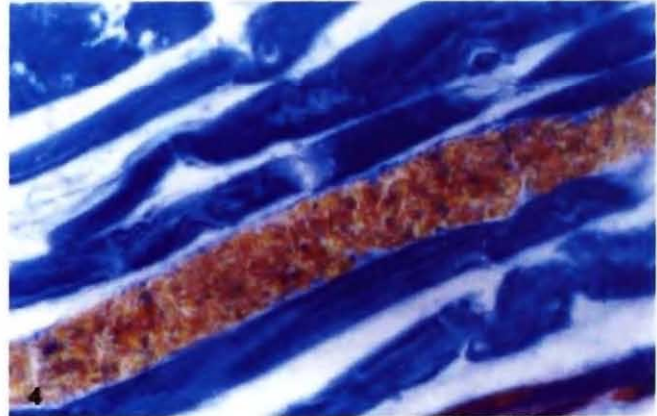
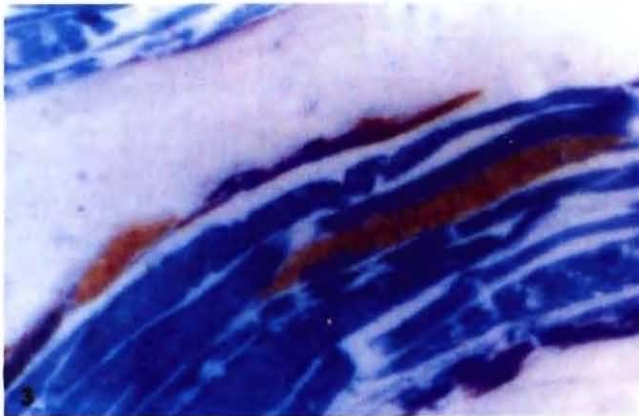
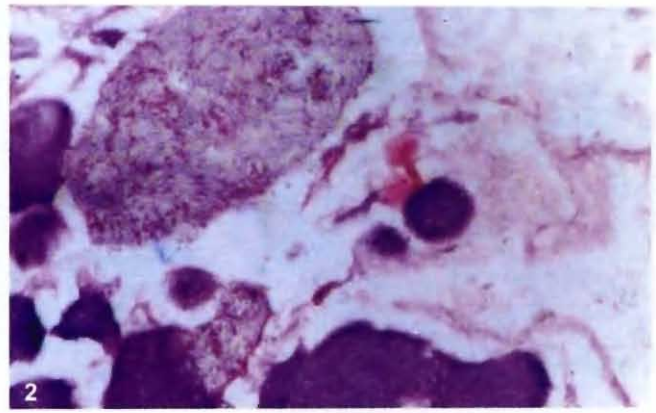
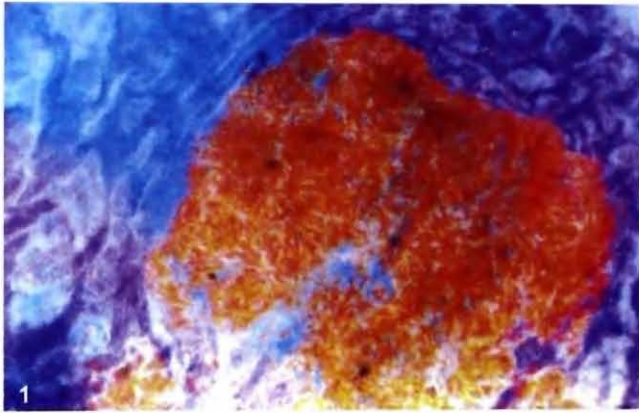


PLATE - 5

